

Radioprotective effect of *Nigella sativa* Oil (NSO) against radiation-induced hepatic toxicity and haematological alteration in irradiated albino mice

S.S. Mohammed Amin¹, L. MA. Mohammed², A.B. Faiq^{2*}, S.S. Salih², Z.Y. Saeed³, T.F. Muhammed Salih⁴, D. Abdullah Rashid⁵

¹Anaesthesia Department, College of Health & Medical Technology, Sulaimani Polytechnic University, Sulaimaniyeh, Iraq

²Medical Laboratory Department, College of Health & Medical Technology, Sulaimani Polytechnic University, Sulaimaniyeh, Iraq

³Zhianawa Cancer Center, Sulaimaniyeh, Iraq

⁴Nursing Department, College of Health & Medical Technology, Sulaimani Polytechnic University, Sulaimaniyeh, Iraq

⁵Biology Department, College of Basic Education, University of Sulaimani, Sulaimaniyeh, Iraq

ABSTRACT

► Original article

*Corresponding author:

Ary Bahman Faiq, M.Sc.,

E-mail: ary.faiq@spu.edu.iq

Received: May 2022

Final revised: September 2022

Accepted: October 2022

Int. J. Radiat. Res., January 2023;
21(1): 89-95

DOI: 10.52547/ijrr.21.1.12

Keywords: X- radiation, *nigella sativa* oil (NSO), haematological parameters, lipid peroxidation, histological modification, liver function.

Background: In this study, an attempt was made to estimate to what degree *Nigella sativa* oil (NSO) could reduce the destruction produced by irradiation on the haematopoietic system, liver function and histopathological changes of liver tissues, and malondialdehyde MDA level in albino mice exposed to whole-body x-radiation. **Materials and Methods:** the mice were divided into four different groups. Group I (negative control group) received deionized water. Group II (6 Gy group) was exposed to whole-body X-irradiation at 6 Gy. Group III (NSO) received NSO orally (10 ml/kg). Group IV (NSO+6 Gy) received NSO orally (10 ml/kg) for 5 days prior to irradiation. **Results:** The results of the group exposed to 6 Gy X-irradiation showed a decrease in red blood cell count, *haemoglobin*, hematocrit, mean corpuscular volume and mean corpuscular haemoglobin (all with $P \leq 0.05$), while for the group that received NSO before irradiation, all the mentioned parameters were ameliorated and shifted toward normal values. Alanine aminotransferase (ALT) and aspartate aminotransferase (AST) enzyme levels were showed to be affected: they both increased during irradiation in the (6 Gy) group and decreased in the (NSO + 6 Gy) group. Histopathological alterations were also observed when the liver was irradiated in the (6 Gy) group. However, the (NSO+6 Gy) group demonstrated a lowering of the incidence of histopathological changes in liver tissues. **Conclusion:** it is clear that mice treated with NSO oil prior to X-irradiation had reduced alteration in the haematological parameters, hepatocyte lipid peroxidation and the histology of the liver.

INTRODUCTION

Ionizing radiation is widely used for various purposes, including cancer radiotherapy, diagnosis and non-clinical applications. Despite their notable applications, ionizing radiations can damage tissues and organs through direct and indirect actions. In direct action, radiation energy is absorbed by cell structures, particularly DNA, leading to molecular damage. In indirect action, most of the energy is absorbed by water molecules; as a result, free radicals, which have unpaired electrons and are highly chemically reactive, are produced^(1,2). The free radicals may diffuse a distance of about twice the DNA radius and interact with DNA molecules, causing cell death, DNA damage, chromosomal aberrations and carcinogenesis⁽³⁾. In the human body, when

impairment occurs in the oxidant/antioxidant equilibrium system, it is mainly attributed either to an increase in the reactive oxygen species (ROS) or to defects in antioxidant enzymes. Both cause cell damage and, eventually, many diseases^(4,5). The liver is a susceptible organ affected by gradually increasing oxidative stress or by the decreasing level of glutathione, in many different cases. Therefore, there are many hepatic diseases associated with free radical proliferation, such as viral hepatitis, fatty liver, and hepatic ischemia, as well as alcohol consumption⁽⁶⁾. There are many parameters designed to assess the scale of hepatic destruction which are measured through oxidized cellular species, such as those of DNA, proteins or lipid membranes, by malondialdehyde and the enzymes alanine aminotransferase (ALT) and aspartate

aminotransferase (AST) ⁽⁷⁾. Bone marrow is another tissue considered to be affected by radiation. As is known, haematopoietic cells are responsible for producing blood cells in the bone marrow. Haematopoietic cells are highly radiosensitive, and exposing them to even low doses of radiation can lead to reduction in blood cell counts and bone marrow failure ⁽⁸⁾. Antioxidants in natural products such as plant extracts have the ability to increase the threshold capacity against the oxidative stress caused by free radicals, and to reduce hepatic degeneration ⁽⁹⁾. *Nigella sativa* (black cumin) is a good natural source of antioxidants, and has significant radical scavenging properties due to its components. It contains thymoquinone, carvacrol, t-anethol and 4-terpineol ^(10, 11). Studies have indicated that thymoquinone is the main component of the essential oil of *N. sativa* and has proved to act as an antioxidant, anti-carcinogenic and anti-mutagenic agent ^(12, 13). According to some studies, there were reductions in malondialdehyde, ALT and AST levels in animals treated with *N. sativa* ^(14, 15). An investigation performed on rats by Abdel-Hamid *et al.* concluded that high serum alpha-fetoprotein in CCl₄ induced hepatic carcinoma that was reduced after administration of a methanolic extract of *N. sativa*. The study also concluded that elevation of some enzymes in the glycolysis pathway, such as hexokinase, glyceraldehyde phosphate dehydrogenase and glucose 6 phosphate dehydrogenase, during tumor proliferation was reduced after treatment with *N. sativa* extracts ⁽¹⁶⁾. Furthermore, another study showed that both aqueous and methanolic extracts of *N. sativa* demonstrated anti-proliferative activity against human breast cancer BCF-7 ⁽¹⁷⁾.

In this study, an attempt was made to evaluate the effect of NSO on red blood cell count (RBC), haemoglobin (Hb), haematocrit test (HCT), mean corpuscular volume (MCV), mean corpuscular haemoglobin (MCH) and red cell distribution width (RDW), on liver functions by measuring serum ALT and AST enzymes and liver tissue malondialdehyde level (MDA), and on histopathological changes of liver tissues after exposure of albino mice to whole-body X-radiation.

MATERIALS AND METHODS

Ethical approval

The mice were treated according to guideline 2 for the housing of mice in scientific institutions, where mice were placed in one cage, fulfilling their need for shelter and social interaction, and constantly supplied with food and water; the cages were cleaned periodically. This setup was submitted to and approved by the College of Health and Medical Technology, Sulaimani Polytechnic University (registration number MLD 00097) on 14 January

2020.

Experimental animals

In this experimental study, 24 male albino mice, 12–14 weeks old, weighing 35–45 g were obtained from the animal house at the Biology Department of the College of Education, University of Sulaimani. The mice were acclimated to the laboratory conditions. They had free access to drinking water and standard food throughout the research period.

Experimental design

The animals were divided into four different groups, with six mice in each group. The control and treated groups were designed as following: group I (negative control) received deionized water for 5 consecutive days. Group II (6 Gy) received only deionized water orally for 5 days, and was then subjected to whole-body X-irradiation at 6 Grays, applied as a one-shot dose. Group III (NSO) received only NSO orally (10 ml/kg) for 5 days without exposure to radiation. Group IV (NSO + 6 Gy) received NSO orally (10 ml/kg) for 5 days prior to irradiation, and was then exposed to whole-body X-irradiation at 6 Gy.

Irradiation

Animals in the 6 Gy group and NSO + 6 Gy were placed in separate plastic containers and irradiated to a single dose of 6 Gy whole-body X-irradiation from a 6MV X-ray linear accelerator machine (Elekta Synergy 6MV, UK). The absorbed dose rate was 4 Gy/min at a 100 cm distance. Uniform total-body X-irradiation distribution was confirmed by dosimeter, using isodose curve measurements. A test with a phantom water layer was performed in order to check self-shielding without changing the dose distribution profile for the thickness involved.

Anaesthesia/euthanasia methods

The mice were anaesthetised using the inhalation anaesthesia method. The mice were sedated inside a locked container supplied with a piece of cotton previously impregnated with 5 ml 100% diethyl ether from Scharlu chemicals. This protocol allowed the mice to be sedated within one minute. Finally, it was ensured that the mice had completely lost consciousness before being sacrificed.

Sample collection and analysis

The mice were sacrificed and both blood and liver tissue samples were immediately collected after 24 hours of exposure to 6 Gy X-irradiation. The blood samples were collected in coagulant tubes for haematological and biochemical examination that included CBC (complete blood count), ALT and AST levels. Approximately 25 mg of liver tissue was weighted out immediately after the mouse sacrifice for malondialdehyde (MDA) analysis, which was calorimetrically quantified (Oxiselect TBRAS Assay

Kit). This assay is based on the reaction of MDA with thiobarbituric acid (TBA) forming a pink chromogen read by an EMC-LAB UV-6100PC 532 nm/2nm slit-width spectrophotometer.

Histological investigation

To perform the histopathological examination, the liver soft tissue was removed after the mouse sacrifice and fixed in formalin for 48 hours. Subsequent fixation of the tissues was processed in a series of graded ethanol solutions and xylene from Scharlu chemicals for dehydration and clearing, respectively. They were then embedded in paraffin, after which blocks of 5- μ m thick paraffin sections were collected by rotary microtome (Accu-Cut SRM200) and stained with haematoxylin and eosin stain.

Nigella sativa oil extractions

Newly harvested black cumin seed grains were purchased from a local market. The grains were ground in a grinding mill then poured into a Soxhlet extractor. The extraction was processed for 5 hours using pure ethanol as a solvent at temperatures of 40–45°C inside the Soxhlet chamber. After completing the extraction, the solvent was separated by a rotor evaporator (Heidolph instruments) to obtain a blackish-brown oil.

Statistical evaluation

Data were first sorted by Microsoft Excel and statistically analyzed using one-way analysis of variance (ANOVA) in SPSS software. The p value was considered significant at $p \leq 0.05$.

RESULTS

Effects of X-irradiation on haematological parameters

In order to estimate X-irradiation effects on alteration of some haematological parameters in male albino mice, RBC, Hb, HCT, MCV, MCH and RDW values were evaluated after irradiation with and without NSO extract administration. The results showed a significant reduction ($p \leq 0.05$) in RBC count, Hb, HCT and MCV in mice exposed to whole-body X-irradiation when compared with the control group, while in presence of NSO extract all the mentioned parameters except for MCH were significantly raised ($p \leq 0.05$). Moreover, the RDW value showed an increase in the irradiated group and a slight reduction in the NSO + 6 Gy and NSO groups. Accordingly, all parameters were ameliorated and shifted toward the normal values ($p \leq 0.05$) in mice that received NSO prior to radiation (table 1).

Effects of X-irradiation on hepatocyte lipid peroxidation

As the liver is an organ sensitive toward free radical attacks, measurement of MDA in the

hepatocyte was used as a criterion for the measurement of oxidative stress. According to our results, MDA level was elevated in the 6 Gy group compared to the negative control group, while an observable decrease in MDA level was seen post oil treatment in the NSO + 6 Gy group (figure 1). Comparison of MDA results for oil-treated and irradiated oil-treated groups showed a depletion in MDA level ($p \leq 0.05$).

Table 1. Haematological parameters in the control, 6 Gy (X-irradiated), NSO and NSO + 6 Gy (X-irradiated) groups. Data are represented as mean \pm SE, $n = 5$.

Parameters	RBC ($\times 10^6/\text{mm}^3$)	Hb (mg/dl)	HCT (%)	MCV (fl)	MCH (pg)	RDW %
Control	7.07 \pm 0.14	11.15 \pm 0.07	35.5 \pm 0.91	54.5 \pm 0.06	16.14 \pm 0.84	12.5 \pm 0.25
6 Gy	6.64 \pm 0.63	10.2 \pm 0.56	33.5 \pm 0.89	51.8 \pm 0.15	15.7 \pm 0.07	14.2 \pm 0.28
NSO	8.95 \pm 0.81	14.4 \pm 0.56	55 \pm 0.96	54.55 \pm 0.75	14.8 \pm 0.07	13.15 \pm 0.21
NSO + 6 Gy	7.06 \pm 0.54	10.95 \pm 0.65	36.95 \pm 0.95	52.65 \pm 0.85	15.5 \pm 0.07	13.3 \pm 0.14

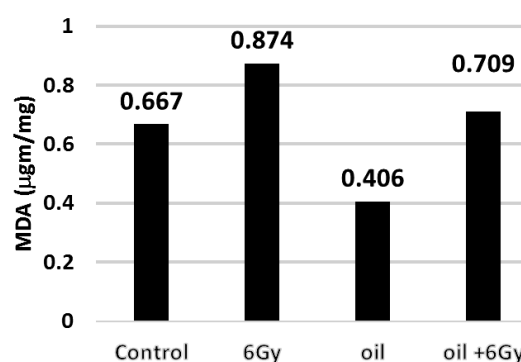


Figure 1. Levels of malondialdehyde (MDA) in mice hepatic tissues for the control group, X-irradiated group without NS oil treatment (6 Gy), NS oil-treated non-X-irradiated group (NSO), and NS oil-treated X-irradiated group (NSO + 6 Gy).

Effect of X-irradiation on liver function

Many studies have revealed ALT and AST as useful biomarkers for the prognosis and monitoring of hepatic destruction^(18,19). An elevation was observed in ALT and AST levels in the 6 Gy group when compared with the negative control group. However, ALT and AST levels showed a reduction in the NSO + 6 Gy group and shifted toward the normal values (figure 2). The obtained results revealed an increase in ALT and AST activities in the 6 Gy X-irradiation group. But in contrast to this trend, results of the NSO + 6 Gy group showed a decrease in ALT and AST values. The ALT values of the NSO + 6 Gy group were set back to less than half of the 6 Gy group. At the same time, there was a small reduction in AST level in the previous group.

Effect of X-irradiation on liver cells and tissues

To evaluate the effect of X-irradiation on liver cells and tissues, histological examinations were carried out on liver tissues in both the control and treatment groups. Liver sections of the control mice showed no

significant lesions, signified by normally arranged hepatocytes (H) organized about the central vein (CV) with normal sinusoidal capillaries (S), and a nearly normal number of Kupffer cells (figures 3 and 4). After exposing the mice to 6 Gy X-irradiation, the effects appeared in both the 6 Gy and NSO + 6 Gy groups. Group II (6 Gy) showed a diffuse and significant vacuolar degeneration (VD) within the hepatocyte cytoplasm and obvious congestion in the

central vein (CV) (figures 5 and 6). Group III (NSO) revealed small lipid vacuoles within the hepatocyte cytoplasm and normally arranged (H) (figures 7 and 8). However, group IV (NSO + 6 Gy) demonstrated a trend toward a lowered incidence of hepatic histopathological changes. Additionally, a moderate VD and a clear and non-congested CV were observed in the NSO + 6 Gy group (figures 9 and 10).

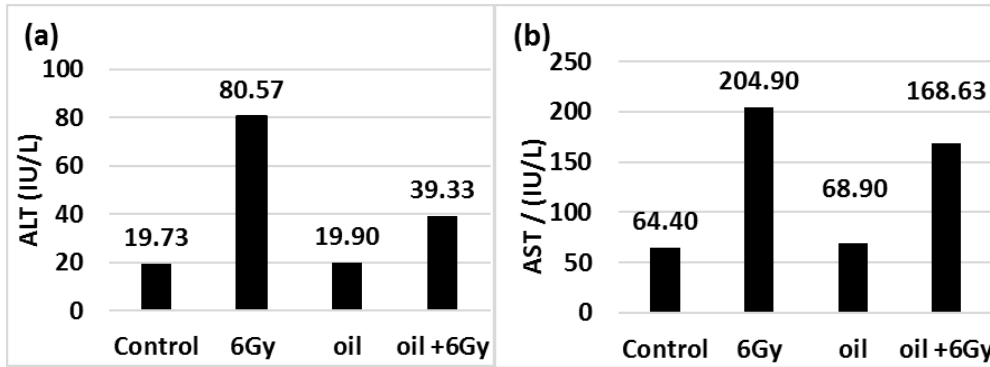


Figure 2. Activities of serum enzymes: (a) alanine aminotransferase (ALT) and (b) aspartate aminotransferase (AST) in the control group, X-irradiated group without NS oil treatment (6 Gy), NS oil-treated non-X-irradiated group (NSO), and NS oil-treated X-irradiated group (NSO + 6 Gy).

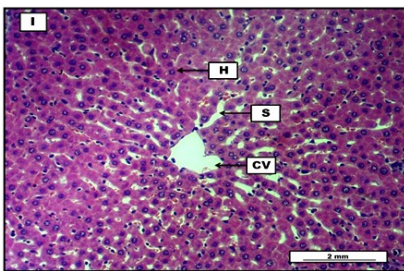


Figure 3. Photomicrograph of liver tissue from the negative control group (group I). The section shows no significant lesions signified by normally arranged hepatocytes (H) organised about the central vein (CV) with normal sinusoidal capillaries (S). H&E staining. Scale bar: 2 mm; magnification: 40X.

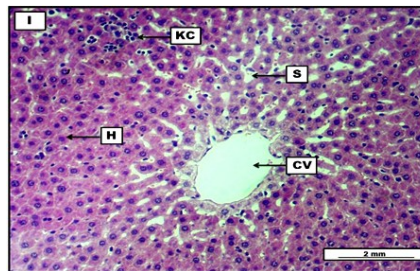


Figure 4. Photomicrograph of liver tissue from the negative control group (group I). The section shows no obvious lesions, normally arranged hepatocytes (H) surrounding the central vein (CV), together with normally presented sinusoidal capillaries (S) with some slight congestion. Presence of mild focal Kupffer cells (KC) hyperplasia. H&E staining. Scale bar: 2 mm; magnification: 40X.

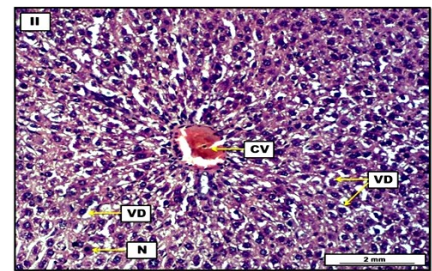


Figure 5. Photomicrograph of liver tissue from group II (6 Gy). The section shows diffuse and significant vacuolar degeneration within the hepatocytes cytoplasm (VD). Pyknotic nuclei can be seen as well (N). The segment shows obvious congestion in the central vein (CV). H&E staining. Scale bar: 2 mm; magnification: 40X.

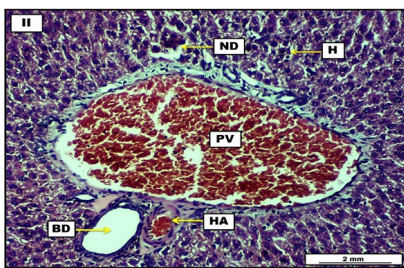


Figure 6. Photomicrograph of liver tissue from group II (6 Gy). Presence of significant vascular congestion within the cross section of a branch of portal vein (PV). Necrotic debris (ND) together with some pyknotic nuclei can also be spotted within the hepatocytes (H). Incidence of cross sections from bile duct and hepatic artery in the given zone. H&E staining. Scale bar: 2 mm; magnification: 40X.

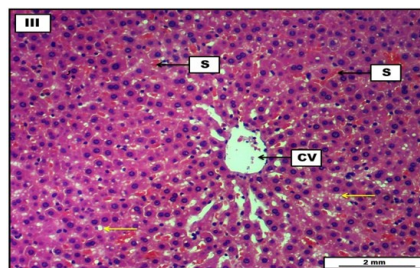

Figure 7. Photomicrograph of liver tissue from group III (NSO). The section shows mild to moderate fatty degeneration evidenced by small intracellular lipid vacuoles (yellow arrows). Hepatic sinusoids (S) show a sensible degree of vascular congestion. Cross section of a central vein (CV) also can be seen. H&E staining. Scale bar: 2 mm; magnification: 40X.

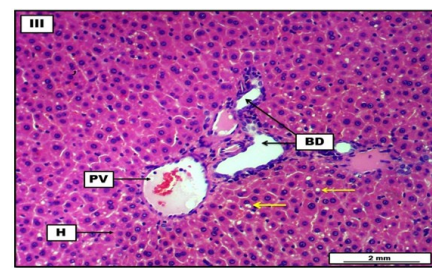


Figure 8. Photomicrograph of liver tissue from group III (NSO). The section shows moderate fatty degeneration (yellow arrows), evidenced by clear small lipid vacuoles within the hepatocyte cytoplasm. It also shows the presence of normally arranged hepatocytes (H). Moreover, cross sections from branches of bile ducts (BD) and portal vein (PV) can be seen within the portal triad. H&E staining. Scale bar: 2 mm; magnification: 40X.

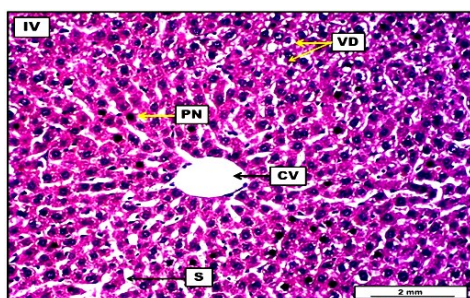


Figure 9. Photomicrograph of liver tissue from group IV (NSO + 6 Gy). The section shows moderate but still significant intracellular vacuolar degeneration (VD), as well as the presence of pyknotic nuclei (PN) within some hepatocytes and clear sinusoidal capillaries (S). H&E staining. Scale bar: 2 mm; magnification: 40X.

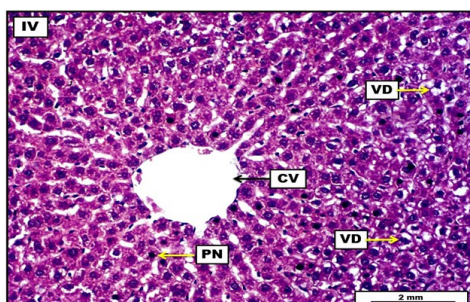


Figure 10. Photomicrograph of liver tissue from group IV (NSO + 6 Gy). The section shows moderate vacuolar degeneration (VD) within the hepatocyte cytoplasm. Moderate hepatocyte pyknotic nuclei (PN) and a clear, non-congested central vein (CV) can also be seen. H&E staining. Scale bar: 2 mm; magnification: 40X.

DISCUSSION

Despite the extensive benefits derived from radiation, it sometimes has deleterious effects due to its ability to induce oxidative stress in tissues. *Nigella sativa* oil has been suggested as a natural radioprotective agent against oxidative radiation. One part of this study was designed to determine the effects of radiation on the haematopoietic system by evaluating several haematological parameters. The significant depletions in Hb, HCT, MCV and MCH levels were also confirmed by multiple investigations showing the same trend in these parameters in mice exposed to irradiation (20, 21). The depletion in RBC value of the 6 Gy group might be due to the high percentage of polyunsaturated fatty acids in their plasma membranes and sensitivity of RBCs toward oxidative stress produced by irradiation. RBC count reduction might be an indicator of alteration in cell membrane stability and elevation in erythrocyte permeability (22, 23). These results are comparable with those of Abdelhalim *et al.* (2015), who found significant reductions post irradiation in the values of the haematological tests mentioned above (24). The elevated RDW value in the irradiated mice was in accordance with the results of a study carried out by Mehrotra *et al.* (2013), who reported a relationship

between radiation and RDW increases after radiation (25). The slight increase in RDW value might be due to an increase in RBC size accompanied with changes in the morphology and deformability of RBCs (24). The NSO + 6 Gy group showed a regain in all of the haematological parameters, except for a depletion in RDW value, compared to the non-oil-treated X-irradiated 6 Gy group. This illustrates that NSO extracts can be selected as a protective candidate substance against the adverse effects of irradiation. Assayed (2010) was able to demonstrate the radioprotective action of NSO against alteration in some haematological parameters in rats; the rats were daily intubated with NSO and then exposed to 4 Gy whole-body gamma irradiation (26). Moreover, one investigation concluded that radiation groups treated with 400 mg/kg of NSO for 25 days and 50 days showed an increase in all haematological parameters (27). These results all are in agreement with earlier findings which reported that administration of 1 gm/kg of NSO for 10 days could reduce the side effects of radiation therapy and improve recovery (28). Moreover, it was also reported by Fabiani *et al.* that administration of 0.04 mg/kg of NSO at several doses (0.01–0.1) for 30 days in mice prior to irradiation considerably elevated haematological parameters post irradiation (29).

The liver is a susceptible organ that suffers lipid peroxidation and cell dysfunction when exposed to radiation, especially with high doses and long durations (30). Protection of liver tissue from destruction initiated by free radicals can be prompted either through self-regenerative mechanisms stimulating anti-oxidative shuttles or by taking components that have antioxidant capacity (31). NSO extract is among the plant products with proven potential for reducing oxidative stress induced by radiation (32). This potential is due to NSO composition, containing volatile oil, fatty acids, and sterols such as β -sitosterol, thymoquinone and dithymoquinone (33).

The statistical analyses of the current study revealed that treatment of mice with NSO ameliorated the level of malondialdehyde in the hepatocyte compared with the non-oil-treated group (6 Gy) of mice. Furthermore, MDA levels were kept low in the NSO + 6 Gy group in congruence with the latter interpretation. Consequently, there was less cell oxidation during the NSO treatment.

The results of the ALT and AST enzymes showed that NSO administration could reduce the damaging effect of X-irradiation, as enzyme activities increased in the 6 Gy irradiation group and decreased in the NSO + 6 Gy group (34, 35). Notably, AST level slightly decreased despite NSO provision prior to irradiation. It is necessary to mention that serum AST increases as a result of liver and RBC damage, as AST exists in both hepatocytes and RBCs. The RBC could be damaged by hemolysis as ALT significantly lowered, or by destruction.

The histological examination of liver was performed for all groups. The pathological changes in X-irradiated liver tissue showed significant vascular congestion within the cross section of a branch of portal vein when compared with the control group. As is known, congestion is the main pathological change in the irradiated liver resulting from obstruction of hepatic venous outflow through a combination of endothelial cell edema and sinusoidal congestion terminal hepatic venule narrowing⁽³⁶⁾. Necrotic debris together with some pyknotic nuclei could also be spotted within the hepatocytes in the 6 Gy group, compared to those of the control group. This observation was an indicator of direct radiation injury. Moreover, a study suggested that the cause of pathological changes in the liver tissue could be a result of poor tolerance to hepatic radiation⁽³⁷⁾. The obtained results of the NSO + 6 Gy group demonstrated moderate vacuolar degeneration within the hepatocyte cytoplasm with a non-congested central vein and moderate hepatocyte pyknotic nuclei. A trend toward lowering incidence of hepatic histopathological changes in the liver tissue of mice that received NSO as a treatment prior to irradiation could be considered as an action of NSO in reducing oxidative stress effects and maintaining antioxidant defense.

CONCLUSION

Interest in the protection of normal tissues from high energy radiation has been rising. The above findings confirm that NSO efficiently prevents or mitigates the side-effects of irradiation. According to the results obtained in the this study, the administration of NSO prior to irradiation can inhibit the alteration of haematological parameters, hepatocyte lipid peroxidation and histopathological changes in the liver, as NSO is capable of reducing oxidative stress effects and maintaining antioxidant defence.

ACKNOWLEDGMENTS

The current research was supported by Sulaimani Polytechnic University, Zhianawa Cancer Center, and the University of Sulaimani, Sulaymaniyah, Iraq.

Conflicts of interest: There are no conflicts of interest to declare.

Ethical Consideration: This study was submitted to and approved by the College of Health and Medical Technology, Sulaimani Polytechnic University (registration number MLD 00097) on 14 January 2020.

Funding: there was not financial support for the study or authorship of this article.

Authors' Contribution: Soma M. Amin, Lana Mohammed, and Ary Faiq; review articles, write, and analyze data. Sabiha Salih; analyzes the

hematological parameter. Zarean Y. Saeed; assess the histopathology of the specimens. Tara Muhammed Salih & Dlshad Rashid; prepare the nigella extract, acclimatize and feed the mice, and review final issue of the study.

REFERENCES

- Desouky O, Ding N, Zhou, G (2015) Targeted and non-targeted effects of ionizing radiation. *J Radiat Res Appl Sci*, **8**(2): 247-54.
- Desouky O, Ding N, Zhou G (1970) Direct and indirect action of radiation. In *Molecular Radiation Biology* (pp. 70-90). New York, NY: Springer.
- Painuli S and Kumar N (2016) Prospects in the development of natural radioprotective therapeutics with anti-cancer properties from the plants of Uttarakhand region of India. *J Ayurveda Integr Med*, **7**(1): 62-68.
- Tan BL, Norhaizan ME, Huynh K, Heshu SR, Yeap, SK, Hazilawati, H, Roselina, K (2015) Water extract of brewers' rice induces apoptosis in human colorectal cancer cells via activation of caspase-3 and caspase-8 and downregulates the Wnt/ β -catenin downstream signaling pathway in brewers' rice-treated rats with azoxymethane-induced colon carc. *BMC CAM*, **15**(1): 205.
- Alenzi FQ, Altamimi MA, Kujan O, Tarakji B, Tamimi W, Bagader O, . . . Wys RK (2013) Antioxidant properties of Nigella sativa. *J Mol Genet Med*, **7**(3): 1-5.
- Mollazadeh H and Hosseinzadeh H (2014) The protective effect of Nigella sativa against liver injury. *Iran J Basic Med Sci*, **17**(12): 958-66.
- Velho-Pereira R, Kumar A, Pandey BN, Mishra KP, Jagtap AG (2012) Radioprotection by macerated extract of Nigella sativa in normal tissues of fibrosarcoma bearing mice. *Indian J Pharm Sci*, **74**(5): 403-14.
- Williams JP, Brown SL, Georges GE, Hauer-Jensen M, Hill RP, Huser AK, et al. (2010) Animal models for medical countermeasures to radiation exposure. *Radiat Res*, **173**(4): 557-78.
- Tan BL, Norhaizan ME, Liew WPP, Rahman HS (2018) Antioxidant and oxidative stress: A mutual interplay in age-related diseases. *Front Pharmacol*, **9**: 1162.
- Burits M, Bucar F (2000) Antioxidant activity of Nigella sativa essential oil. *Phytother Res*, **14**(5): 323-28.
- Bordoni L, Fedeli D, Nasuti C, Maggi F, Papa F, Wabitsch M, et al. (2019) Antioxidant and anti-inflammatory properties of nigella sativa oil in human pre-adipocytes. *Antioxidants*, **8**(2): 51.
- Khan MA, Chen HC, Tania M, Zhang DZ (2011) Anticancer activities of nigella sativa (black cumin). *Afr J Tradit Complement Altern Med*, **8**(5): 226-32.
- Bourgou S, Ksouri R, Bellila A, Skandrani I, Falleh H, Marzouk B (2008). Phenolic composition and biological activities of Tunisian Nigella sativa L. shoots and roots. *CR Biol*, **331**(1): 48-55.
- Anter M, Coskun O, Budancamanak M (2005) Hepatoprotective effects of Nigella sativa L and Urtica dioica L on lipid peroxidation, antioxidant enzyme systems and liver enzymes in carbon tetrachloride-treated rats. *World J Gastroenterol*, **11**(42): 6684-88.
- Meral I, Yener I, Kahraman I, Mert N (2001) Effect of Nigella sativa on glucose concentration, lipid peroxidation, anti-oxidant defence system and liver damage in experimentally-induced diabetic rabbits. *J Vet Med A Physiol Pathol Clin Med*, **48**(10): 593-99.
- Abdel-Hamid NM, Abdel-Ghany MI, Nazmy MH, Amhad SW (2013) Can methanolic extract of Nigella sativa seed affect glyco-regulatory enzymes in experimental hepatocellular carcinoma? *Environ Health Prev Med*, **18**: 49-56.
- Farah IO and Begum RA (2003) Effect of Nigella sativa (N. sativa L.) and oxidative stress on the survival pattern of MCF-7 breast cancer cells. *Biomed Sci Instrum*, **39**: 359-64.
- Sun Q, Mao W, Jiang H, Zhang X, Xiao J, Lian Y (2018) The Effect of protracted exposure to radiation on liver injury: A cohort study of industrial. *Int J Environ Res Public Health*, **15**(1): 71.
- Dufour DR, Lott JA, Nolte FS, Gretch DR, Koff RS, Seeff LB (2000) Diagnosis and monitoring of hepatic injury. I. performance characteristics of laboratory tests. *Clin Chem*, **46**(12): 2027-2049.
- Xu D, Peng M, Zhang Z, Dong G, Zhang Y, Yu H (2012) Study of damage to red blood cells exposed to different doses of γ -ray irradiation. *Blood Transfus*, **10**(3): 321-30.
- Sancheti G and Goyal PK (2007) Prevention of radiation induced haematological alterations by medicinal plant Rosmarinus officinalis.

- nalis, in mice. *Afr J Tradit Complement Altern Med*, **4**(2): 165-72.
22. Agarwal M, Purohit RK, Chakrawarti A, Basu A, Bhartyia KM (2011) Protective efficacy of Aloe vera against radiation and cadmium induced haematological changes in the Swiss albino mice. *Advanced Biotech*, **10**(10): 44-70.
23. Sharma R, Purohit RK, Sharma S, Rao R (2012) Protective role of liv. 52 against radiation and Cadmium induced haematological changes in the Swiss albino mice. Proceedings of the international conference on emerging frontiers and challenges in radiation biology, India.
24. El-Deeb AE, Abd-Aleem IM, Abd-Rahman AA (2006) The curative effect of some antioxidants on γ -irradiated rats. *Egypt Soc Toxicol*, **36**: 79-89.
25. Mehrotra S, Pecaut MJ, Gridley DS (2013) Effects of minocycline on haematopoietic recovery after whole-body irradiation. *In Vivo*, **27**(1): 11-28.
26. Assayed ME (2010) Radioprotective effects of black seed (Nigella sativa) oil against hemopoietic damage and immunosuppression in gamma-irradiated rats. *Immunopharmacol Immunotoxicol*, **32**(2): 284-96.
27. Najam LA, AL-Dulamey QK, Al-Jawwady YA (2020) Effects of low dose Gamma ray on some haematological parameters in adult rats. *Iran. J. Medical Phys*, **17**: 137-41.
28. JP T (2014) Black seed oil cures many cancer according to numerical studies. *Health Impact News*, **16**(11): 1-15.
29. Fabiani R, Rosignoli P, Bartolomeo AD, Fuccelli R, Servili M, Montedoro GF, Morozzi G (2008) Oxidative DNA damage is prevented by extracts of olive oil, hydroxytyrosol, and other olive phenolic compounds in human blood mononuclear cells and HL60 cells. *Nutr*, **138**(8): 1411-16.
30. Nakajima T, Ninomiya Y, Neno M (2019) Radiation-induced reactions in the liver modulation of radiation effects by lifestyle-related factors. *Int J Mol Sci*, **19**(12): 3855.
31. Benson R, Madan R, Kilambi R, Chander S (2016) Radiation induced liver disease. *J Egypt Natl Canc Inst*, **28**(1): 7-11.
32. Ahmad A and Alkreathy HM (2018) Comparative biochemical and histopathological studies on the efficacy of metformin and Nigella sativa oil against thioacetamide-induced acute hepatorenal damage in rats. *Biomed Res*, **29**(15): 3106-16.
33. Cheikh-Rouhoua S, Besbes S, Hentati B, Blecker C, Deroanne C, Attiaa H (2007) Nigella sativa L.: Chemical composition and physicochemical characteristics of lipid fraction. *Food Chem*, **101**(2): 673-81.
34. Dollah MA, Parhizkar S, Latiff LA, Hassan MH (2013) Toxicity effect of Nigella sativa on the liver function of rats. *Adv Pharm Bull*, **3**(1): 97-102.
35. Essawy AE, Abdel-Moneim AM, Khayyat LI, Elzergy AA (2012) Nigella sativa seeds protect against hepatotoxicity and dyslipidemia induced by carbon tetrachloride in mice. *J App Pharm Sci*, **2**(10): 21-25.
36. Reed GB and Cox AJR (1966) The human liver after radiation injury. A form of veno-occlusive disease. *Am J Pathol*, **48**(4): 597-611.
37. Takamatsu S, Kozaka K, Kobayashi S, Yoneda N, Yoshida K, Inoue D, et al. (2018) Pathology and images of radiation-induced hepatitis: a review article. *Jpn J Radiol*, **36**(4): 241-56.

