

# Multi-slice spiral CT study on the anatomical variation of the left renal vein

L. Wang, R.L. Mao, H. Xiang, C. Cheng\*

Department of Radiology, Daping Hospital, Army Medical University, Chongqing 400042, China

## ABSTRACT

### ► Original article

**\*Corresponding author:**

Cheng Cheng, Ph.D.,

E-mail: [chuopingcc@163.com](mailto:chuopingcc@163.com)

Received: February 2023

Final revised: April 2023

Accepted: May 2023

Int. J. Radiat. Res., July 2023;  
21(3): 453-457

DOI: 10.52547/ijrr.21.3.14

**Keywords:** Variation of left renal vein, multi-slice spiral CT, classification, vascular malformation.

**Background:** Background: To investigate the diagnostic value of multi-slice spiral computed tomography (MSCT) in the anatomical variation of left renal vein (LRV). **Materials and Methods:** The clinical and imaging data of 96 patients with LRV variation in our hospital from June 2019 to December 2022 were retrospectively analyzed, and the imaging manifestations, classification, and clinical significance were discussed in combination with the literature. **Results:** Among the 96 patients with LRV variation, 30 patients (30/96, 31.25%) were type I (annular aortic type), including 20 cases of type IA, 7 cases of type IB, and 3 cases of type IC. A total of 17 cases (17/96, 17.71%) were type II (complete retroaortic type), with 15 cases were type IIA and 2 cases were type IIB. There were 52 cases (52/96, 54.17%) of type III (abnormal reflux type), with 32 cases of type IIIA and 20 cases of type IIIB. There were 15 cases (15/96, 15.63%) of type IV (delayed confluence type). Taken together, 18 of the 96 patients (18/96, 18.75%) had both types of variants, including 10 cases with other types of variants accompanied by delayed confluence of the LRV, and 5 cases with other types of variants combined with abnormal reflux. **Conclusion:** Fully understanding the anatomical variation of renal vein before operation is of great guiding significance for the selection of renal transplant donors, and helps to formulate the best renal surgery plan, guide the correct treatment of renal vein before operation, avoid renal vein tear, bleeding, miscut and misligation, and reduce surgical complications.

## INTRODUCTION

The main trunk of the normal left renal vein (LRV) is composed of two to four branches that merge into one branch before exiting the renal hilum <sup>(1)</sup>. It runs in front of the renal artery, crosses the angle between the superior mesenteric artery and the abdominal aorta, and merges right into the left lateral wall of the inferior vena cava <sup>(2)</sup>. Compared with the right renal vein, the LRV is long and has many branches <sup>(3)</sup>. Its length is 6-10 cm, which is 3 times the length of the right renal vein <sup>(4)</sup>. LRV also collected many small branch veins such as left adrenal vein, left gonadal vein, and lumbar vein <sup>(5)</sup>. Anatomic variation of LRV usually refers to trunk variation, including late convergence of retroaortic left renal vein (RLRV), circumaortic left renal vein (CLRV) and LRV, malformations of left inferior vena cava or bilateral inferior vena cava, and abnormal reflux of LRV <sup>(6)</sup>. Most of the LRV variation has no clinical manifestations and is not easy to attract attention, but it has important clinical value in living donor kidney transplantation <sup>(7)</sup>.

At present, renal vascular imaging methods mainly include ultrasound, computed tomography angiography (CTA), contrast enhancement magnetic resonance angiography (CE-MRA) and digital subtraction angiography (DSA) <sup>(8)</sup>. Ultrasound

examination is non-invasive, non-radiation, simple and fast, especially color ultrasound has advantages in displaying blood flow, but ultrasound images lack three-dimensional sense, it is not easy to find finer vascular branches, and it is easy to be affected by the operator's experience <sup>(9)</sup>. CE-MRA is non-invasive, radiation-free, requires less contrast agent, and has a small probability of side effects. However, factors such as longer scanning time, more contraindications, higher requirements for patients to hold their breath, and low accuracy of the optimal time for capturing renal angiography will affect the image quality and the detection of small branches <sup>(10)</sup>. DSA is the gold standard for the diagnosis of renal vascular diseases, but it is invasive and expensive <sup>(11)</sup>. Renal vessel multi-slice spiral CTA (MSCTA) examination is non-invasive, safe, rapid, and has few contraindications <sup>(12)</sup>. The spatial resolution of multi-slice spiral CT in the Z axis is significantly improved, reaching isotropic, and the slice thickness is thin <sup>(13)</sup>. There is no need for thick slice scanning and thin slice reorganization, and the signal-to-noise ratio is higher <sup>(14)</sup>. Using multi-slice spiral CT, the optimal time of renal artery imaging can be accurately captured by contrast agent tracer trigger scanning technology, the image quality is good, and can display sufficient concentration of renal veins while displaying renal arteries. Therefore, CTA has gradually become the

preferred method for evaluating renal vessels <sup>(15)</sup>.

In this study, the anatomical variation of LRV was studied by multi-slice spiral CT, and the types and clinical significance of LRV anatomical variation were discussed. Our study applied multi-slice spiral CT to assess the anatomical variation of LRV, which was beneficial for the selection of renal transplant donors, and helped to formulate the best renal surgery plan.

## MATERIALS AND METHODS

### Patients

From June 2019 to December 2022, a total of 96 patients with LRV anatomical variations were included in the study, including 50 males and 46 females, aged from 20-78 years, with a mean age of  $(49.23 \pm 14.23)$  years. Patients with kidney congenital development and abnormal location, renal disease affecting renal vasculature, left kidney adjacent organs or retroperitoneal lesions involving renal vessels affecting observers, and cardiac dysfunction or inferior vena cava lesions affecting renal venous return were excluded. This study was carried out with the approval of the ethics committee of Daping Hospital, Army Medical University (Registration No. 2023(126), January, 2021).

### Instruments and methods

256-layer MSCT machines (Brilliance iCT, Phillips, Netherlands) were used. The scan range was mid-upper or full abdomen.

The patient was placed in the supine position and underwent plain scan, arterial phase, portal venous phase, and equilibrium phase enhanced scanning. The contrast agent dosage (Visipaque, 370 mgI/mL) was calculated as 2 mL/Kg body weight. The maximum total dose of each patient was 120 mL, and the injection rate was 3.5-4.0 mL/s. The delay times were 25 s in the arterial phase, 55 s in the portal phase, and 90 s in the equilibrium phase.

Scanning conditions: 120 kVp, intelligent mA, pitch 0.984, volume data acquisition. After the completion of scanning, the original data were transferred to active data warehouse (ADW) 4.3 post-processing workstation (GE company, USA) for routine reconstruction in the transverse axis (slice thickness of 5 mm) and coronal view (slice thickness of 3 mm), and then transferred to picture archiving and communication system (PACS) for image interpretation.

### Image analysis

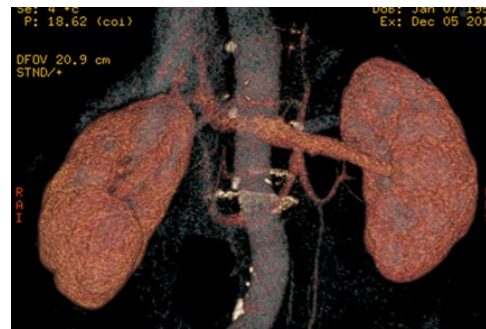
Image postprocessing such as multiplanar reconstruction (MPR), thin-block maximum density projection (MIP), and volume rendering (VR) was performed by two abdominal radiologists on PACS and/or ADW 4.3 postprocessing workstations. Imaging interpretation, mainly observe the start and

end of LRV, number, course, location and branch, etc. Patients with LRV variation were included in this study. When the opinions of two physicians were different, one more physician with higher seniority was added, and the three physicians reached a consensus through discussion.

## RESULTS

There were 50 males and 46 females in 96 patients with LRV variation, and there was no significant difference in the incidence of LRV variation between men and women ( $P > 0.05$ ).

Among the 96 patients with LRV variation, 30 patients (30/96, 31.25%) were type I (annular aortic type), including 20 cases of type IA (figure 1), which showed that the anterior and posterior branches of the main LRV ran around the abdominal aorta, the anterior branch ran normally, and the posterior branch could drain into inferior vena cava (IVC) at the same or lower level.

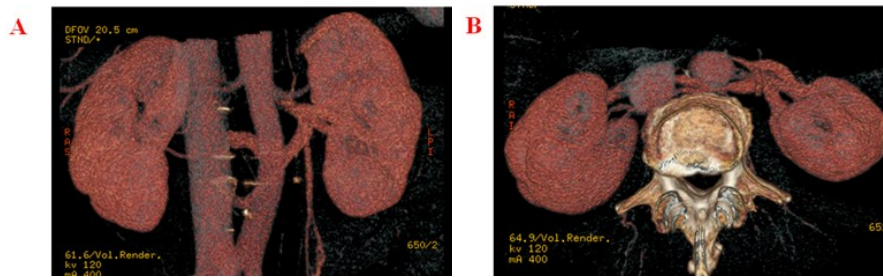


**Figure 1.** Images of type IA LRV variant. MSCT 3D reconstruction showed that the main LRV was divided into two anterior and posterior branches running around the abdominal aorta. The ventral branch ran normally, and the dorsal branch passed between the abdominal aorta and the vertebral body into the right IVC at the level of the third lumbar vertebra.

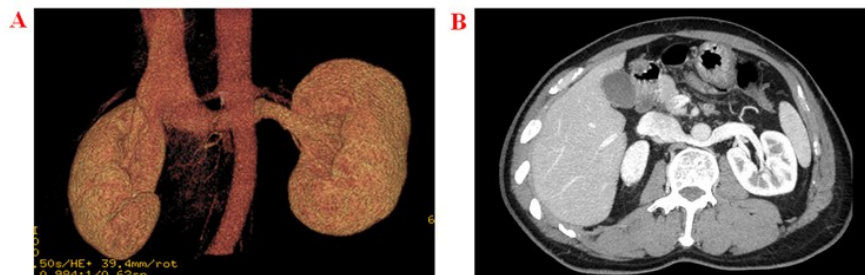
A total of 7 cases of type IB, which showed that the two renal veins were not confluent, which originated from the renal hilum and ran actively from the abdominal ring, the anterior branch ran normally, and the posterior branch was at the same level or low level into IVC.

A total of 3 cases of type IC (figure 2A-2B), which showed that the LRV trunk was divided into anterior and posterior branches that ran around the abdominal aorta, the anterior branch was normal, and the posterior branch was at the same level or low recurrence branch into IVC.

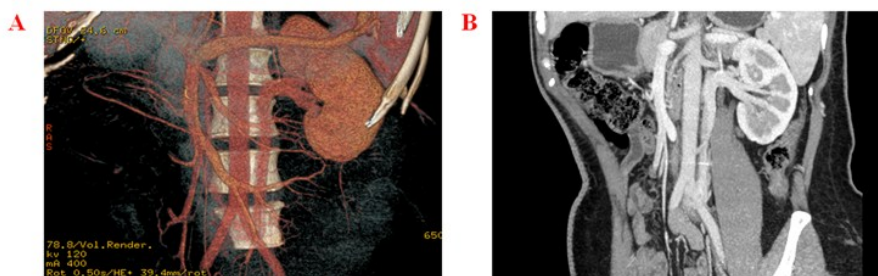
A total of 17 cases (17/96, 17.71%) were type II (complete retroaortic type), and 15 cases were type IIA (figure 3A-3B). The main trunk of the LRV flowed into the IVC at the normal level or low level behind the abdominal aorta. A total of 2 cases were type IIB (figure 4A-4B), which presented as LRV injection into left common iliac vein.



**Figure 2.** Images of type IC variant of LRV. **(A)** The coronal view of MSCT three-dimensional reconstruction, a delayed round of the LRV was observed. After the round, the main trunk was divided into two anterior and posterior branches running around the abdominal aorta, the ventral branch running normally, and the dorsal branch running into the right IVC through the posterior branch of the abdominal aorta. **(B)** The transverse view of MSCT three-dimensional reconstruction, a delayed round of the LRV was observed. After the round, the main trunk was divided into two anterior and posterior branches running around the abdominal aorta, the ventral branch (long arrow) running normally, and the dorsal branch running into the right IVC through the posterior branch of the abdominal aorta.



**Figure 3.** Images of type IIA LRV variant. **(A)** MSCT 3D reconstruction showed the main LRV draining into the right IVC posterior to the abdominal aorta at the level of the second lumbar vertebra. **(B)** Transverse axis view showed the main LRV draining into the right IVC posterior to the abdominal aorta at the level of the second lumbar vertebra.



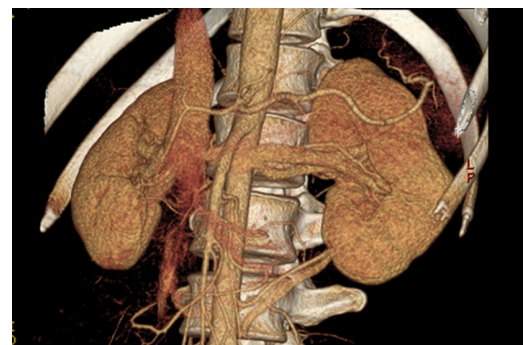**Figure 4.** Images of type IB variant of LRV. **(A)** MSCT 3D reconstruction showed the main LRV draining low into the left common iliac vein. **(B)** Coronal view showed the main LRV draining low into the left common iliac vein.

There were 52 cases (52/96, 54.17%) of type III (abnormal reflux type) and 32 cases of type IIIA (figure 5). The main LRV ran normally, and branch vessels were seen in the upper or lower pole to drain into IVC, left common iliac vein, lumbar vein or hemiazygous vein. 20 cases were type IIIB (figure 6A-6B), which manifested as the main LRV draining into adjacent veins, including left IVC or double IVC.

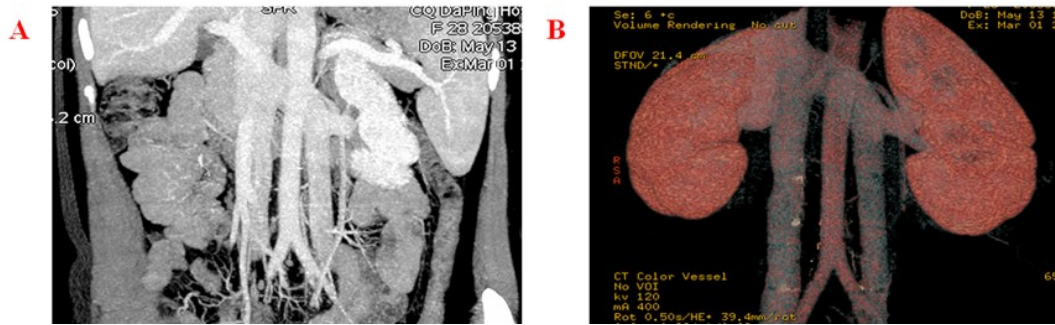
There were 15 cases (15/96, 15.63%) of type IV

(delayed confluence type, figure 7), showing that the distance between the posterior hilar confluence of double or multiple LRVs and the left edge of the abdominal aorta was  $\leq 1.5$  cm. Taken together, 18 of the 96 patients (18/96, 18.75%) had both types of variants, including 10 cases with other types of variants accompanied by delayed confluence of the LRV, and 5 cases with other types of variants combined with abnormal reflux.

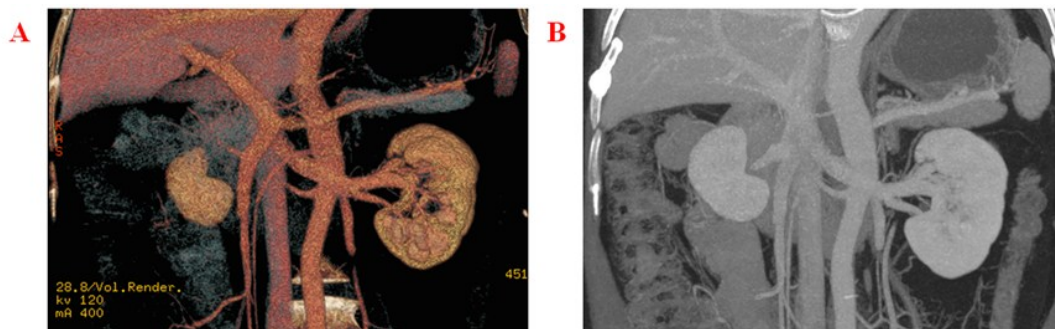
**Figure 5.** Images of type IIIA variant of LRV. MSCT 3D reconstruction showed normal course of the main LRV, delayed confluence of the LRV, and the branch of the accessory renal vein in the lower pole of the left kidney ran behind the abdominal aorta and merged into the IVC.







**Figure 6.** Images of type IIIB variant of LRV. (A) Coronal MIP showed a double IVC malformation with the main LRV draining into the left IVC. (B) 3D reconstruction showed a double IVC malformation with the main LRV draining into the left IVC.



**Figure 7.** Images of type IV variant of the LRV. (A) MSCT 3D reconstruction showed that the LRV was divided into three branches and delayed renal confluence into the main renal vein draining into IVC. (B) Coronal MIP showed that the LRV was divided into three branches and delayed renal confluence into the main renal vein draining into IVC.

## DISCUSSION

The main LRV consisted of two to four branches that converged into one before exiting the kidney (16). The main trunk of the LRV runs in front of the renal artery, oblique to the right front, passes through the Angle between the abdominal aorta and the superior mesenteric artery, and drains into the inferior vena cava (17).

LRV variations can be divided into V major types: type I CLR, which contains three subtypes (6). The trunk of type IA LRV is divided into anterior and posterior branches around the abdominal aorta and injected into IVC respectively. The two LRV of type IB originates from the renal hilum, and the anterior branch runs normally, and the posterior branch is injected into the IVC through the posterior abdominal aorta. The main trunk of type IC LRV is divided into anterior and posterior branches, and anastomosed branches or recurrent branches of posterior branches are injected into IVC during the course of the two branches going to the right (18). Type II RLRV, the main LRV runs behind the abdominal aorta, including two subtypes. Type IIA LRV is injected into the IVC at a normal or low level. Type IIB LRV is injected into the left common iliac vein (19). Type III abnormal reflux, including 2 subtypes, type IIIA LRV is injected into IVC normally with abnormal branches into the normal IVC, left ovarian vein, common iliac vein, or hemiazygous vein. Type IIIB LRV is injected directly into adjacent veins, such as left IVC and double IVC (20). Type IV renal vein confluence is

delayed, and the distance between the LRV exiting the renal hilar confluence and the left margin of the abdominal aorta is  $\leq 1.5$  cm (21). Type V is a rare type (22). In line with the above reports, the results of our study indicated that among the 96 patients with LRV variation, 30 patients (31.25%) were type I, including 20 cases of type IA, 7 cases of type IB, and 3 cases of type IC. A total of 17 cases (17.71%) were type II, with 15 cases were type IIA and 2 cases were type IIB. There were 52 cases (54.17%) of type III, with 32 cases of type IIIA and 20 cases of type IIIB. There were 15 cases (15.63%) of type IV. Taken together, 18 of the 96 patients (18.75%) had both types of variants, including 10 cases with other types of variants accompanied by delayed confluence of the LRV, and 5 cases with other types of variants combined with abnormal reflux.

The length of LRV is longer than that of the right renal vein, and there are many types of variation (23). Multiple post-processing reconstruction techniques of MSCT are very important to display the anatomical variation of LRV (24). The best time for MSCT scanning to observe the main trunk of LRV is the late arterial stage. The clarity of VR image of renal vein in this stage is better than that in the venous stage, which is beneficial to display the spatial structure of renal vein (25). The clinical significance of LRV anatomical variation is helpful for preoperative evaluation of renal surgery and diagnosis of related diseases due to the long length of LRV and the large number of branches (26). At present, the research of preoperative CT three-dimensional vascular reconstruction mainly

focuses on arteries, but the variation of intraoperative veins is also important, and it is necessary to analyze the veins in detail, especially for patients undergoing laparoscopic renal surgery (27). Due to the limitation of small surgical field and surgical exposure, comprehensive and careful evaluation of renal vessels before surgery is helpful to vascular separation and avoids vascular injury (28).

In conclusion, fully understanding the anatomical variation of renal vein before operation is of great guiding significance for the selection of renal transplant donors, and helps to formulate the best renal surgery plan, guide the correct treatment of renal vein before operation, avoid renal vein tear, bleeding, miscut and misligation, and reduce surgical complications.

#### ACKNOWLEDGMENT

None.

**Funding:** This work was supported by the Chongqing Clinical Research Center for Imaging and Nuclear Medicine, Chongqing, China (CSTC2015YFPT-gcjsyjzx0175), Chongqing Key Clinical Program Fund for Radiology from Chongqing Health Commission (2022).

**Conflict of interest:** The authors confirm they have no conflicts of interest to declare.

**Ethical consideration:** This study was carried out with the approval of the ethics committee of Daping Hospital, Army Medical University (Registration No. CSTC2015YFPT, January, 2021).

**Author contribution:** L.W., R.L.M. and H.X. participated in the study design and the literature search. L.W., R.L.M., H.X. and C.C. collected the data and wrote the manuscript. L.W., R.L.M., H.X. and C.C. revised the manuscript. All authors read and approved the final manuscript.

#### REFERENCES

- Idhrees M and Velayudhan B (2022) Retroaortic left renal vein in open thoracoabdominal aneurysm repair: A modified approach. *Eur J Cardiothorac Surg*, **62**(4): Ezac452.
- Selberherr A, Mari M, Klinger M, et al. (2022) Left Renal Vein Division for Juxtarenal Aortic Exposure: Influence on Renal Function and Role of the Communicating Lumbar Vein. *World J Surg*, **46**(6): 1493-9.
- Lewis DS, Grimm LJ, Kim CY (2015) Left renal vein compression as cause for varicocele: prevalence and associated findings on contrast-enhanced CT. *Abdom Imaging*, **40**(8): 3147-51.
- Zhang J and Li T (2022) Stent in Left Renal Vein Stuck at the Opening of Tricuspid Valve. *Ann Thorac Surg*, **113**(2):e91-e4.
- Brancatelli G, Galia M, Finazzo M, et al. (2000) Retroaortic left renal vein joining the left common iliac vein. *Eur Radiol*, **10**(11): 1724-5.
- Kuzan TY, Kuzan BN, Telli TA, et al. (2020) Evaluation of the frequency of left renal vein variations in computed tomography and its relationship with cancer development. *Folia Morphol (Warsz)*, **79**(4): 793-8.
- Yi SQ, Ueno Y, Naito M, et al. (2012) The three most common variations of the left renal vein: a review and meta-analysis. *Surg Radiol Anat*, **34**(9): 799-804.
- Heiss SG, Shifrin RY, Sommer FG (2000) Contrast-enhanced three-dimensional fast spoiled gradient-echo renal MR imaging: evaluation of vascular and nonvascular disease. *Radiographics*, **20**(5):1341-52.
- Cohen DL, Weinberg I, Uretsky S, et al. (2021) Imaging strategies for safety surveillance after renal artery denervation. *Clin Res Cardiol*, **110**(5): 609-19.
- Laurence I, Ariff B, Quest RA, et al. (2012) Is there a role for free breathing non-contrast steady-state free precession renal MRA imaging for assessing live donors? A preliminary study. *Br J Radiol*, **85**(1016):e448-54.
- Mueller-Peltzer K, Rübenthaler J, Fischereder M, et al. (2017) The diagnostic value of contrast-enhanced ultrasound (CEUS) as a new technique for imaging of vascular complications in renal transplants compared to standard imaging modalities. *Clin Hemorheol Microcirc*, **67**(3-4): 407-13.
- Liu J, Yang S, Jin H, et al. (2018) The diagnostic value of multi-slice spiral computed tomography in patients with renal carcinoma. *J Cancer Res Ther*, **14**(4): 795-8.
- Chen L, Qi L, Zhang J, et al. (2021) Neutrophil-lymphocyte ratio as a prognostic factor for minute clear cell renal cell carcinoma diagnosed using multi-slice spiral CT. *Medicine (Baltimore)*, **100**(23): e26292.
- Peng N, Wang X, Zhang Z, et al. (2016) Diagnosis value of multi-slice spiral CT in renal trauma. *J Xray Sci Technol*, **24**(5): 649-55.
- Ming WD, Li XG, Xue HD, et al. (2014) Role of multi-slice computed tomography angiography in the diagnosis of visceral artery aneurysms. *Zhongguo Yi Xue Ke Xue Yuan Xue Bao*, **36**(3): 296-9.
- Haładaj R, Polguy M, Wysiadeci G, et al. (2019) Circumaortic left renal vein (circumaortic renal collar) associated with the presence of vascular anomalies: a case series and review of literature. *Folia Morphol (Warsz)*, **78**(2): 437-43.
- Lopez-Lopez V, Garcia-Lopez J, Eshmuninov D, et al. (2022) Left renal vein graft and in situ hepatic perfusion in hepatectomy for complete tumor invasion of hepatic veins: hemodynamic optimization and surgical technique. *Langenbecks Arch Surg*, **407**(4): 1-7.
- Satyapal KS (1995) Classification of the drainage patterns of the renal veins. *J Anat*, **186** (Pt 2): 329-33.
- Sonawane GB, Moorthy KH, Pillai BS (2020) Newer variants of retroaortic left renal vein. *Indian J Urol*, **36**(2): 142-3.
- Tao XF, Zhu JQ, Wu YW, et al. (2013) Dual-energy computed tomography angiography for evaluating the renal vascular variants. *Chin Med J (Engl)*, **126**(4): 650-4.
- Koc Z, Ulsan S, Oguzkurt L (2007) Association of left renal vein variations and pelvic varices in abdominal MDCT. *Eur Radiol*, **17**(5): 1267-74.
- Zhu J, Zhang L, Yang Z, et al. (2015) Classification of the renal vein variations: a study with multidetector computed tomography. *Surg Radiol Anat*, **37**(6): 667-75.
- Lee HN, Hyun D, Park KB, et al. (2021) CT findings after left renal vein division during abdominal aortic surgery. *Acta Radiol*, **62**(12): 1679-86.
- Boyacı N, Karakas E, Dokumacı DS, et al. (2014) Evaluation of left renal vein and inferior vena cava variations through routine abdominal multi-slice computed tomography. *Folia Morphol (Warsz)*, **73**(2): 159-63.
- Ayaz S and Ayaz ÜY (2016) Detection of retroaortic left renal vein and circumaortic left renal vein by PET/CT images to avoid misdiagnosis and support possible surgical procedures. *Hell J Nucl Med*, **19**(2): 135-9.
- Tatarano S, Enokida H, Yamada Y, et al. (2019) Anatomical Variations of the Left Renal Vein During Laparoscopic Donor Nephrectomy. *Transplant Proc*, **51**(5):1311-3.
- Dilli A, Ayaz UY, Kaplanoğlu H, et al. (2013) Evaluation of the left renal vein variations and inferior vena cava variations by means of helical computed tomography. *Clin Imaging*, **37**(3): 530-5.
- Powell AC, Plitas G, Muhs BE, et al. (2006) Left renal vein reconstruction after right nephrectomy and inadvertent left renal vein ligation: a case report and review of the literature. *Vasc Endovascular Surg*, **40**(5): 421-4.

