

Efficacy and safety of ultrasound-guided percutaneous laser ablation in the treatment of unifocal papillary thyroid microcarcinoma

J. Gu^{1,2#}, X. Fan^{3#}, X. Sun⁴, Z. Yu², X. Zhu^{1*}

¹Department of Interventional Radiology, The First Affiliated Hospital of Soochow University, Suzhou, Jiangsu Province 215006, PR China

²Department of Ultrasonography, The Affiliated Suzhou Hospital of Nanjing Medical University, Suzhou, Jiangsu Province 215001, PR China

³Department of Ultrasonography, The Affiliated Suzhou Science and Technology Town Hospital of Nanjing Medical University, Suzhou 215000, Jiangsu Province, PR China

⁴Department of Intervention, The Second Affiliated Hospital of Soochow University, Suzhou 215004, Jiangsu Province, China

ABSTRACT

► Original article

*Corresponding author:

Xiaoli Zhu, Ph.D.,

E-mail: zhuxiaoli90@163.com

Received: February 2023

Final revised: May 2023

Accepted: May 2023

Int. J. Radiat. Res., July 2023;
21(3): 577-584

DOI: 10.52547/ijrr.21.3.30

Keywords: Papillary thyroid microcarcinoma, percutaneous laser ablation, ultrasound, efficacy, safety.

Background: Ultrasound-guided percutaneous laser ablation (US-PLA), as a minimally invasive ablation method, has been widely used in the treatment of benign and malignant tumors. The objective of the current study was to determine the efficacy and safety of US-PLA for unifocal papillary thyroid microcarcinoma (PTMC). **Materials and Methods:** Totally 18 PTMC patients underwent US-PLA at our hospital were selected. Tumor location, tumor volume and thyroid function of patients were examined before percutaneous laser ablation (PLA). Contrast-enhanced ultrasound (CEUS) was performed immediately after PLA treatment. Complications, thyroid function, ablation area size and volume, tumor recurrence rate and metastasis rate were recorded. **Results:** Eighteen nodules were completely ablated in 18 patients, and postoperative CEUS showed no contrast fill in the ablated areas. Fifteen patients underwent single needle and single PLA ablation, and 3 cases underwent a second ablation due to incomplete ablation as confirmed by CEUS. All patients tolerated and completed ablation with no serious complications. The maximum diameter and volume of the ablation zones at 6, 12, 18, and 24 months after PLA were significantly smaller than the preoperative nodules ($P < 0.05$). The number of tumors that completely disappeared at 6, 12, 18, and 24 months was 1 (5.7%), 6 (38.9%), 4 (61.1%), and 2 (72.2%), respectively. No local tumor recurrence, lymph node metastasis and distant metastasis occurred. **Conclusion:** US-PLA is a safe and effective technique for unifocal PTMC treatment, which may provide a new therapeutic option for PTMC patients who are not eligible or unwilling to receive surgery.

INTRODUCTION

In recent years, with the prevalence of medical examination and the clinical application of high-resolution ultrasound, thyroid nodule has become a common disease, and its incidence and detection rate increase every year ⁽¹⁾. Currently, the detection rate of thyroid nodules has reached 20%-76%, and 5%-13% are malignant tumors ⁽²⁾. Among them, papillary thyroid carcinoma (PTC) is the most common subtype of thyroid cancer. The common symptom of PTC is a painless mass in the neck, most of which move up and down with swallowing, and a few of which are accompanied with hoarseness, dysphagia and pressure ⁽³⁾. Papillary thyroid microcarcinoma (PTMC) refers to PTC with a diameter of ≤ 10 mm. The occurrence of PTMC is influenced by hormonal, genetic, environmental and

other factors, such as radioactivity, goitrogenic substances, and iodine deficiency ⁽⁴⁾. With the promotion of ultrasound-guided fine needle aspiration biopsy (US-FNAB), the detection rate of PTMC has increased significantly ⁽⁵⁾.

Surgical resection is a classic and dominant treatment method for PTMC. However, in recent years, many scholars indicate that total lobectomy is unnecessary for PTMC with the drawback of need for lifelong medication ^(6, 7). Surgical procedures for PTMC require general anesthesia and leave a postoperative scar of about 4-6 cm in the neck, which discourages some patients who cannot tolerate surgery and have aesthetic requirements. In fact, PTMC with a "mild" biological behavior and slow growth, is usually associated with a good prognosis and low mortality, and the diagnosis and treatment strategy and method selection have become a hot

topic at home and abroad ^(6,8).

Ito *et al.* ⁽⁹⁾ have followed up 340 patients with confirmed PTMC and found that 84.1% of them without increase in tumor size during 5 to 10 years of follow-up, and the effect on survival is not statistically significant. Also, none of the 1235 low-risk PTMC patients without immediate surgery develop distant metastases or die from PTMC during the observation period of 1.5 to 19 years. Thus, they conclude that follow-up observation rather than immediate surgery is also a good choice for these low-risk PTMC patients. However, patients with suspicious nodules often feel anxious after biopsy confirmation of PTMC, which seriously affects their quality of life. Therefore, some patients with PTMC prefer to undergo minimally invasive ablation firstly to actively manage the tumor lesions and then receive regular follow-up observation. In a meta-analysis of 12 studies (1284 nodules in a total of 1187 PTMC patients treated with thermal ablation) by Tong *et al.* ⁽¹⁰⁾, all three ablation modalities (radiofrequency, microwave, and laser ablation) significantly reduced tumor volume in PTMC. In this study, no distant metastases occur during the follow-up period (mean 7.8 months), and few major complications are encountered in terms of safety. A systematic evaluation of 503 low-risk PTMC nodes in 470 patients treated by thermal ablation is performed by Cho *et al.* ⁽¹¹⁾, which indicates that no patient develops local tumor recurrence or distant metastases, even though two patients (0.4%) develop lymph node metastases, one patient (0.2%) develops a new PTMC, which can all be successfully treated by another ablation; five patients (1.1%) undergo delayed surgery after ablation, including two patients with lymph node metastasis and three patients with unknown etiology, and even if surgery is performed after ablation, it does not cause any impact on the procedure itself or survival. Therefore, more and more scholars believe that thermal ablation for PTMC has the advantages of precise operation, small trauma, high safety, rapid recovery and high efficacy, and it has developed into one of the most promising minimally invasive treatment methods ⁽¹²⁾.

Ultrasound-guided percutaneous laser ablation (US-PLA) is a minimally invasive interventional method that has been successfully applied in the treatment of benign thyroid nodules with considerable clinical efficacy in recent years ^(13, 14). Similar to radiofrequency ablation (RFA), percutaneous laser ablation (PLA) causes irreversible coagulative necrosis by generating high temperature to the local tissue. Compared with RFA and microwave ablation (MWA), PLA has unique advantages in the treatment of cervical diseases adjacent to vital organs due to its small laser fiber needle and precise and controllable output energy ^(15, 16). It has been applied as an alternative surgical treatment to some PTMC patients, and the results

reveal that PLA can effectively kill PTMC without recurrence ⁽¹⁷⁾. Moreover, PLA treatment has the advantages of thin and flexible laser fiber bundles, accurate, objective and controllable energy output, making it possible to accurately and safely perform thyroid nodule ablation ⁽¹³⁾. As reported previously, US-PLA is a safe and effective alternative clinical treatment for low-risk PTMC ^(18, 19). Other studies also support the application of PLA in the treatment of PTMC cervical lymphatic metastases ⁽²⁰⁾. However, overall, studies of US-PLA for PTMC are still in the initial stage.

The purpose of this study was to investigate the safety and efficacy of US-PLA in the treatment of PTMC, and to provide a clinical basis for early intervention in PTMC patients. The accuracy of US-PLA for thyroid nodule ablation in PTMC patients and its effects on PTMC patient prognosis are the novelties of this study.

MATERIALS AND METHODS

Patients

This was a retrospective study. From January 2017 to June 2020, 18 patients with single PTMC lesions treated by US-PLA were included. The demographic and clinical characteristics information of patient was summarized in table 1. There were 6 men and 12 women, aged between 23 and 58 years old (mean age 40.0 ± 9.5). The present study was approved by the Ethics Committee of the Affiliated Suzhou Science & Technology Town Hospital of Nanjing Medical University. A written informed consent document was obtained from all patients before the procedure. Inclusion criteria were as follows: (1) PTMC confirmed by fine-needle aspiration biopsy (FNAB). (2) A single tumor with a maximum diameter of less than or equal to 10 mm. (3) A tumor without contact or invasion of the thyroid capsule. (4) Normal cardiopulmonary function. (5) Normal blood tests, such as routine blood and coagulation function. (6) No cervical or distant lymph node metastasis. (7) Patients who could not tolerate or refuse surgical treatment.

Exclusion criteria were as follows: (1) Patients with multiple nodules, or nodules larger than 10 mm in diameter. (2) Patients with lymph node metastasis or distant metastasis. (3) Patients with tumors that invaded the thyroid capsule or important organs. (4) Patients with severe cardiopulmonary dysfunction. (5) Patients treated with thyroid surgery or radioiodine treatment. (6) Abnormal contralateral vocal cord function. (7) Patients without complete follow-up information.

Pre-PLA observation

The tumor locations, diameters, volumes and ultrasonographic characteristics were evaluated by

ultrasonography (TOSHIBA Apli0500 Ultrasound Instrument; High Frequency Linear Array Probe, frequency of 10 MHz; Toshiba, Tokyo, Japan). Blood tests included serum thyroid stimulating hormone (TSH), free triiodothyronine (FT3), free tetraiodothyronine (FT4), thyroglobulin (TG), anti-TG

antibody, and routine blood and coagulation function. The tumor volume was calculated as follows: $V = \pi \cdot a \cdot b \cdot c / 6$ (where V is the volume, a is the maximum diameter, and b and c are the other maximum vertical diameters).

Table 1. Statistics on the clinical characteristics of PTMC patients treated with PLA.

Patient No.	Sex/Age (years)	Lobar location	Size before PLA (mm)	Serum thyroglobulin before PLA (ng/ml)	PLA ablation time (s)	No. of ablation procedures	Follow-up (months)
1	F/44	L	6.4×2.9×3.5	0.13	159	1	25.5
2	M/39	L	7.8×6.5×4.9	0.17	327	1	25.1
3	M/37	R	9.1×3.3×6.4	0.09	199	1	28.6
4	F/30	L	4.8×3.7×3.8	0.25	245	2	25.4
5	F/53	L	8.7×5.0×4.8	0.16	488	1	28.3
6	F/31	L	5.2×2.8×3.3	0.11	211	1	27.9
7	F/23	R	4.5×3.1×2.8	0.21	349	1	26.5
8	F/40	L	8.4×6.8×6.5	0.13	187	1	24.2
9	F/49	R	6.4×5.6×5.4	0.09	236	1	29.4
10	M/57	R	8.9×5.8×4.9	0.13	190	2	24.5
11	F/37	R	9.4×7.3×5.6	0.14	393	1	31.1
12	M/40	L	9.3×7.1×4.6	0.08	385	1	26.2
13	F/45	R	7.6×3.5×6.8	0.10	416	1	27.1
14	M/32	L	8.5×4.1×2.8	0.19	522	2	29.6
15	F/33	R	9.1×4.4×7.2	0.22	183	1	29.8
16	F/37	L	6.0×4.5×4.0	0.17	166	1	25.4
17	F/35	R	9.4×7.0×6.1	0.12	235	1	26.7
18	M/58	L	4.5×3.9×2.7	0.14	208	1	27.9

PLA, percutaneous laser ablation; F, female; M, male; L, left; R, right; PTMC, papillary thyroid microcarcinoma.

PLA method

The patient was in a supine position, and the neck was fully exposed. Ultrasound-guided local anesthesia with 2% lidocaine was used after routine disinfection and towel laying. A 21 G guided needle was then fixed in the center of the nodule. Then, a needle core was inserted with optical fibers, and the guided needle was retreated 5 mm to the tip of the optical fibers to contact the nodule directly. The laser ablation system was switched on for continuous ablation. Laser ablation power was 4 W-6 W, and a single-point and constant ablation was performed until the high echo in the ablation area completely covered the proposed range. The ablation focus was at least 0.1 cm above the edge of the nodule (figure 1B/2B). If the patient did not feel any obvious discomfort, the power would be slowly increased. A volume of 20 ml of hydro dissection solution could be used to avoid thermal damage if tumors were close to the recurrent laryngeal nerve (RLN), common carotid artery or jugular vein. If patients felt obvious pain or discomfort during ablation, power would be reduced or the ablation would be suspended. The ablation should be ceased when nodules were completely covered by strong echoes. Contrast-enhanced ultrasonography (CEUS) was performed 5 minutes after ablation (figure 1C/2C). If there was still nodule enhancement in the ablation area, further ablation was feasible. Throughout the procedure, we intermittently asked about the feeling of patients to assess pain levels and vocal status. After the procedure, the puncture area was covered with ice

and compressed for 30 minutes and patients were observed in the hospital for 24 hours.

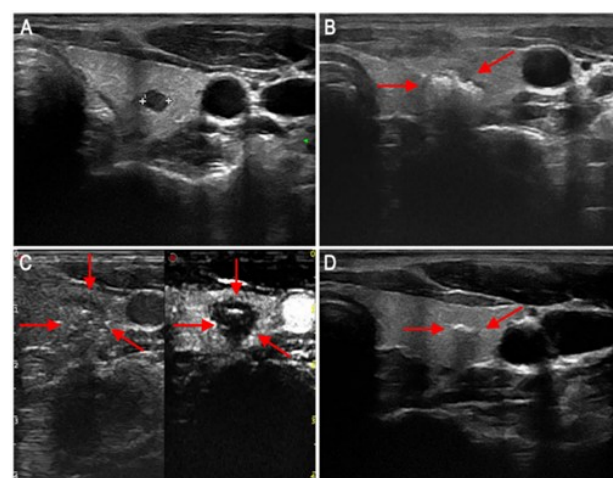


Figure 1. Preoperative ultrasound images of a patient with PTMC on the left side of the neck. **A:** Preoperative ultrasound showed a hypoechoic nodule with a size of 5.2×2.8×3.3 mm, ultrasound-guided biopsy confirmed the tumor as PTMC. **B:** Intraoperative ultrasound showed the typical hyperechoic region (red arrow) during ablation. **C:** Postoperative CEUS shows that the ablation area is larger than the preoperative nodule and there is no contrast filling in the ablation area, suggesting complete ablation. **D:** Six months later, ultrasound showed a scar like tissue with a size of 4.2×1.2×1.7 mm. PTMC, papillary thyroid microcarcinoma; CEUS, contrast-enhanced ultrasound.

Post-PLA observation and follow-up

Complications and tumor volumes were recorded. Patients were followed at 1, 3, 6, 12, 18,

and 24 months and every six months thereafter following PLA. Laboratory tests and ultrasonography were performed at each follow-up visit. The lesion size, blood supply and necrosis were observed via ultrasound or CEUS. If suspected metastatic lymph nodes and suspected thyroid parenchymal lesions were found, US-FNAB examination was performed. Laboratory tests including serum TSH, FT3, FT4, TG and anti-TG antibody were detected by electrochemiluminescence immunoassay (ECLIA) on a Roche Cobas 6000 e 601 analyzer (Roche Diagnostics, Germany). The volume reduction ratio (VRR) was calculated using the following equation: $VRR = ([\text{initial volume} - \text{final volume}] / \text{initial volume}) \times 100\%$ (21).

Statistical analysis

Analysis was carried out using SPSS 19.0 (IBM Corporation, Chicago, IL, USA) and quantitative variables were reported as the mean \pm standard deviation (SD). A matched t-test was performed on the volume and maximum diameter at different follow-up time points. P values <0.05 were considered to indicate statistical significance.

RESULTS

General characteristics of PTMC patients

From January 2017 to June 2020, 18 patients with single PTMC lesions treated by US-PLA in our department were enrolled in this study. These patients included 13 women and 5 men with a mean age of 40.0 ± 9.5 years (range, 23-58 years). Of the 18 lesions, 10 were located on the left side and 8 on the right side. The mean maximum lesion diameter was 7.4 ± 1.8 mm (range, 4.5-9.4 mm), and the mean lesion volume was 101.8 ± 64.1 mm³ (range, 20.5-210.2 mm³). No thyroid hormone abnormalities were detected in all patients preoperatively, and the active time during PLA was 283.3 ± 115.4 s (range, 159-522 s). In addition, 15 of the 18 patients underwent single needle and single PLA ablation, and 3 cases underwent a second ablation due to incomplete ablation as confirmed by CEUS (table 1).

Complications and prognosis

During the PLA procedure, all patients (100%) felt self-limited neck swelling to some extent. 15 patients (83.3%) experienced varying degrees of neck pain and burning during the procedure, and 14 patients were able to tolerate the entire procedure. Once the ablation procedure was completed, the pain decreased or disappeared, with only 1 patient receiving a 5.0 mg intramuscular dezocine injection. One patient (5.56%) developed cough and fever on day 7 after PLA, which was relieved after symptomatic treatment. There were no cases of neck hematoma, surgical area infection trachea, esophagus

and other important organ injury during surgery. However, a 33-year-old woman was found with hypothyroidism 1 month after PLA surgery, and her thyroid hormone levels recovered the next month without the administration of medication. A 55-year-old woman developed hoarseness after surgery, and returned to normal 2 months after the ablation procedure without any specific treatment. None of these complications were life-threatening or led to some sequelae. No cervical lymph node metastasis or distant metastasis cases were found during the ensuing follow-up (table 2).

Table 2. Complications and prognosis of PTMC patients treated with PLA.

Complications	No. (%)	Actions Taken
Neck swelling	100%(18/18)	None, self-limiting
Pain	83.3%(15/18)	14 patients were well tolerated and 1 patient received 5 mg of dezocine injection
Cough and fever	5.6%(1/18)	Effective symptomatic treatment
Hoarseness	5.6%(1/18)	None, self-limiting
Neck hematoma	0%(0/18)	-
Local infection	0%(0/18)	-
Vital organ injury	0%(0/18)	-
Serum hormone abnormalities	5.6%(1/18)	None, self-limiting
local recurrence	0%(0/18)	-
Cervical lymph node metastasis	0%(0/18)	-
Distant metastasis	0%(0/18)	-

PTMC, papillary thyroid microcarcinoma.

Measurement of Pre, intra and post-PLA

Preoperative ultrasound revealed a hypoechoic nodule (figure 1A/2A). The entire PLA procedure was performed under real-time ultrasound monitoring, and intraoperative ultrasound showed that irregular and hyperechoic gasification areas began to appear around the mass with the release of ablation energy (figure 1B/2B). The pre-ablation image was used to compare whether the ablated area covered and surpassed the original lesion. A CEUS examination was performed immediately after PLA, and the outcomes showed no contrast perfusion in the ablated area, suggesting that the ablation was complete (figure 1C/2C). Six months later, ultrasound showed a hyperechoic nodule in the ablation area (figure 1D/2D). The follow-up time ranged from 24.2 months to 31.1 months, with an average follow-up time of 27.2 ± 2.0 months. During the follow-up period, ultrasound dynamic examination confirmed the disappearance of blood perfusion in the ablation area.

Efficacy of PLA for reducing PTMC nodule volume

The maximum diameter, volume, and volume reduction ratio (VRR) of the tumors before and after PLA were shown in table 3 and figure 3A/3B/3C. The mean volume of the 18 nodules before PLA was 101.8 ± 64.1 mm³, and the maximum diameter and volume

of the ablated areas at 1 hour, 1 month, and 3 months after PLA were significantly larger than those of the preoperative nodules because the enlarged ablation of all tumor lesions was performed ($P<0.05$). However, the maximum diameter and volume of the ablated area were decreased gradually at 6, 12, 18, and 24 months after PLA, all of which were significantly smaller than the preoperative nodules ($P<0.05$). The VRR was -738%, -256%, -92%, 26%, 80%, 94%, and 96% at 1 hour, 1 month, 3 months, 6 months, 12 months, 18 months, and 24 months after PLA, respectively. At the 6th month after PLA, the VRR started to change from negative to positive values, which may be caused by the charred necrotic tissue gradually absorbed by the body.

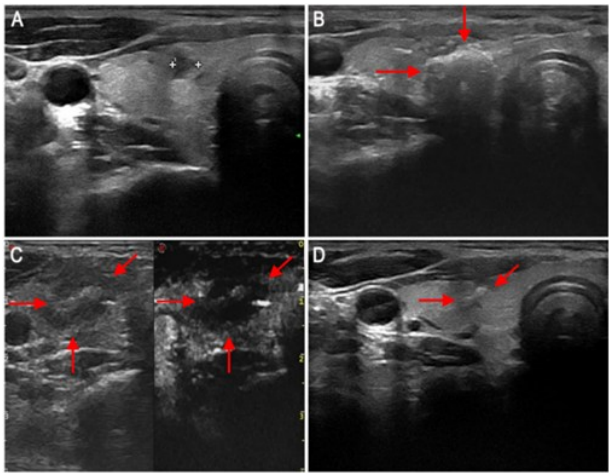


Figure 2. Preoperative ultrasound images of a patient with PTMC on the right side of the neck. **A:** Preoperative ultrasound showed a hypoechoic nodule with a size of 4.5×3.1×2.8 mm, ultrasound-guided biopsy confirmed the tumor as PTMC. **B:** Intraoperative ultrasound showed a vaporized area (red arrow) during ablation. **C:** CEUS showed a vaporized cavity in the ablation area after operation. **D:** Six months later, ultrasound showed a scar like tissue with a size of 2.1×0.8×1.1 mm. PTMC, papillary thyroid microcarcinoma; CEUS, contrast-enhanced ultrasound.

Table 3. Maximum diameter and volume of PTMC nodules in patients before and after PLA treatment.

Time	Maximum diameter (mm)	P-value	Volume (mm ³)	P-value	VRR (%)
Pre-PLA (n=18)	7.4±1.8	-	101.8±64.1	-	-
Post-PLA					
1 hour (n=18)	18.1±3.9	<0.001	1039.5±799.8	<0.001	-737.5±608.6
1 month (n=18)	13.9±4.2	<0.001	754.8±499.7	<0.001	-256.4±126.7
3 months (n=18)	9.4±3.1	<0.001	396.5±221.8	<0.001	-92.4±70.9
6 months (n=17)	5.2±2.5	<0.001	64.3±76.4	<0.01	25.8±20.3
12 months (n=11)	2.1±1.2	<0.001	9.7 ± 7.4	<0.001	80.1±16.4
18 months (n=7)	1.4±0.9	<0.001	6.5 ± 3.1	<0.001	93.5±15.7
24 months (n=5)	1.0±0.5	<0.001	3.2 ± 1.5	<0.001	96.1±11.4

PTMC, papillary thyroid microcarcinoma; PLA, percutaneous laser ablation.

At the final follow-up, 13 cases (72.2%) showed complete disappearance of the ablated lesions on ultrasound and 5 cases (27.8%) retained scar-like changes. The number of tumors that completely disappeared at 6, 12, 18, and 24 months was 1 (5.7%), 6 (38.9%), 4 (61.1%), and 2 (72.2%), respectively. No local tumor recurrence, lymph node metastasis or distant metastasis occurred. None of the patients died of PTMC during the follow-up period.

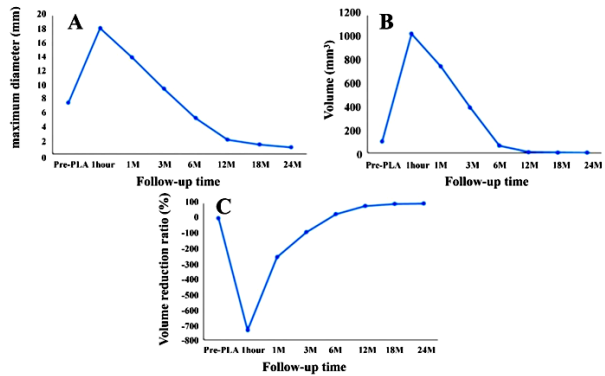


Figure 3. The effects of US-PLA on PTMC nodule reduction in the follow-up periods. Changes in the maximum diameter (**A**), volume (**B**), and volume reduction ratio (**C**) of the tumors at each follow-up. US-PLA, ultrasound-guided percutaneous laser ablation; PTMC, papillary thyroid microcarcinoma; M, month.

DISCUSSION

In recent decades, despite the increasing incidence of PTMC, surgical excision remains the mainstay of treatment worldwide (22). However, traditional surgical resection may cause detachment of the thyroid gland, with the risks of varying degrees of hypothyroidism (23). Surgical resection for PTMC may be conducted with excessive resection and increase sense of insecurity in patients, which has been controversial for many years (24, 25). Some scholars believe that total thyroidectomy for PTMC is unnecessary and expanding thyroidectomy does not improve surgical outcomes (26). However, some also argue that lymph node metastasis does not affect the survival rates of PTMC patients, and preventive lymph node dissection is unnecessary for PTMC patients without suspected lymph node metastasis (27-29). Therefore, in the current clinical environment, an effective minimally invasive treatment of PTMC is urgently needed.

PLA is first used in the treatment of hepatic, uterine and adrenal diseases (30-32). Pacella *et al.* (33) have preliminarily verified the efficacy of PLA to treat benign thyroid nodules. US-PLA treatment, a promising minimally invasive treatment for thyroid nodules, has shown multiple advantages in clinical practice, including simple operation, minimal invasiveness, stable coagulation range, safety and

quick recovery ⁽³⁴⁾. Dossing *et al.* ⁽³⁵⁻³⁷⁾ have performed PLA 3 times for 16, 30, and 78 patients with benign cold thyroid nodules and he finds that the nodular volume reduction ratios 6 months after PLA are 46%, 44%, and 51%, respectively, suggesting that PLA can effectively reduce tumors. In 2010, PLA was recommended as an effective and safe method for thyroid nodules according to the American Society of Clinical Endocrinologists, the Italian Society of Clinical Endocrinology and the European Thyroid Association ⁽³⁸⁾. Therefore, the proper application of PLA in the treatment of thyroid diseases meets the needs of modern medicine development.

In our study, the VRR was -738%, -256%, -92%, 26%, 80%, 94%, and 96% at 1 hour, 1 month, 3 months, 6 months, 12 months, 18 months, and 24 months after PLA, respectively. We performed enlarged ablation to ensure complete ablation of the lesion, so that the volume of the ablated area was significantly larger than the primary lesion at 1 hour, 1 month, and 3 months after PLA. At each follow-up time point after PLA, color doppler ultrasound confirmed the absence of blood flow signal in the ablated area and CEUS confirmed the absence of nodular enhancement signal in the ablated area, indicating that PLA treatment was effective for PTMC. With the absorption of charred necrotic tissue, the area of the ablation zone gradually decreased, and the VRR reached 96% in the second year after PLA. In the study by Ji *et al.* ⁽³⁹⁾, 37 patients with solitary PTMC treated by PLA had a mean volume increasing multiplier of 96% in the second year after PLA, which is consistent with our findings. At the final follow-up, 13 cases (72.2%) showed complete disappearance of the ablated lesion on ultrasound and 5 cases (27.8) retained scar-like changes, further confirming the effective ablation of the lesion by PLA. In a meta-analysis of 1187 patients with PTMC ⁽¹⁰⁾, complete disappearance of tumors after ablation is 34%-91%, which may be related to the size and characteristics of the tumors in different studies and the follow-up period.

In the study by Peng *et al.* ⁽¹⁸⁾, a recurrence rate of 2.9% (3/105) is observed in 105 patients with PLA-treated unifocal PTMC lesions at a minimum 5-year follow-up. Two patients have metastatic central cervical lymph nodes identified 24 months after PLA and both subsequently undergo open surgical resection. A new PTMC lesion is found 12 months after PLA in 1 patient, and the patient undergoes a second laser ablation. No recurrence or lymph node metastasis occurs during the subsequent 3-year follow-up. No significant recurrent lesions or lymph node metastases are observed in any of the other 102 patients. In many other studies, the local recurrence rate after ablation is also no higher than 0.5% ^(10, 40, 41). Ji *et al.* ⁽³⁹⁾ have found that only 2.7% of patients develop cervical lymph node metastases

during the follow-up after PLA treatment. In our study, no patients with local recurrence, lymph node metastasis or distant metastasis were identified during the two-year postoperative follow-up period, similar to the results of Zhou *et al.* ⁽⁴²⁾. Complete and enlarged ablation of the tumor may be beneficial to reducing the local recurrence and metastasis rates of the tumor.

The thyroid gland is adjacent to important structures such as RLN, carotid artery, parathyroid glands, esophagus and trachea, making surgical treatment of thyroid disease risky. PLA have its unique advantages in the treatment of small thyroid lesions close to important structures in the neck. In the study by Valcavi *et al.* ⁽⁴³⁾, 122 patients with benign thyroid nodules are treated with PLA. 1.6% of patients develop delayed laryngeal dysfunction after 6-10 weeks and 3.2% develop abnormal thyroid function. In our study, none of the 18 patients developed serious complications such as RLN, tracheal or esophageal injury after PLA. One patient developed cough and fever on day 7 after PLA, which was unrelated to PLA treatment and was resolved with symptomatic treatment. One patient developed hoarseness, which returned to normal on its own 2 months after PLA, probably due to laryngeal nerve compression caused by perinodular edema. One patient had hypothyroidism, probably due to excessive ablation, which did not require any clinical treatment and resolved spontaneously after 3 months. In addition, all patients (100%) felt self-limited neck swelling to some extent, which may be related to post-ablation parenchymal edema of the thyroid gland.

Hypothyroidism is a common complication after surgical resection treatment. In the study by Ding *et al.* ⁽⁴⁴⁾, the incidence of hypothyroidism after surgical resection for PTMC is as high as 75%, because the surgery also removes a large amount of normal thyroid tissue. By contrast, PLA is a minimally invasive treatment that destroys the tumor while preserving the integrity of the thyroid gland as much as possible, thus significantly reducing the incidence of hypothyroidism after PLA ⁽¹⁹⁾. TSH is a very sensitive and specific indicator of thyroid function ⁽⁴⁵⁾. FT3 and FT4 are a true reflection of thyroid metabolism, with the advantages of being not affected by the changes of binding protein concentration and binding properties, and they are the most sensitive and valuable indicator to reflect thyroid function ⁽⁴⁶⁾. The detection of TG can distinguish complete thyroid defect and thyroid hypoplasia ⁽⁴⁷⁾. Anti-TG is also considered as a special marker of thyroid body shape integrity. It is a tumor marker for differentiated thyroid cancer, and can be used as an important reference index for follow-up of patients with differentiated thyroid cancer after treatment ⁽⁴⁸⁾. Abnormal levels of serum TSH, FT3, FT4, TG and anti-TG are makers of hypothyroidism

(49). Here, through detecting the levels of these markers, no thyroid hormone abnormalities were detected in all patients preoperatively, which was consistent with the above studies.

During the process of PLA treatment, attention should be paid to the following aspects: (1) Hydrodissection solution should be used when the distance between nodules and vital organs is less than 5 mm. (2) The temperatures of the thyroid and vital organs must be monitored: once the temperature is too high, energy output must be reduced. (3) If the nodule adheres to the trachea or blood vessels, the nodule can be ablated partially. (4) If one side of RLN is injured, the other side of RLN should be avoided during ablation to avoid asphyxia. Although PLA exhibits considerable clinical efficacy in treating PTMC in the present study, it still must be further improved. (1) More patients and long-term follow-up need to be investigated in the ensuing studies. (2) New imaging techniques, such as computerized three-dimensional stereotaxic technology, could be used to reduce the damage surrounding vital tissues during the PLA process. (3) There are few comparative studies between thermal ablation and surgical resection, which need to be further investigated.

CONCLUSIONS

In this retrospective study, US-PLA was found to effectively reduce PTMC nodules with favorable prognosis and no severe complications in PTMC patients, suggesting that US-PLA is a precise and safe method with good treatment results, minimal trauma and no surgical scars, and can be applied as an alternative for unifocal PTMC therapy.

Original article statement

This original article has been preprinted in Research Square⁽⁵⁰⁾ with an assigned DOI of 10.21203/rs.3.rs-260933/v2. All authors confirm the originality of this article and declare that this paper is not under consideration for submission to other journals.

Availability of data and material

Research data can be obtained from corresponding author upon reasonable request.

ACKNOWLEDGMENT

None.

Funding: This work was supported by the Suzhou Basic Research Application under Grant NO. SYSD2020080, Suzhou Medical and health application technology innovation project under Grant NO. SKJYD2021086, Maternal and child health scientific research project of Jiangsu Province under Grant NO. FYX202019.

Conflicts of interests: All authors declare that they have no conflict of interest.

Ethical consideration: The study was approved by the ethics committee of The Affiliated Suzhou Science & Technology Town Hospital of Nanjing Medical University (approval number: 2017LL-2020) and consent to participate from the patient was available.

Author contribution: Conceptualization, data analysis and validation, draft writing: J.G. and X.F.; Data collection, analysis and visualization: X.S., Z.Y.; Supervision, review, and editing: X.Z. All authors have read and agreed to the submitted version of the manuscript.

REFERENCES

- Holt EH (2021) Current Evaluation of Thyroid Nodules. *Med Clin North Am*, **105**(6): 1017-31.
- Cho BY, Choi HS, Park YJ, et al. (2013) Changes in the clinicopathological characteristics and outcomes of thyroid cancer in Korea over the past four decades. *Thyroid*, **23**(7): 797-804.
- Coca-Pelaz A, Shah JP, Hernandez-Prera JC, et al. (2020) Papillary Thyroid Cancer-Aggressive Variants and Impact on Management: A Narrative Review. *Adv Ther*, **37**(7): 3112-28.
- Ito Y, Miyauchi A, Oda H (2018) Low-risk papillary microcarcinoma of the thyroid: A review of active surveillance trials. *Eur J Surg Oncol*, **44**(3): 307-15.
- Min Y, Wang X, Chen H, et al. (2020) Thermal Ablation for Papillary Thyroid Microcarcinoma: How Far We Have Come? *Cancer Manag Res*, **12**: 13369-79.
- Mauri G, Orsi F, Carriero S, et al. (2020) Image-Guided Thermal Ablation as an Alternative to Surgery for Papillary Thyroid Microcarcinoma: Preliminary Results of an Italian Experience. *Front Endocrinol (Lausanne)*, **11**: 575152.
- Xu B, Zhou NM, Cao WT, et al. (2018) Comparative study on operative trauma between microwave ablation and surgical treatment for papillary thyroid microcarcinoma. *World J Clin Cases*, **6**(15): 936-43.
- Cao XJ, Yu MA, Zhu YL, et al. (2021) Ultrasound-guided thermal ablation for papillary thyroid microcarcinoma: a multicenter retrospective study. *Int J Hyperthermia*, **38**(1): 916-22.
- Ito Y, Miyauchi A, Inoue H, et al. (2010) An observational trial for papillary thyroid microcarcinoma in Japanese patients. *World J Surg*, **34**(1): 28-35.
- Tong M, Li S, Li Y, et al. (2019) Efficacy and safety of radiofrequency, microwave and laser ablation for treating papillary thyroid microcarcinoma: a systematic review and meta-analysis. *Int J Hyperthermia*, **36**(1): 1278-86.
- Cho SJ, Baek JH, Chung SR, et al. (2019) Thermal Ablation for Small Papillary Thyroid Cancer: A Systematic Review. *Thyroid*, **29**(12): 1774-83.
- Bo XW, Lu F, Xu HX, et al. (2020) Thermal Ablation of Benign Thyroid Nodules and Papillary Thyroid Microcarcinoma. *Front Oncol*, **10**: 580431.
- Mauri G, Nicosia L, Della Vigna P, et al. (2019) Percutaneous laser ablation for benign and malignant thyroid diseases. *Ultrasonography*, **38**(1): 25-36.
- Rahal Junior A, Falsarella PM, Mendes GF, et al. (2018) Percutaneous laser ablation of benign thyroid nodules: a one year follow-up study. *Einstein (Sao Paulo, Brazil)*, **16**(4): eAO4279.
- Cheng Z, Che Y, Yu S, et al. (2017) US-Guided Percutaneous Radiofrequency versus Microwave Ablation for Benign Thyroid Nodules: A Prospective Multicenter Study. *Scientific Reports*, **7**(1): 9554.
- Morelli F, Sacchini A, Pompili G, et al. (2016) Microwave ablation for thyroid nodules: a new string to the bow for percutaneous treatments? *Gland surgery*, **5**(6): 553-8.
- Zhou W, Zhang L, Zhan W, et al. (2016) Percutaneous laser ablation for treatment of locally recurrent papillary thyroid carcinoma <15 mm. *Clinical Radiology*, **71**(12): 1233-9.
- Peng K, Zhou P, Liu W (2021) Long-Term Efficacy of Ultrasound-Guided Percutaneous Laser Ablation for Low-Risk Papillary Thyroid Microcarcinoma: A 5-Year Follow-Up Study. *Biomed Res Int*, **2021**: 6616826.

19. Zhang L, Zhang GP, Zhan WW, *et al.* (2022) The feasibility and efficacy of ultrasound-guided percutaneous laser ablation for multifocal papillary thyroid microcarcinoma. *Front Endocrinol (Lausanne)*, **13**: 921812.
20. Mauri G, Cova L, Ierace T, *et al.* (2016) Treatment of metastatic lymph nodes in the neck from papillary thyroid carcinoma with percutaneous laser ablation. *Cardiovascular and Interventional Radiology*, **39**(7): 1023-30.
21. Cao XJ, Liu J, Zhu YL, *et al.* (2021) Efficacy and safety of thermal ablation for solitary T1bN0M0 papillary thyroid carcinoma: A multicenter study. *J Clin Endocrinol Metab*, **106**(2): e573-e81.
22. Zhi J, Zhao J, Gao M, *et al.* (2018) Impact of major different variants of papillary thyroid microcarcinoma on the clinicopathological characteristics: the study of 1041 cases. *International Journal of Clinical Oncology*, **23**(1): 59-65.
23. Kaliszewski K, Diakowska D, Wojtczak B, *et al.* (2019) The occurrence of and predictive factors for multifocality and bilaterality in patients with papillary thyroid microcarcinoma. *Medicine*, **98**(19): e15609.
24. Jeon MJ, Kim WG, Kwon H, *et al.* (2017) Clinical outcomes after delayed thyroid surgery in patients with papillary thyroid microcarcinoma. *European Journal of Endocrinology*, **177**(1): 25-31.
25. Xue S, Wang P, Hurst ZA, *et al.* (2018) Active Surveillance for Papillary Thyroid Microcarcinoma: Challenges and Prospects. *Frontiers in Endocrinology*, **9**: 736.
26. Lin L, Xiao J, Shi L, *et al.* (2019) STRA6 exerts oncogenic role in gastric tumorigenesis by acting as a crucial target of miR-873. *Journal of Experimental & Clinical Cancer Research: CR*, **38**(1): 452.
27. Xu Y, Xu L, Wang J (2018) Clinical predictors of lymph node metastasis and survival rate in papillary thyroid microcarcinoma: analysis of 3607 patients at a single institution. *The Journal of Surgical Research*, **221**: 128-34.
28. Tang J, Liu HB, Yu L, *et al.* (2018) Clinical-pathological Characteristics and Prognostic Factors for Papillary Thyroid Microcarcinoma in the Elderly. *Journal of Cancer*, **9**(2): 256-62.
29. Wang X, Lei J, Wei T, *et al.* (2019) Clinicopathological characteristics and recurrence risk of papillary thyroid microcarcinoma in the elderly. *Cancer Management and Research*, **11**: 2371-7.
30. Chai W, Zhao Q, Kong D, *et al.* (2019) Percutaneous laser ablation of hepatic tumors located in the portacaval space: Preliminary results. *Lasers in Surgery and Medicine*, **51**(10): 866-873.
31. Hindley JT, Law PA, Hickey M, *et al.* (2002) Clinical outcomes following percutaneous magnetic resonance image guided laser ablation of symptomatic uterine fibroids. *Human Reproduction (Oxford, England)*, **17**(10): 2737-41.
32. Jiang T and Chai W (2018) Endoscopic ultrasonography (EUS)-guided laser ablation (LA) of adrenal metastasis from pancreatic adenocarcinoma. *Lasers in Medical Science*, **33**(7): 1613-6.
33. Pacella CM, Bizzarri G, Spiezia S, *et al.* (2004) Thyroid tissue: US-guided percutaneous laser thermal ablation. *Radiology*, **232**(1): 272-80.
34. Pacella CM, Mauri G, Cesareo R, *et al.* (2017) A comparison of laser with radiofrequency ablation for the treatment of benign thyroid nodules: a propensity score matching analysis. *International journal of hyperthermia: the official journal of European Society for Hyperthermic Oncology, North American Hyperthermia Group*, **33**(8): 911-9.
35. Dossing H, Bennedbaek FN, Karstrup S, *et al.* (2002) Benign solitary solid cold thyroid nodules: US-guided interstitial laser photocoagulation--initial experience. *Radiology*, **225**(1): 53-7.
36. Dossing H, Bennedbaek FN, Hegedus L (2011) Long-term outcome following interstitial laser photocoagulation of benign cold thyroid nodules. *European Journal of Endocrinology*, **165**(1): 123-8.
37. Dossing H, Bennedbaek FN, Hegedus L (2005) Effect of ultrasound-guided interstitial laser photocoagulation on benign solitary solid cold thyroid nodules - a randomised study. *European Journal of Endocrinology*, **152**(3): 341-5.
38. Baek JH, Lee JH, Valcavi R, *et al.* (2011) Thermal ablation for benign thyroid nodules: radiofrequency and laser. *Korean Journal of Radiology*, **12**(5): 525-40.
39. Ji L, Wu Q, Gu J, *et al.* (2019) Ultrasound-guided percutaneous laser ablation for papillary thyroid microcarcinoma: a retrospective analysis of 37 patients. *Cancer Imaging*, **19**(1): 16.
40. Ding M, Tang X, Cui D, *et al.* (2019) Clinical outcomes of ultrasound-guided radiofrequency ablation for the treatment of primary papillary thyroid microcarcinoma. *Clin Radiol*, **74**(9): 712-7.
41. Wang L, Xu D, Yang Y, *et al.* (2019) Safety and efficacy of ultrasound-guided percutaneous thermal ablation in treating low-risk papillary thyroid microcarcinoma: A pilot and feasibility study. *J Cancer Res Ther*, **15**(7): 1522-9.
42. Zhou W, Jiang S, Zhan W, *et al.* (2017) Ultrasound-guided percutaneous laser ablation of unifocal T1N0M0 papillary thyroid microcarcinoma: Preliminary results. *Eur Radiol*, **27**(7): 2934-40.
43. Valcavi R, Riganti F, Bertani A, *et al.* (2010) Percutaneous laser ablation of cold benign thyroid nodules: a 3-year follow-up study in 122 patients. *Thyroid*, **20**(11): 1253-61.
44. Ding B, Yu JF, Sun W, *et al.* (2017) Surgical safety analysis of retaining the glands in papillary thyroid microcarcinoma. *Eur Rev Med Pharmacol Sci*, **21**(2): 234-8.
45. Boi F, Minerba L, Lai ML, *et al.* (2013) Both thyroid autoimmunity and increased serum TSH are independent risk factors for malignancy in patients with thyroid nodules. *J Endocrinol Invest*, **36**(5): 313-20.
46. Otun J, Sahebkar A, Östlundh L, *et al.* (2019) Systematic review and meta-analysis on the effect of soy on thyroid function. *Sci Rep*, **9**(1): 3964.
47. Kurimoto C, Inaba H, Ariyasu H, *et al.* (2020) Predictive and sensitive biomarkers for thyroid dysfunctions during treatment with immune-checkpoint inhibitors. *Cancer Sci*, **111**(5): 1468-77.
48. Ostrowska L, Gier D, Zyśk B (2021) The Influence of Reducing Diets on Changes in Thyroid Parameters in Women Suffering from Obesity and Hashimoto's Disease. *Nutrients*, **13**(3).
49. Karpuzoglu H, Ucal Y, Kumru P, *et al.* (2022) Increased maternal leptin levels may be an indicator of subclinical hypothyroidism in a newborn. *J Med Biochem*, **41**(2): 156-61.
50. Jun-Gu FX, Sun X, Yu Z, Zhu X (2022) Efficacy and safety of ultrasound-guided percutaneous laser ablation in the treatment of unifocal papillary thyroid microcarcinoma. *Research Square*, 1-18.