

Dual-source CT imaging in evaluating cardiovascular function after coronary artery bypass grafting

Q. Chen and C. Zhang*

Department of Cardiovascular Medicine, Affiliated Hospital of Chengdu University, No. 82, North Section 2, 2nd Ring Road, Jinniu District, Chengdu, Sichuan Province, China

ABSTRACT

► Short report

***Corresponding author:**

Chunwei Zhang, Ph.D.,

E-mail: alex-zcw@163.com

Received: March 2023

Final revised: June 2023

Accepted: June 2023

Int. J. Radiat. Res., October 2023;
21(4): 837-840

DOI: 10.52547/ijrr.21.4.33

Keywords: Dual-source CT imaging, coronary artery bypass grafting, cardiac function, vascular patency and lesions.

Background: To explore the diagnosis and evaluation efficacy of liver iron concentration (LIC) based on magnetic resonance quantitative technique in liver iron overload in patients with long-term transfusion. **Materials and Methods:** From November 2021 to January 2023, 30 chronic aplastic anemia (CAA) patients with long-term blood transfusion admitted to our hospital were included as the study group. Simultaneously, 20 healthy volunteers with matched gender and age were included in the control group. The serum ferritin (SF), serum iron, total iron binding capacity and transferrin saturation (TSAT) between the two groups was calculated and compared. LIC was evaluated using Liver Magnetic resonance imaging (MRI)-T2* map imaging. The correlation between LIC and SF and TSAT was analyzed, and the diagnosis value of LIC in hepatic iron overload was calculated. Low-risk patients (n=22) diagnosed with iron overload received continuous regular iron removal treatment and the SF, TSAT and LIC were measured after 6 months. **Results:** SF, TSAT and LIC were higher in CAA patients relative to the healthy controls ($P<0.05$). LIC was positively correlated with SF ($r=0.74$, $P<0.001$) and TSAT ($r=0.67$, $P<0.001$). The sensitivity and specificity of LIC in the diagnosis of hepatic iron overload were 80.00% and 100% based on SF, and 76.0% and 100% based on TSAT, respectively. Additionally, SF, TSAT and LIC were all declined after 6 months of treatment ($P<0.05$). **Conclusion:** The detection of LIC based on MRI-T2* is an effective and non-invasive means for the assessment of liver iron load in patients with long-term transfusion.

INTRODUCTION

Coronary artery bypass grafting (CABG) re-establishes a vascular channel between the proximal and distal end of coronary artery stenosis, allowing blood to bypass the stenosis site to the distal end, thereby improving the blood flow of the heart and reducing the probability of myocardial infarction, restoring hibernating myocardium and inhibiting myocardial function, delaying myocardial infarction remodeling and improving cardiac function and quality of life ⁽¹⁾. CABG is currently one of the main means for coronary artery stenosis therapy, and is also the most effective treatment for coronary heart disease ⁽²⁾. However, some patients will suffer from myocardial ischemia symptoms again due to bridge stenosis and occlusion after surgery ⁽³⁾. With the extension of operation time and the accumulation of cases, further interventional therapy and secondary CABG are also inevitable problems in cardiac surgery ⁽⁴⁾. Therefore, systematic postoperative follow-up study is of great significance for secondary treatment. The patency of the bridging vessels after surgery is the key to the success for the operation and also the major concern of clinicians ⁽⁵⁾. How to evaluate the patency of the bridging vessels has become an

important part of the postoperative follow-up.

In recent years, electron beam computed tomography (EBCT), multi-slice spiral CT (MSCT), magnetic resonance imaging (MRI) and other non-invasive methods for diagnosis have been applied, which provides more options for postoperative follow-up of CABG ⁽⁶⁻⁸⁾. Among them, MSCT angiography is most widely used in clinic ⁽⁹⁾. Its powerful imaging treatment means can clearly display the coronary artery, bridging vessel and the proximal and distal anastomosis of bridging vessel from multiple perspectives, and distinguish the relationship between the titanium clamp clamping the lateral branch of mammalian artery and the normal vessel wall through rotation ⁽¹⁰⁾. Moreover, the bridging vessel is less affected by cardiac beating. Therefore, the display of bridging vessels using MSCT is better than that of its connected own coronary arteries, but its temporal resolution is still limited, and its imaging speed is challenged in patients with rapid heart rate and arrhythmia ⁽¹¹⁾. With the clinical application of dual-source CT at the end of 2005, the time resolution, and scanning speed are further improved, which solves the problem of breath-holding time of patients, reduces the influence of respiratory motion artifact on image quality, and is

conducive to clearly displaying the walking condition of bridging vessels, especially to displaying left internal mammary artery bridge with large scanning range, long breath-holding time and long and tortuous path⁽¹²⁾. In addition, the time resolution of dual-source CT is less than 100 ms (83 ms), and the heart (rate) rule of patients is no longer strictly required⁽¹³⁾. For example, for patients with high heart rate, images with good quality can be obtained without taking drugs to reduce heart rate, thus expanding the scope of coronary artery imaging and truly achieving total heart rate scanning, which makes the test available to more patients and avoids the risks associated with taking beta-blockers, reduces the waiting time of patient, and lowers hospitals manpower costs⁽¹⁴⁾. Thereby, dual-source CT attracts increasing attention in the diagnosis of bridging vascular diseases, which is conducive to the early and correct diagnosis of bridging vascular diseases and guidance for further clinical treatment⁽¹⁵⁾.

In this research, we aimed to use dual-source CT imaging to assess cardiovascular function after coronary artery bypass grafting, which may provide evidence for the application of dual-source CT as an effective, safe and reliable approach in the diagnosis and examination of patients after CABG.

MATERIALS AND METHODS

General data

We retrospectively analyzed the medical records of 60 patients with coronary artery bypass grafting who received double-source CT cardiovascular imaging examination in our hospital from August 2021 to October 2022. Totally 35 males and 25 females were included, with an average age of 62.58 ± 6.74 years (ranged from 43 to 78 years). Patients with renal insufficiency and severe arrhythmia were excluded, and dual-source CT cardiovascular imaging was performed, followed by coronary angiography within 2 weeks.

Examination methods

The inspection equipment was Siemens second generation dual-source CT (Siemens Health-care, Germany). Patients received strict breathing training before the scan to learn to hold their breath during the whole scan. Nitroglycerin (0.5 mg, Nippon Kayaku, Tokyo, Japan) was administered sublingual 5 min before the scan. The scanning range was 2 cm from the thoracic entrance to the subdiaphragmatic surface of the heart. A double-barrel high-pressure syringe (Ulrich Medical, Germany) was used, and 60-90 ml iopromide (Ultravist, Schering, Berlin, Germany) was administrated at a rate of 5 ml/sec. After completion, 40-50 ml of normal saline was administrated via injection at 5 ml/sec. Bolus tracking technology (Smart Prep; GE Medical

Systems, USA) is adopted to monitor the enhancement process of ascending aorta. When the CT value reached 100 Hu, the scan was triggered. Scanning parameters were as follows: collimation in 0.6 mm, frame rotation time of 280 ms, tube voltage of 120 KV, tube current of 280-320 mAs. The patient was asked to complete the scan with one breath hold after normal inhalation. The data of optimal systolic and diastolic periods were reconstructed using a prospective electrocardio-gated adaptive sequential scan. When the image quality was not satisfactory, any phase reconstruction could be carried out for the best image quality. The image was transmitted to the post-processing workstation (Siemens, Germany) and processed by the post-processing technology such as maximum density projection (MIP), surface reconstruction (CPR) and volume reconstruction (VR) using the Circulation software (Siemens, Germany), and the cardiac function index including LV-EF, LV-EDV and LV-ESV was also evaluated.

Coronary angiography (CAG): Philips digital angiography machine (Philips, Amsterdam, the Netherlands) was selected for examination, radial artery puncture and irradiation examination of both left and right coronary arteries.

Criteria

Two clinically experienced physicians conducted double-blind evaluation, including the bridging vessel number and the narrowing, occlusion and patency of bridging vessels. Grade A indicated that the bridging vessels were completely unobstructed without stenosis or lumen stenosis was less than 50%. Grade B indicated a bridge stenosis of more than 50% without complete occlusion. Grade 0 indicated complete occlusion of the bridging vessels. The formula for calculating left ventricular ejection fraction before and after coronary artery bypass grafting was $LV-EDV - LV-ESV / LV-EDV \times 100\%$. In addition, the change rate of cardiac function after coronary artery bypass grafting was calculated as $(\text{postoperative LV-EF} - \text{preoperative LV-EF}) / \text{preoperative LV-EF} \times 100\%$.

Statistical analysis

Results were analyzed with SPSS 19.0 statistical software (IBM Corporation, USA). Measurement data were subject to t test and counting data were analyzed using χ^2 test. It was regarded as statistically significant when $P < 0.05$.

RESULTS

Dual-source CT results

In this examination, the display rate of bridge vessels by dual-source CT cardiovascular imaging reached 100%. Totally 73 bridging vessels were detected, including 31 internal mammary artery bridges and 42 great saphenous vein bridges. The

comparison showed that there was a statistically significant difference in the patency rate between the two types of bridges ($P < 0.05$, table 1).

Table 1. Comparisons of patency rate between internal mammary artery bridge and great saphenous vein bridge.

Bridge vessels	Branches	Lesion rate	Patency rate
Internal mammary artery bridges	31	3	28 (90.32%)
Great saphenous vein bridges	42	12	30 (71.43%)
χ^2	3.90		
P	<0.05		

Effect of bridge vessels by dual-source CT

With CAG examination as the “gold standard,” dual-source CT examination had a sensitivity of 96.67% (58/60) and specificity of 100.00% (13/13), which was displayed in table 2.

Table 2. Results of dual-source CT cardiovascular imaging and CAG.

Dual-source CT cardiovascular imaging	CAG		Total
	Bridging artery lesion	Bridging artery patency	
Bridging artery lesion	58	0	58
Bridging artery patency	2	13	15
Total	60	13	73

CT, computed tomography; CAG, coronary angiography;

Cardiac function index before and after bypass surgery

As displayed in figure 1, the LV-EDV and LV-ESV levels were declined, and LV-EF was elevated after surgery ($P < 0.05$). Figure 2 showed an example of a patient with stenosis and reduced lumen diameter at the main coronary artery before surgery and patent vein bridges after surgery, which indicated the improved cardiac function after bypass surgery.

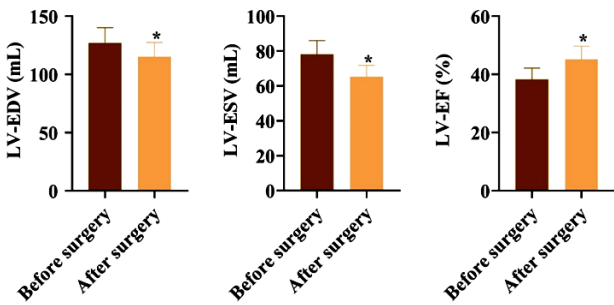


Figure 1. Changes of LV-EDV, LV-ESV and LV-EF levels before and after bypass surgery. * $P < 0.05$. LV-EDV, left ventricular end-diastolic volume; LV-ESV, left ventricular end-systolic volume; LV-EF, left ventricular ejection fraction.

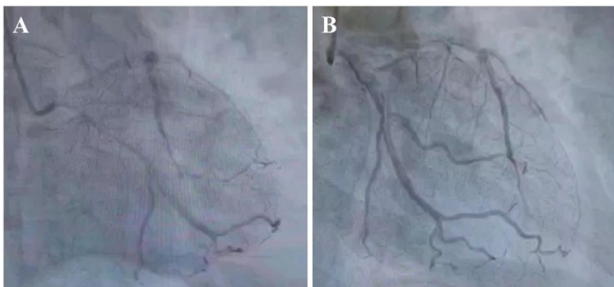


Figure 2. Representative CT images of patients of a patient (A) before and (B) after bypass surgery.

DISCUSSION

Studies have shown that bridging vessel occlusion or stenosis is a common complication of CABG, which is significantly associated with the prognosis of patients ⁽¹⁶⁾. In our work, we revealed that the patency rate of internal mammary artery bridge was significantly different from that of great saphenous vein bridge, which suggested that venous bridge lesions are common after CABG, possibly induced by the absorption of monocytes after endothelial cell injury and their gradual migration to phagocytic and oxidized lipoproteins under the inner skin, thus forming foam cells, leading to the proliferation of venous bridge vessels or the formation of atherosclerotic plaques. In addition, underlying diseases in some patients may also lead to postoperative bridge stenosis and occlusion. Therefore, timely detection of bridge vessel stenosis and occlusion after coronary artery bypass grafting is critical for the guidance of clinical therapy.

CAG is an effective means for the diagnosis of bridge stenosis and occlusion, and serves as the gold standard in examination ⁽¹⁷⁾. However, this inspection method is relatively difficult to operate, and has a certain degree of trauma, which limits the application in clinic. With the advancement of CT technology, CT has been widely used in clinical practice ⁽¹⁸⁾. In particular, the time resolution is relatively high, which can reach 83 ms, so as to better collect and reconstruct single sector data, greatly improve the image clarity, and provide help for clinical diagnosis ⁽¹⁹⁾. Dual-source CT is even more effective than traditional coronary angiography in the detection of bridge occlusion, with high application value ⁽²⁰⁾. The results of this study show that the display rate of the bridge vessels by dual-source CT cardiovascular imaging was up to 100%, which fully indicated the feasibility and effectiveness of the clinical application of dual-source CT cardiovascular imaging, especially in the identification and diagnosis of internal mammary artery bridge and great saphenous vein bridge to effectively improve the accuracy of judgment of doctors. In the clinical application of dual-source CT cardiovascular imaging, the image quality is relatively less affected by the heart rate, and the overall scan speed is relatively fast, with low radiation dose ⁽²¹⁾. In addition, dual-source CT cardiovascular imaging is a non-invasive examination, and the examination itself will not cause adverse effects on patients ⁽²²⁾. Our study identified the high diagnostic value of dual-source CT, which showed 96.67% sensitivity and 100.00% specificity. Therefore, dual-source CT cardiovascular imaging can be used to observe the lesions and patency of bridging vessels with high sensitivity and specificity. Related clinical studies have also shown that dual-source CT cardiovascular imaging has unique advantages in the diagnosis of bridge disease,

especially in the follow up of coronary artery bypass surgery⁽²³⁾.

Besides, it has been reported that the degree of coronary artery stenosis is related to left ventricular function⁽²⁴⁾. The determination of left ventricular function is crucially linked with the diagnosis, treatment, and prognosis of ischemic heart disease⁽²⁵⁾. LV-EDV, LV-ESV, stroke output and LV-EF are commonly used indicators of pumping function, which can provide valuable diagnostic information for clinic⁽²⁶⁾. Notably, studies have shown that dual-source is applied to calculate left ventricular volume and ejection fraction to evaluate the sensitivity and specificity of cardiac function and coronary artery stenosis up to 97.4% and 97.8%, respectively⁽²⁷⁾.

In this work, the differences of LV-EDV, LV-ESV and LV-EF after bypass surgery were statistically significant possibly because bypass surgery changes the ischemic myocardium from a state of low blood flow to a state of normal or nearly normal through revasodilation, improves myocardium systolic and diastolic functions and thus changes the geometry of the heart and affects end-systolic and end-diastolic volume⁽²⁸⁾.

In conclusion, the dual-source CT cardiovascular imaging is of high diagnostic value to assess the cardiac function, vascular patency rate and lesions after coronary artery bypass grafting. As a safe and reliable examination method, the value of it is underlined in clinical practice, which is worth popularizing and applying.

ACKNOWLEDGMENT

None.

Funding: None.

Conflicts of interests: The authors declare no conflicts of interest in this study.

Ethical consideration: This study was approved by the Ethics Committee of the Affiliated Hospital of Chengdu University (approval number: SC2021-[L] 014A, June, 2021).

Author contribution: Qijun Chen conceived the study, conducted clinical data collection and analysis and wrote the draft manuscript. Chunwei Zhang conceived the study, reviewed and revised the manuscript. Both authors approved the final version of the manuscript.

REFERENCES

1. Taggart DP (2014) Contemporary coronary artery bypass grafting. *Front Med*, **8**(4): 395-8.
2. Arsalan M, Mack MJ (2016) Coronary Artery Bypass Grafting Is Currently Underutilized. *Circulation*, **133**(10): 1036-45.
3. Bildari P, fakhe M, Abdollahpour M A, Boroumand N (2020) Comparison of Perfectionism and negative affectability in the patients with coronary artery disease and healthy individuals. *SJMSHM*, **2**(2): 6-14.
4. Gaudino M, Benedetto U, Fremes S, et al. (2020) Association of radial artery graft vs saphenous vein graft with long-term cardiovascular outcomes among patients undergoing coronary artery bypass grafting: A systematic review and meta-analysis. *JAMA*, **324**(2): 179-87.
5. Cundiff DK (2002) Coronary artery bypass grafting (CABG): reassessing efficacy, safety, and cost. *Med Gen Med*, **4**(2): 7.
6. Dewey M, Lembcke A, Enzweiler C, et al. (2004) Isotropic half-millimeter angiography of coronary artery bypass grafts with 16-slice computed tomography. *Ann Thorac Surg*, **77**(3): 800-4.
7. Arian F, Amini M, Mostafaei S, et al. (2022) Myocardial Function Prediction After Coronary Artery Bypass Grafting Using MRI Radiomic Features and Machine Learning Algorithms. *J Digit Imaging*, **35**(6): 1708-18.
8. Kulkarni S, Rumberger JA, Jha S (2021) Electron Beam CT: A Historical Review. *AJR Am J Roentgenol*, **216**(5): 1222-8.
9. Bedi HS, Gill JA, Bakshi SS (2008) Can we perform coronary artery bypass grafting on the basis of computed tomographic angiography alone? A comparison with conventional coronary angiography. *Eur J Cardiothorac Surg*, **33**(4): 633-8.
10. Malhotra R, Mishra M, Khurana P, et al. (2007) Coronary artery bypass grafts assessment at one year by noninvasive multislice computed tomography and invasive coronary angiography. *Innovations (Phila)*, **2**(3): 116-20.
11. Burgstahler C, Beck T, Kuettner A, et al. (2006) Non-invasive evaluation of coronary artery bypass grafts using 16-row multi-slice computed tomography with 188 ms temporal resolution. *Int J Cardiol*, **106**(2): 244-9.
12. Schmoe J, Dirrichs T, Fehrenbacher K, et al. (2020) Virtual Monoenergetic Images (VMI+) in Dual-Source Dual-Energy CT Venography (DSDE-CTV) of the Lower Extremity Prior to Coronary Artery Bypass Graft (CABG): A Feasibility Study. *Acad Radiol*, **27**(9): 1249-54.
13. Lee SK, Jung JI, Ko JM, et al. (2014) Image quality and radiation exposure of coronary CT angiography in patients after coronary artery bypass graft surgery: influence of imaging direction with 64-slice dual-source CT. *J Cardiovasc Comput Tomogr*, **8**(2): 124-30.
14. Adler G, Meille L, Rohnean A, et al. (2010) Robustness of end-systolic reconstructions in coronary dual-source CT angiography for high heart rate patients. *Eur Radiol*, **20**(5): 1118-23.
15. Yun H, Zeng MS, Yang S, et al. (2011) Congenital coronary artery fistulas: dual-source CT findings from consecutive 6,624 patients with suspected or confirmed coronary artery disease. *Chin Med J (Engl)*, **124**(24): 4172-7.
16. Hwang HY, Paeng JC, Kang J, et al. (2021) Relation between functional coronary artery stenosis and graft occlusion after coronary artery bypass grafting. *J Thorac Cardiovasc Surg*, **161**(3): 1010-8.e1.
17. Li M, Liu S, Zhang J, et al. (2015) Coronary competitive reverse flow: Imaging findings at CT angiography and correlation with invasive coronary angiography. *J Cardiovasc Comput Tomogr*, **9**(3): 202-8.
18. Schmidt B, Flohr T (2020) Principles and applications of dual source CT. *Phys Med*, **79**: 36-46.
19. Schicchi N, Fogante M, Esposto Pirani P, et al. (2019) Third-generation dual-source dual-energy CT in pediatric congenital heart disease patients: state-of-the-art. *Radiol Med*, **124**(12): 1238-52.
20. Singh S, Singh N, Gulati GS, et al. (2016) Dual-Source Computed Tomography for Chronic Total Occlusion of Coronary Arteries. *Catheter Cardiovasc Interv*, **88**(4): E117-e25.
21. Booi R, Dijkshoorn ML, van Straten M, et al. (2016) Cardiovascular imaging in pediatric patients using dual source CT. *J Cardiovasc Comput Tomogr*, **10**(1): 13-21.
22. Miller JC, Abbata S, Mamuya WS, et al. (2009) Dual-source CT for cardiac imaging. *J Am Coll Radiol*, **6**(1): 65-8.
23. Jin GY, Jeong SK, Lee SR, et al. (2009) Screening strategies for the diagnosis of coronary artery stenosis in patients with cerebral infarction using dual-source spiral CT. *J Neurol Sci*, **284**(1-2): 129-34.
24. Ostojic M, Stanetic BM, Kovacevic-Preradovic T, et al. (2019) Coronary stenosis and left ventricular function - Major prognostic factors in patients with ischemic heart disease: Has something changed in the era of "precision medicine"? *Int J Cardiol*, **278**: 36-7.
25. Perera D, Clayton T, O'Kane PD, et al. (2022) Percutaneous Revascularization for Ischemic Left Ventricular Dysfunction. *N Engl J Med*, **387**(15): 1351-60.
26. Hart JP, Cabreriza SE, Gallup CG, et al. (2002) Validation of left ventricular end-diastolic volume from stroke volume and ejection fraction. *Asaio j*, **48**(6): 654-7.
27. Xu Y, Tang L, Zhu X, et al. (2010) Comparison of dual-source CT coronary angiography and conventional coronary angiography for detecting coronary artery disease. *Int J Cardiovasc Imaging*, **26**(1): 75-81.
28. Kang DK, Lim SH, Park JS, et al. (2020) Clinical utility of early post-operative cardiac multidetector computed tomography after coronary artery bypass grafting. *Sci Rep*, **10**(1): 9186.