

Prognostic value and clinical relevance of tertiary lymphoid structures in non-muscle-invasive bladder cancer

JB. Ji¹, PC. Li^{2*}, TT. Yuan¹, ZK. Qu¹, GX. Song¹, ML. Bao¹, XD. Liang¹, B. Jiang¹, XL. Yin¹, YY. Wang¹, H. Ji¹

¹Department of Urology, Yancheng Third People's Hospital (The Yancheng School of Clinical Medicine of Nanjing Medical University), Yancheng, Jiangsu 224001, China.

²Department of Urology, The First Affiliated Hospital with Nanjing Medical University, Nanjing, Jiangsu 210029, China

ABSTRACT

► Original article

***Corresponding author:**

Pengchao Li, Ph.D.,

E-mail:

lipengchao_edu@outlook.com

Received: October 2023

Final revised: November 2023

Accepted: November 2023

Int. J. Radiat. Res., April 2024;
22(2): 277-282

DOI: 10.61186/ijrr.22.2.277

Keywords: Tertiary lymphoid structure, non-muscle-invasive bladder cancer, clinical relevance.

Background: The presence of tertiary lymphoid structures (TLS) is related with good prognosis of various cancers including bladder cancer. The majority of bladder tumors are identified as non-muscle-invasive bladder cancer (NMIBC) when they are discovered in their early stages. We aimed to evaluate the prognostic value and clinical relevance of TLS in NMIBC. **Materials and Methods:** This cohort included 130 NMIBC samples, with 39 (30%) having TLS, as confirmed by hematoxylin and eosin and immunohistochemistry staining. The chi-square test was utilized to examine the relationship between TLS and the biomarkers and clinicopathologic characteristics of NMIBC. **Results:** It was found that TLS has significant association with pT stage, Ki-67 expression, and COX-2 expression. Using Kaplan-Meier analysis and Gehan-Breslow-Wilcoxon test, we found that the presence of TLS is associated with longer recurrence-free survival and overall survival of NMIBC patients. Moreover, we used bioinformatics to analyze the association of TLS marker L1CAM and bladder cancer. L1CAM is downregulated in bladder cancer, linked to an advanced stage of the disease, and indicates a poorer prognosis for those who have bladder cancer. In bladder cancer, there is a positive correlation between its expression and B cell infiltration. We also indicated that NMIBC with TLS have a higher level of TLS than that without TLS. **Conclusion:** To conclude, the presence of TLS is an important favorable prognostic indicator in NMIBC. A further understanding on TLS can provide new insights to improve immunotherapy for bladder cancer.

INTRODUCTION

According to the cancer statistics in 2022 by American Cancer Society, there are estimated 106,180 new cases of colon cancer, 44,850 new cases of rectum cancer, and 52,580 deaths caused by colon cancer⁽¹⁾. The largest morbidity of colorectal cancer is seen in North America, Europe, and Western Asia, and it is more common in resource-rich and industrialized nations⁽²⁾. Approximately 75% of bladder tumors are discovered in their early stages and are classified as non-muscle-invasive bladder cancer (NMIBC). This categorization correlates to clinical tumor stages Tis, Ta, and T1 according to the 8th American Joint Committee on Cancer and the Union for International Cancer Control⁽³⁾. NMIBC is limited to the mucosal layer or involves invasion of the bladder wall's submucosal layer (lamina propria), but it does not entail invasion of the detrusor muscle beneath it (muscularis propria). Even with endoscopic surgery, NMIBC patients face a significant recurrence rate while having a favorable prognosis. Muscle-invasive bladder cancer (MIBC), which is linked to increased mortality rates and corresponds

to T2 or higher stages, occurs in certain people. Bladder cancer has one of the highest predicted death rates of any disease since it requires constant observation, has a high recurrence and progression rate, and necessitates several different forms of treatment^(4,5).

The current treatment methods for NMIBC include transurethral resection, single instillation of chemotherapy post-transurethral resection of the bladder tumor, adjuvant intravesical chemotherapy, and adjuvant intravesical Bacillus Calmette-Guérin⁽⁶⁾. Although these methods bring benefits to patients with NMIBC, they also seriously affect the quality of life of patients. Thus, it is very important to control the recurrence, progression, and metastasis of patients with NMIBC.

Tertiary lymphoid structures (TLS) are ectopic lymphoid tissues and resemble secondary lymphoid organs⁽⁷⁾. They can be seen in the tumor microenvironment of some solid malignancies, such as malignancies of the kidney⁽⁸⁾, endometrium⁽⁹⁾, melanoma⁽¹⁰⁾, lung⁽¹¹⁾, colon⁽¹²⁾, and breast^(13,14). In TLS, T and B cells are dispersed over distinct areas. T cells are primarily found in the region with mature

dendritic cells and strong endothelial venules, whereas B cells are primarily found in the germinal center and a little network of follicular dendritic cells. TLS are fundamental for antitumor immune responses by recruiting and activating tumor infiltrating lymphocytes to activate immune response (15). TLS is associated with antitumor immune responses and predicts a favorable prognosis in urothelial bladder cancer (16). In this study, we analyzed the link of TLS with the clinicopathologic features and cancer markers in NMIBC. The relationship between TLS and the survival of NMIBC patients was also evaluated, which may offer a new insight into the role of TLS in NMIBC. No previous studies have linked TLS and NMIBC. This study builds on previous studies and found that the presence of TLS is an important favorable prognostic indicator in NMIBC. A better understanding of TLS could provide new ways to improve immunotherapy for bladder cancer.

MATERIALS AND METHODS

Participants

This single-center study involved 130 patients with NMIBC at The First Affiliated Hospital with Nanjing Medical University. All participants are Chinese. NMIBC is confirmed by histopathological results of specimens from transurethral resection. Written informed consent for participation in this study has been obtained from each patient. The study protocol has gained approval from the review boards of The First Affiliated Hospital with Nanjing Medical University. An online single-sample classifier was used to categorize the NMIBCs into UROMOL subtypes 1, 2a, 2b, and 3. (17).

Eligibility criteria

The inclusion criteria are included as follows: 1. Patients sign the written informed consent; 2. Patients are aged between 20–90 years old; 3. Patients are diagnosed with NMIBC and are treated with transurethral resection of bladder tumor.

Patients with the following conditions are excluded: 1. Willing to receive radical cystectomy; 2. other malignancies; 3. A history of other malignancies within the last 5 years; 4. acute inflammatory diseases; 5. Severe hepatic dysfunction or (and) renal dysfunction; 6. do not sign the informed consent; 7. Deemed unsuitable as participants in the investigation by the attending doctor.

RNA extraction and quantitative real-time PCR (qRT-PCR)

Total RNA was isolated from NMIBC tissues using TRIzol reagent (Beyotime, Shanghai, China) based on the manufacturer's protocols. cDNA was synthesized using a SuperScript IV CellsDirect cDNA kit (ThermoFisher Scientific, USA) and qRT-PCR was

performed using StepOne Plus Real-Time PCR system (Applied Biosystems, USA). L1CAM expression was analyzed by comparing Ct values with GAPDH as an internal control. PCR was run on three samples with three technical repeats for each sample. L1CAM, forward primer: 5'-CGAGGAATATGAAGGACACCA-3', reverse primer: 5'-AGGCTGATGTCATCTGTGG-3'. GAPDH, forward primer: 5'-TCAAGATCATCAGCAATGCC-3', reverse primer: 5'-CGATACCAAAGTTGTCATGGA-3'.

Histology and immunohistochemistry

Hematoxylin and Eosin (H&E) staining of the fixed paraffin-embedded sections of NMIBC specimens was observed with Aperio ScanScope software (Leica Biosystems, Germany) and examined by two independent pathologists to confirm TLS. Multicolor immunohistochemistry (IHC) was performed on 5 µm sections as previously described (18, 19) on the Intellipath FLX Automated Staining system using CD3, CD23, CD20, Ki-67, Calretinin, COX-2, Cadherin-17, EGFR, and VEGF antibodies. Stained slices were imaged multispectrally with the PerkinElmer Vectra system. The detailed information for the antibodies is included in table 1. Finally, the images were taken using a Nikon microscope (Nikon, Japan).

Table 1. Antibodies information.

Markers	Company	Catalogue number	Clone	Dilution	Antigen retrieval
CD3	Abcam	ab16669	SP7	1/150	Citrate buffer pH 6
CD23	Abcam	ab92495	EPR3617	1/400	Pressure cooker method
CD20	Abcam	ab78237	EP459Y	1/250	EDTA buffer pH 9.0
Ki-67	Abcam	ab16667	SP6	1/200	Citrate buffer pH 6
Calretinin	Abcam	ab92341	EP1798	1/4000	Citrate buffer pH 6
COX-2	Abcam	ab179800	EPR12012	1/200	EDTA buffer pH 9.0
Cadherin-17	R&D Systems	MAB1032	141713	2 µg/mL	EDTA buffer pH 9.0
EGFR	Abcam	ab52894	EP38Y	1/100	EDTA buffer pH 9.0
VEGF	Abcam	ab32152	Y103	1/250	Citrate buffer pH 6

Statistical analysis

Chi-square analysis was applied to evaluate the association of TLS with clinicopathologic features and biomarker expression in NMIBC. The difference of L1CAM expression in NMIBC in the presence or absence of TLS was analyzed by student's t test. Survival data were evaluated with Kaplan-Meier analysis using Gehan-Breslow-Wilcoxon test. Hazard ratio (HR) and 95% confidential incidence (CI) were determined using the log rank test. Statistical significance was established at the condition of $p < 0.05$.

RESULTS

Expression of TLS marker L1CAM in bladder cancer

L1CAM is a marker for mature TLS (9). L1CAM expression has an obvious upregulation in bladder cancer tissues compared with that in normal tissues (figure 1a). Its expression is higher in more advanced bladder cancer tissues (figure 1b). Overall survival is

lower in patients with high L1CAM expression than in those with low expression (figure 1c). Figure 1D showed that the degree of B cell infiltration in bladder cancer is significantly positively correlated with L1CAM expression. L1CAM expression was higher in NMIBC tissues in the presence of TLS (n = 39) than in the absence of TLS (n = 91) (figure 1E).

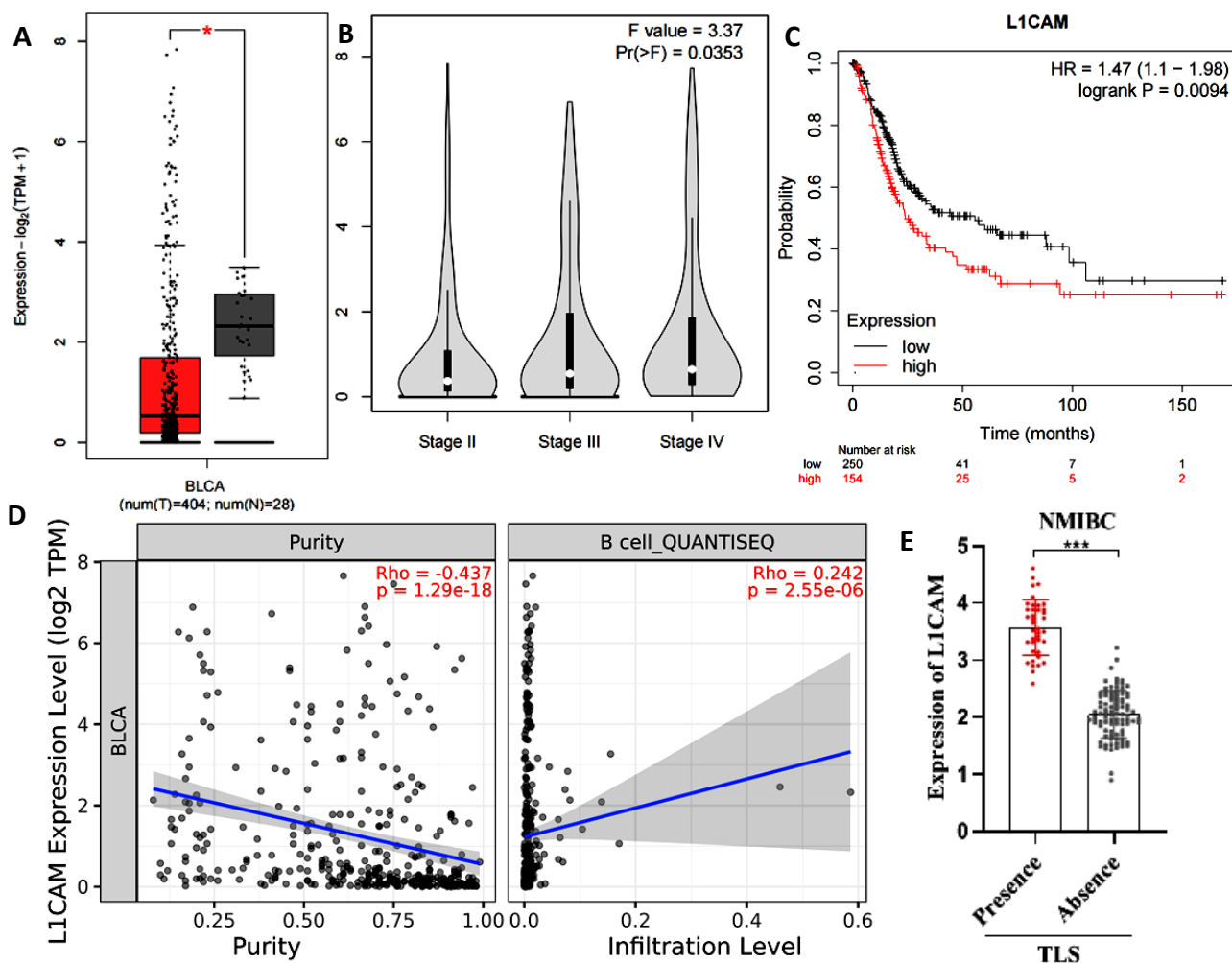


Figure 1. Expression of TLS marker L1CAM in bladder cancer. **A.** Expression of L1CAM in 404 bladder cancer tissues and 28 normal tissues. Data are obtained from GEPIA database. **B.** Expression of L1CAM in bladder cancer tissues of different stages. Data are obtained from GEPIA database. **C.** Association of L1CAM expression with overall survival of bladder cancer patients. Data are obtained from Kaplan-Meier Plotter online database. **D.** Correlation between L1CAM expression with B cell purity and infiltration level in bladder cancer. Data are obtained from TIMER2.0 online database. **E.** Expression of L1CAM in NMIBC tissues in the presence or absence of TLS was assessed by PCR analysis. *p<0.01, ***p<0.001.

Figure 1 Expression of TLS marker L1CAM in bladder cancer

A. Expression of L1CAM in 404 bladder cancer tissues and 28 normal tissues. Data are obtained from GEPIA database. B. Expression of L1CAM in bladder cancer tissues of different stages. Data are obtained from GEPIA database. C. Association of L1CAM expression with overall survival of bladder cancer patients. Data are obtained from Kaplan-Meier Plotter online database. D. Correlation between L1CAM expression with B cell purity and infiltration level in bladder cancer. Data are obtained from

TIMER2.0 online database. E. Expression of L1CAM in NMIBC tissues in the presence or absence of TLS was assessed by PCR analysis. *p<0.01, ***p<0.001.

Association of TLS with clinicopathologic features and biomarkers of NMIBC

Table 2 displays the correlation between TLS and the clinicopathologic characteristics of NMIBC. TLS has no significant association with gender (p=0.8182), age (p=0.6104), subtypes (p=0.8881), multiplicity (p=0.9355), and growth pattern (p=0.1835) of NMIBC. There are 48, 53, and 29 cases

of NMIBC of Tis, T1, and Ta stages, respectively. For Tis NMIBC, there are 11 cases with TLS and 37 cases without TLS. For T1 NMIBC, there are 12 cases with TLS and 41 cases without TLS. For Ta NMIBC, there are 16 cases with TLS and 13 cases without TLS. TLS has significant association with the pT stage of NMIBC, with the p value of 0.0036. We further evaluated the association of TLS with the levels of biomarkers of NMIBC including Ki-67, Calretinin, COX-2, Cadherin-17, EGFR, and VEGF (table 3). TLS has no significant association with Calretinin ($p=0.2057$), EGFR ($p=0.9689$), and VEGF ($p=0.3777$). There was a trend of association with Cadherin-17 ($p=0.0813$). TLS has significant association with Ki-67 ($p=0.0006$) and COX-2 ($p=0.0374$).

Table 2. Correlation of TLS with clinicopathological features in NMIBC.

Features	TLS presence (n = 39)	TLS absence (n = 91)	P value
Gender			
Male (n = 68)	21	47	0.8182
Female (n = 62)	18	44	
Age			
<60 (n = 79)	25	54	0.6104
≥60 (n = 51)	14	37	
Subtypes			
1 (n = 27)	9	18	0.8881
2a (n = 43)	11	32	
2b (n = 51)	16	35	
3 (n = 9)	3	6	
pT stage			
Tis (n = 48)	11	37	0.0036*
T1 (n = 53)	12	41	
Ta (n = 29)	16	13	
Multiplicity			
Unifocal tumor (n = 86)	26	60	0.9355
Multifocal tumor (n=44)	13	31	
Growth pattern			
Papillary (n = 112)	36	76	0.1835
Solid (n = 18)	3	15	

* indicate statistical significance. TLS: tertiary lymphoid structures; NMIBC: non-muscle-invasive bladder cancer.

Table 3. Correlation of TLS with biomarkers in NMIBC.

Biomarkers	TLS presence (n = 39)	TLS absence (n = 91)	P value
Ki-67			
Low (n = 48)	23	25	0.0006*
High (n =82)	16	66	
Calretinin			
Low (n = 61)	15	46	0.2057
High (n = 69)	24	45	
COX-2			
Low (n = 84)	20	64	0.0374*
High (n = 46)	19	27	
Cadherin-17			
Low (n = 75)	18	57	0.0813
High (n = 55)	21	34	
EGFR			
Low (n = 53)	16	37	0.9689
High (n = 77)	23	54	
VEGF			
Low (n = 69)	23	46	0.3777
High (n = 61)	16	45	

* indicate statistical significance. TLS: tertiary lymphoid structures; NMIBC: non-muscle-invasive bladder cancer.

Prognostic value of TLS in NMIBC

There were follow-up data available for 130 NMIBC patients, with a mean follow-up time of 55.37 months and follow-up times ranging from 2 months to 114 months. Forty cases died during follow up, with 6 cases in the group with the presence of TLS and 31 cases with the absence of TLS. Forty-four cases had relapse, with 13 cases in the group with the presence of TLS and 31 cases with the absence of TLS. NMIBC patients with the presence of TLS have longer recurrence-free survival ($p=0.0209$) (figure 2A) and overall survival ($p=0.0101$) (figure 2B) than patients with the absence of TLS.

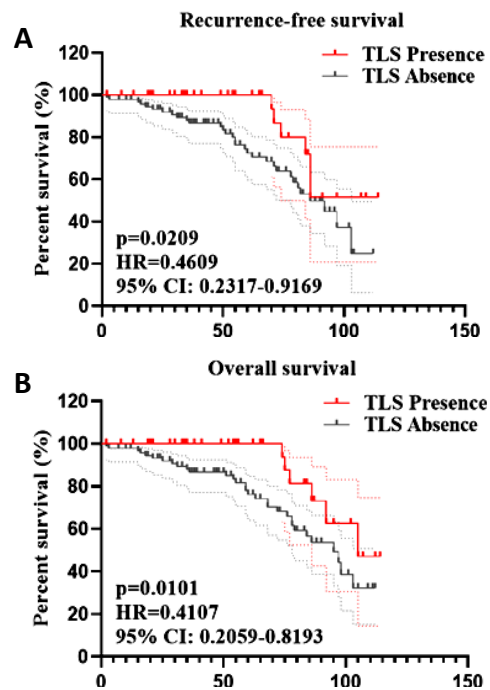


Figure 2. Kaplan-Meier analysis on recurrence-free survival and overall survival of NMIBC patients according to TLS status. **A.** TLS presence is associated with NMIBC patients' survival without recurrence. **B.** Relationship between TLS presence and NMIBC patients' overall survival.

DISCUSSION

TLS have close association with survival and immunotherapy response in MIBC⁽²⁰⁾. TLS score is a useful prognosis predictor for patients with bladder cancer regardless of tumor mutation burden. Low TLS score is associated with better prognosis⁽²¹⁾. Mature TLS are more prevalent in aggressive high grade MIBC as compared to low grade NMIBC⁽¹⁶⁾. No previous studies have linked TLS and NMIBC. In our study, we now confirm the presence of TLS (n=39) in 130 NMIBC cases by H&E and IHC staining and demonstrate that presence of TLS is a favorable prognostic factor for NMIBC. We also analyzed the association of TLS and the clinicopathologic features of NMIBC. TLS has no significant association with gender, age, subtypes, multiplicity, and growth

pattern of NMIBC. Interestingly, there is a significant association of TLS and pT stage. The major of NMIBC patients at Tis or T1 stage are at the absence of TLS.

A previous study used immunohistochemistry and co-immunofluorescence and revealed L1CAM expression in mature TLS, independent of L1CAM expression in endometrial cancer, indicating L1CAM as a marker for well-formed TLS⁽⁹⁾. Chemotherapy-treated urothelial carcinoma shows abundant L1CAM clonal mutations⁽²²⁾. The CE7 epitope of L1CAM on various malignancies including bladder cancer can be targeted by CE7-specific chimeric antigen receptor-redirectioned T cells, which makes it a promising target for adoptive immunotherapy⁽²³⁾. We discovered that L1CAM is downregulated in bladder cancer, is related with advanced stage of bladder cancer, and predicts a poor prognosis for bladder cancer patients using internet databases. Surprisingly, L1CAM expression is associated with B cell infiltration in bladder cancer. Furthermore, NMIBC with TLS has a higher level of TLS than NMIBC without TLS.

As a well-known proliferation index, Ki-67 is highly associated with advanced tumor grade and shorter survival time in primary pT1 urothelial bladder cancer⁽²⁴⁾. This investigation revealed a significant correlation between Ki-67 and the presence of TLS in NMIBC. NMIBC patients with TLS display low Ki-67 levels. COX-2 expression is high in bladder cancer cells and functions as a potential molecular target for the detection and treatment of cancer^(25,26). T cells can enhance the oxidative stress of bladder cancer cells by activating COX-2⁽²⁷⁾. In our study, we found that NMIBC patients in the absence of TLS have low COX-2 levels. In addition, there is a trend on the association of Cadherin-17 expression and TLS presence in NMIBC, though not significant. A larger sample size is needed to further validate the association of Cadherin-17 expression and TLS in NMIBC.

A shortcoming of this study is that the sample size is limited. Despite it, we innovatively revealed that TLS is associated with pT stage, Ki-67 expression, and COX-2 expression in NMIBC, and the presence of TLS predicts a favorable prognosis for NMIBC. We also used the TLS marker L1CAM and revealed its expression pattern and diagnostic value. CXCL13 is also a TLS marker and has been associated with better survival for patients with advanced-stage bladder cancer⁽²⁸⁾. It is necessary to explore its role in NMIBC. Furthermore, our future studies will focus on the association of immune cells or lymphoid chemokines and the presence of TLS in NMIBC. Our study can provide direction on formulating antitumor immunity in NMIBC.

CONCLUSION

Herein, we demonstrated that one significant favorable prognostic factor in NMIBC is the existence

of TLS. A deeper comprehension of TLS may yield fresh perspectives on enhancing immunotherapy for bladder cancer. We will focus on the interaction of TLS with immune cells or lymphoid chemokines in NMIBC in the future. Directions for developing antitumor immunity in NMIBC can be obtained from our investigation.

ACKNOWLEDGMENT

None.

Conflicts of interests: No potential conflict of interest was reported by the authors.

Ethical consideration: All patients provided their written, voluntarily informed consent. All procedures were carried out in accordance with the guidelines outlined in the Helsinki Declaration and this study was approved by the Ethics Committee of our institution.

Author contribution: Pengchao Li conceived and designed the experiments. Jianbo Ji, Tiantian Yuan, Zhaokui Qu, Guoxin Song, Meiling Bao and Xiaodong Liang, contributed significantly to the experiments and arranging data. Bo Jiang, Xiangliang, Yin Yiyang Wang, and Hao Ji performed data analyses. Jianbo Ji and Pengchao Li wrote the draft manuscript. Pengchao Li revised the manuscript. All authors read and approved the final manuscript.

REFERENCES

1. Siegel RL, KD Miller, Fuchs HE, Jemal A (2022) Cancer statistics, 2022. *CA Cancer J Clin*, **72**(1): 7-33.
2. Dy GW, Gore JL, Forouzanfar MH, et al. (2017) Global Burden of Urologic Cancers, 1990-2013. *Eur Urol*, **71**(3): 437-446.
3. Amin MB, Greene FL, Edge SB, et al. (2017) The Eighth Edition AJCC Cancer Staging Manual: Continuing to build a bridge from a population-based to a more "personalized" approach to cancer staging. *CA Cancer J Clin*, **67**(2): 93-99.
4. Avritscher EB, Cooksley CD, Grossman HB, et al. (2006) *Clinical model of lifetime cost of treating bladder cancer and associated complications*. *Urology*, **68**(3): 549-53.
5. Kamat AM, Hahn NM, Efstathiou JA, et al. (2016) Bladder cancer. *Lancet*, **388**(10061): 2796-2810.
6. Bhindi B, Kool R, Kulkarni GS, et al. (2021) Canadian Urological Association guideline on the management of non-muscle-invasive bladder cancer - Full-text. *Can Urol Assoc J*, **15**(8): E424-e460.
7. Hiraoka N, Ino Y, Yamazaki-Itoh R (2016) Tertiary lymphoid organs in cancer tissues. *Front Immunol*, **7**: 244.
8. Meylan M, Petitprez F, Becht E, et al. (2022) Tertiary lymphoid structures generate and propagate anti-tumor antibody-producing plasma cells in renal cell cancer. *Immunity*, **55**(3): 527-541.e5.
9. Horeweg N, Workel HH, Loiero D, et al. (2022) Tertiary lymphoid structures critical for prognosis in endometrial cancer patients. *Nat Commun*, **13**(1): 1373.
10. Cabrera R, Lauss M, Sanna A, et al. (2020) Tertiary lymphoid structures improve immunotherapy and survival in melanoma. *Nature*, **577**(7791): 561-565.
11. Patil NS, BY Nabet Müller S, et al. (2022) Intratumoral plasma cells predict outcomes to PD-L1 blockade in non-small cell lung cancer. *Cancer Cell*, **40**(3): 289-300.e4.
12. Bai Z, Zhou Y, Ye Z, et al. (2021) Tumor-Infiltrating Lymphocytes in Colorectal Cancer: The Fundamental Indication and Application on Immunotherapy. *Front Immunol*, 2021. **12**: p. 808964.
13. Schumacher TN and Thommen DS (2022) Tertiary lymphoid structures in cancer. *Science*, **375**(6576): eabf9419.
14. Wang B, Liu J, Han Y, et al. (2022) The Presence of Tertiary Lymphoid Structures Provides New Insight Into the Clinicopathological

- Features and Prognosis of Patients With Breast Cancer. *Front Immunol*, **13**: p. 868155.
15. Fridman WH, Pagès F, Sautès-Fridman C, Galon J (2012) The immune contexture in human tumours: impact on clinical outcome. *Nat Rev Cancer*, 2012. **12**(4): p. 298-306.
 16. Koti M, Xu AS, Ren KYM, *et al.* (2017) Tertiary Lymphoid Structures Associate with Tumour Stage in Urothelial Bladder Cancer. *Bladder Cancer*, **3**(4): 259-267.
 17. Lindskrog SV, Prip F, Lamy P, *et al.* (2021) An integrated multi-omics analysis identifies prognostic molecular subtypes of non-muscle-invasive bladder cancer. *Nat Commun*, **12**(1): 2301.
 18. Nielsen JS, Sahota RA, Milne K, *et al.* (2012) CD20+ tumor-infiltrating lymphocytes have an atypical CD27- memory phenotype and together with CD8+ T cells promote favorable prognosis in ovarian cancer. *Clin Cancer Res*, **18**(12): p. 3281-92.
 19. Kroeger DR, Milne K, BH Nelson (2016) tumor-infiltrating plasma cells Are associated with tertiary lymphoid structures, cytolytic T-cell responses, and superior prognosis in ovarian cancer. *Clin Cancer Res*, **22**(12): 3005-15.
 20. Zhou L, Xu B, LiuY, Z. Wang (2021) Tertiary lymphoid structure signatures are associated with survival and immunotherapy response in muscle-invasive bladder cancer. *Oncoimmunology*, **10**(1): 1915574.
 21. An Y, Sun JX, Xu MY, *et al.* (2022) Tertiary lymphoid structure patterns aid in identification of tumor microenvironment infiltration and selection of therapeutic agents in bladder cancer. *Front Immunol*, **13**: p. 1049884.
 22. Faltas, BM, Prandi D, Tagawa ST, *et al.*(2016) Clonal evolution of chemotherapy-resistant urothelial carcinoma. *Nat Genet*, **48**(12): 1490-1499.
 23. Hong H, Stastny M, Brown C, *et al.* (2014) Diverse solid tumors expressing a restricted epitope of L1-CAM can be targeted by chimeric antigen receptor redirected T lymphocytes. *J Immunother*, **37**(2): 93-104.
 24. Culpan M, Turan T, Ozkanli SS, *et al.* (2021) Prognostic and clinicopathologic value of ki-67 and profilin 1 immunohistochemical expression in primary pT1 urothelial bladder cancer. *J Cancer Res Ther*, **17**(2): 434-442.
 25. Li D, Zhong S, Zhu Z, *et al.* (2020) LncRNA MAFG-AS1 promotes the progression of bladder cancer by targeting the miR-143-3p/COX-2 axis. *Pathobiology*, **87**(6): 345-355.
 26. Wan GX, Chen P, Yu XJ, *et al.* (2015) Cyclooxygenase-2 polymorphisms and bladder cancer risk: a meta-analysis based on case-control studies. *Int J Clin Exp Med*, **8**(3): 3935-45.
 27. Gakis G (2014) The role of inflammation in bladder cancer. *Adv Exp Med Biol*, **816**: 183-96.
 28. Groeneveld CS, Fontugne J, Cabel L, *et al.*(2021) Tertiary lymphoid structures marker CXCL13 is associated with better survival for patients with advanced-stage bladder cancer treated with immunotherapy. *Eur J Cancer*, **148**: 181-189.