

Analysis of pituitary MRI morphological parameters and changes in 25-hydroxyvitamin D3, free thyroxine, and sex hormone levels in female children with central precocious puberty

Z. Zhang^{1#}, Y. Wei^{1#}, Y. Zhang², J. Wen³, Y. Lin^{1*}

¹Department of Radiology, Hainan Women & Children's Medical Center, Haikou, China

²Department of Neonatology, Hainan Women & Children's Medical Center, Haikou, China

³Department of Clinical Laboratory, Hainan Women & Children's Medical Center, Haikou, China

► Original article

ABSTRACT

*Corresponding author:

Yi Lin, BM.,

E-mail: Linyi88431@163.com

Received: March 2024

Final revised: May 2024

Accepted: May 2024

Int. J. Radiat. Res., October 2024;
22(4): 891-895

DOI: 10.61186/ijrr.22.4.891

Keywords: Central precocious puberty, pituitary MRI, 25-Hydroxyvitamin D3, Free thyroxine, sex hormones, diagnostic imaging.

Contributed equally to this work.

Background: This study aims to investigate the pituitary MRI morphological parameters and alterations in 25-hydroxyvitamin D3 [25-(OH) D3], free thyroxine (FT4), and sex hormone levels in female children with central precocious puberty (CPP) and assess their clinical relevance. **Materials and Methods:** From February 2022 to February 2023, 46 female children with CPP and 46 healthy controls were included. Pituitary MRI morphological parameters, 25-(OH) D3, FT4, and sex hormone levels were compared. Diagnostic values of each parameter were assessed. **Results:** Patients with CPP exhibited higher pituitary height and altered morphology compared to controls, with a higher proportion in grades 4 and 5 ($P < 0.05$). Coronal and sagittal dimensions were increased, while coronal width was decreased in the study group ($P < 0.05$). Levels of E2, LH, FSH, and FT4 were elevated, while 25-(OH) D3 was reduced in CPP patients ($P < 0.05$). Pituitary height, coronal height, and hormone levels showed high diagnostic value for CPP, with AUC values ranging from 0.811 to 0.886. Combined diagnosis using these indicators improved AUC to 0.909. **Conclusion:** In female children with CPP, significant differences exist in pituitary MRI morphological parameters, sex hormones, 25-(OH) D3 and FT4 levels, providing valuable diagnostic insights for CPP.

INTRODUCTION

Sexual maturation typically denotes the onset of secondary sexual characteristics, a natural part of development. Central precocious puberty (CPP) represents an advanced form of this process, where these characteristics manifest significantly earlier than usual. This condition is not merely a variance in developmental timing but can profoundly impact the growth and health of children, potentially leading to metabolic syndrome, cardiovascular diseases, and an increased risk of cancers related to the reproductive system ^(1,2). Traditionally, serum sex hormone levels are utilized to diagnose CPP. However, the reliance on these hormones can result in frequent misdiagnoses or underdiagnoses, particularly in cases where children display isolated breast development without other puberty markers ⁽³⁾.

Beyond sex hormones, thyroid hormones, particularly free thyroxine (FT4), play a crucial role in metabolic processes and development. Despite its significance, research on the utilization of FT4 levels to diagnose CPP, especially in girls, remains sparse ⁽⁴⁾. Similarly, 25-hydroxyvitamin D3 [25-(OH) D3] is

essential for the regulation of mineral absorption and bone formation, implicating potential skeletal development anomalies in CPP cases ⁽⁵⁾. Furthermore, emerging studies indicate potential abnormalities in the hypothalamic-pituitary-gonadal axis in children with CPP, which could manifest as notable changes in pituitary morphology, detectable through imaging techniques ^(6,7).

Magnetic Resonance Imaging (MRI) offers a non-invasive technique with high soft tissue resolution, ideal for observing subtle changes within the hypothalamus and pituitary gland. The clarity and detail provided by MRI make it an invaluable tool in the CPP diagnostic process ^(8,9).

This research aims to delve deeper into the application of pituitary MRI for assessing morphological changes alongside variations in 25-(OH) D3, FT4, and sex hormone levels in female children diagnosed with CPP. The study's novelty lies in its integrative approach, combining detailed MRI scans with comprehensive hormonal profiling to enhance diagnostic accuracy and provide new insights into the underlying mechanisms of CPP. By doing so, it seeks to offer a robust framework for

understanding the complex interplay of hormones and brain structure alterations in precocious puberty, thereby enriching clinical practice with more precise diagnostic tools. The novelty of this study lies in its integrated approach of using both pituitary MRI morphological parameters and hormonal analysis to diagnose central precocious puberty, offering a more comprehensive diagnostic tool.

MATERIALS AND METHODS

General information

This study was conducted from February 2022 to February 2023. Forty-six female children with CPP were selected as the study group, and 46 healthy children undergoing physical examinations in our hospital were selected as the control group in a 1:1 ratio. There were no significant differences in the general characteristics between the two groups ($P > 0.05$, table 1). This study was approved by the Institutional Review Board. Inclusion criteria: 1. Patients in the study group were clinically evaluated and diagnosed with CPP according to the "Diagnosis and Treatment Consensus for CPP" by the Chinese Society of Pediatrics. 2. Age ranged from 6 to 9 years old. 3. Normal intellectual development without cognitive impairment. 4. Informed consent obtained from both the child and their family members. Control group consisted of healthy children undergoing health check-ups in our hospital. Exclusion criteria: 1. Presence of neurological disorders. 2. Presence of other diseases unsuitable for MRI examination. 3. Presence of mental health disorders. 4. Presence of congenital thyroid dysfunction disorders. 5. Peripheral precocious puberty. The study group consisted of 46 female children diagnosed with CPP, with a mean age of 7.45 ± 1.02 years. The control group comprised 46 healthy children, with a mean age of 7.56 ± 1.26 years. This study was approved by the ethics committee of Hainan Women & Children's Medical Center (Approval no. HWC-MC-1302). Signed written informed consents were obtained from the patients and/or guardians.

Table 1. General data comparison.

group	Age (year)	stature (cm)	Body mass (kg)	Bone age (age)	Bone age error (age)
Control group (n=46)	7.56±1.26	125.69±8.11	26.98±6.56	9.55±1.23	1.99±0.87
Study group (n=46)	7.45±1.02	126.26±7.98	26.56±5.89	9.45±1.06	2.00±0.78
t	0.460	-0.340	0.323	0.418	-0.180
P	0.646	0.735	0.747	0.677	0.858

Note: Bone age error: bone age-actual age.

Biochemical detection

Three milliliters of fasting venous blood were collected from all subjects, and serum was collected after centrifugation. Serum levels of follicle-

stimulating hormone (FSH), luteinizing hormone (LH), and 17β -estradiol (E2) were measured using chemiluminescence immunoassay. Serum levels of 25-(OH) D3 and FT4 were measured using the Siemens Immulite 2000 fully automated immunoassay analyzer.

MRI examinations

MRI examinations were performed using the Siemens Spectra MRI 3.0T scanner. Parameters: slice thickness 2 mm, slice gap 0.2 mm, gradient field strength 10mT.msl, matrix 173×192 , field of view $140 \text{ mm} \times 140 \text{ mm}$. Pituitary height was measured on the mid-sagittal T1 weighted image, and the upper margin morphology, anterior lobe height, posterior lobe position, and pituitary stalk morphology were observed. Coronal measurements included pituitary coronal width, coronal height, sagittal anterior-posterior diameter, and sagittal height, with averages taken. All MRI scans were performed using a Siemens Spectra MRI 3.0T (Siemens AG, Germany). Hormone levels were measured using a Siemens Immulite 2000 immunoassay analyzer (Siemens Healthineers, Germany).

Observational indicators

MRI examinations were performed on both groups, and pituitary conditions and MRI morphological parameters were recorded: coronal height, width, sagittal height, anterior-posterior diameter; serum hormone levels were also measured, including E2, FSH, and LH, and differences in 25-(OH) D3 and FT4 levels between the groups were recorded, exploring the diagnostic value of each indicator for CPP. Pituitary morphology evaluation followed Elster's method ⁽¹⁰⁾, where a clearly concave upper margin was considered grade 1, slightly concave as grade 2, no concavity as grade 3, slight protrusion as grade 4, and obvious protrusion as grade 5.

Statistical analysis

Data analysis was performed using Statistic Package for Social Science (SPSS) 24.0 software (IBM, Armonk, NY, USA). Student's *t*-test was used for continuous variables such as age, height, body weight, bone age, and hormone levels, with $P < 0.05$ considered statistically significant.

RESULTS

Comparison of pituitary conditions between the control and study groups

The pituitary height of patients in the study group was higher than that of the control group, and there was a statistically significant difference in pituitary morphology between the two groups. The proportion of grades 4 and 5 in the study group was higher than

that in the control group ($P < 0.05$, table 2). Additionally, the prevalence of Elster's grades 4 and 5 pituitary morphologies, which indicate more pronounced protrusion, was substantially higher in the CPP group compared to the controls, highlighting the severe morphological changes in patients with CPP. Typical MRI images were shown in figure 1.

Table 2. Comparison of pituitary conditions in the control and study groups.

group	Pituitary height (mm)	The pituitary shape				
		Level 1	Level 2	Level 3	Level 4	Level 5
Control group (n=46)	5.33±0.56	12 (26.0)	11 (23.91)	8 (17.39)	7 (15.22)	8 (17.39)
Study group (n=46)	7.12±0.71	4(8.7)	6 (13.04)	4(8.7)	15 (32.61)	17 (36.96)
χ^2/t	-13.426	12.953				
P	<0.001	0.012				

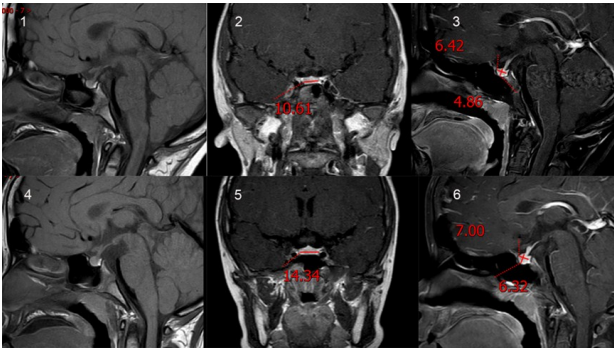


Figure 1. Typical MRI images. (1-3) Before the patient's treatment, 1: MRI scanning T1WI sagittal position showing pituitary morphology, 2: T1+C delayed phase coronal position showing uniform pituitary enhancement, with left and right meridian size of 10.61mm, 3: T1+C delayed phase sagittal position showing uniform pituitary enhancement, with anterior and posterior radial sizes of 6.42mm and upper and lower high meridian sizes of 4.86mm. (4-6) After treatment of the patient, 4: MRI scanning T1WI sagittal position showing pituitary morphology, 5: T1+C delayed phase coronal position showing uniform pituitary enhancement with left and right meridian sizes of 14.34mm, 6: T1+C delayed phase sagittal position showing uniform pituitary enhancement with anterior and posterior radial sizes of 7.00mm and upper and lower high meridian sizes of 6.32mm.

Comparison of pituitary morphology parameters between the control and study groups

Further detailed analysis revealed that the coronal height and the sagittal anterior-posterior diameter were both significantly increased in the study group compared to the control group ($P < 0.05$, table 3), indicating a specific pattern of pituitary enlargement in children with CPP. Conversely, the coronal width was found to be narrower in the study group, reinforcing the notion of abnormal pituitary growth patterns in affected individuals. No significant differences were observed in the vector height between the two groups ($P > 0.05$), suggesting that this parameter may not be affected by the condition.

Table 3. Comparison of pituitary morphology parameters between the control and study groups.

group	Coronation height diameter (mm)	Coronation wide diameter (mm)	Sagittal high diameter (mm)	Vector front and rear diameter (mm)
Control group (n=46)	4.66±0.56	11.18±1.02	4.98±0.56	7.02±0.74
Study group (n=46)	7.15±0.61	10.55±0.98	5.18±0.67	7.77±0.68
t	-20.394	3.021	-1.553	-5.062
P	<0.001	0.003	0.124	<0.001

Comparison of serum sex hormone levels between the control and study groups

The levels of estrogen (E2), luteinizing hormone (LH), and follicle-stimulating hormone (FSH) were significantly elevated in the study group as compared to the control group ($P < 0.05$, table 4). These findings are consistent with the hormonal profile typically seen in CPP, where increased gonadotropin and estrogen levels are indicative of premature activation of the hypothalamic-pituitary-gonadal axis.

Table 4. Comparison of serum sex hormone levels between the control and study groups.

Group	E2(IU/L)	LH(IU/L)	FSH(IU/L)
Control group (n=46)	4.66±0.56	6.45±0.79	46.22±5.16
Study group (n=46)	7.98±0.98	10.22±1.12	120.12±16.66
t	-19.950	-18.656	-28.738
P	<0.001	<0.001	<0.001

Comparison of FT4 and 25-(OH) D3 Levels between the control and study groups

Significant hormonal disparities were also noted in the levels of free thyroxine (FT4) and 25-hydroxyvitamin D3 (25-(OH) D3). The FT4 levels were elevated, whereas the levels of 25-(OH) D3 were significantly reduced in the CPP group compared to controls ($P < 0.05$, table 5). These results suggest an interplay between thyroid function and vitamin D metabolism in the pathophysiology of CPP.

Table 5. Comparison of FT4, 25- (OH) D3 levels in the control and study groups.

Group	FT4(pmol/L)	25-(OH)D3(ng/ml)
Control group (n=46)	17.45±1.23	28.55±3.16
Study group (n=46)	35.11±2.44	14.46±1.98
t	-43.834	25.626
P	<0.001	<0.001

Diagnostic value of pituitary morphology, serum sex hormones, FT4, and 25-(OH) D3 levels for CPP

Receiver Operating Characteristic (ROC) curve analysis was conducted to evaluate the diagnostic performance of each biomarker. The analysis revealed high Area Under the Curve (AUC) values for pituitary height (0.875), coronal height (0.845), estrogen (E2, 0.854), LH (0.811), FSH (0.885), FT4 (0.843) and 25-(OH) D3 (0.886), indicating strong diagnostic potential for each parameter in isolation. Remarkably, when these indicators were combined, the diagnostic accuracy improved, with a composite

AUC of 0.909 (table 6). This demonstrates the enhanced diagnostic utility of a multi-parametric

approach in identifying CPP.

Table 6. Diagnostic value of pituitary morphology, serum sex hormones and FT4, 25- (OH) D3 levels for central precocious puberty.

index	AUC	The best cut-off value	95%CI		sensitivity	specificity	P
			lower limit	upper limit			
Vertical height	0.875	5.945	0.804	0.947	0.874	0.761	<0.001
Coronation height diameter	0.845	5.915	0.756	0.933	0.870	0.826	<0.001
Coronation wide diameter	0.628	10.300	0.514	0.742	0.478	0.804	0.054
Vector front and rear diameter	0.604	7.020	0.488	0.720	0.761	0.435	0.086
E2	0.854	6.065	0.771	0.937	0.872	0.823	<0.001
LH	0.811	7.980	0.715	0.907	0.848	0.825	<0.001
FSH	0.885	53.190	0.814	0.957	0.913	0.783	<0.001
FT4	0.843	25.690	0.758	0.929	0.873	0.829	<0.001
25-(OH)D3	0.886	20.720	0.815	0.956	0.871	0.821	<0.001
Joint prediction	0.909	—	0.848	0.970	0.842	0.848	<0.001

DISCUSSION

CPP is primarily caused by central lesions and involves various complex factors. The pathogenesis includes genetic factors, changes in pituitary morphology, abnormal sex hormone levels, thyroid dysfunction, among others, and single-marker detection lacks specificity and sensitivity. This study aimed to comprehensively diagnose CPP from multiple aspects to improve clinical diagnostic efficacy. Thus, this study aimed to analyze the pituitary MRI morphological parameters and the changes in 25-(OH) D3, FT4, and sex hormone levels in female patients with CPP.

The findings from this study underscore the pivotal role of advanced imaging techniques in diagnosing CPP. MRI, with its high soft tissue resolution, has proved invaluable in delineating pituitary abnormalities that are indicative of CPP. The alterations in pituitary height and morphology, as observed through MRI, corroborate with hormonal changes, specifically elevated levels of E2, LH, and FSH, which are hallmarks of CPP due to their role in stimulating puberty-related changes.

It is reported that children with CPP have abnormalities in the hypothalamic-pituitary-gonadal axis ⁽¹¹⁾. Sex hormone levels increase before puberty in these children. The results of this study show that the levels of E2, LH, and FSH in the study group were significantly higher than those in the control group. Abnormal pituitary function contributes to the occurrence of this disease. The activation of the hypothalamic-pituitary-gonadal axis can promote the action of gonadotropin-releasing hormone (GnRH). Secretion of GnRH is suppressed before puberty, but this inhibition is lifted during puberty, leading to the synthesis of FSH, LH, and E2, thus inducing girls to enter puberty ^(12,13). The results of this study indicate that the levels of E2, LH, and FSH are elevated in children with CPP, consistent with the aforementioned mechanism.

Abnormalities in pituitary function can be reflected not only by abnormal sex hormone levels but also by the imaging features of the pituitary. Pituitary height is considered to be related to

children's height, body mass, bone age index, and corresponding hormones, and analyzing pituitary morphology and height can serve as an auxiliary diagnostic method for CPP ⁽¹⁴⁾. Research has shown that children with precocious puberty have external pituitary morphology differences from normal individuals, with significantly higher pituitary height in the former ⁽¹⁵⁾. Early secretion of GnRH in children with CPP leads to increased levels of gonadotropins, resulting in hypertrophy and proliferation of pituitary gland cells, increased pituitary height, and subsequent release of estrogen. It has been reported that the pituitary edge is mostly flat during childhood and raised during puberty ⁽¹⁶⁾. Female children with CPP exhibit pituitary hyperplasia on MRI, reflecting the early activation of the hypothalamic-pituitary-gonadal axis. Elster grading of the pituitary is closely related to physical development. The results of this study show that the proportion of grades 4 and 5 in the study group was higher than that in the control group, and the coronal height and sagittal anterior-posterior diameter were higher in the study group, while the coronal width was lower than that in the control group. The pituitary diameter can serve as an indicator of whether children have entered puberty, with increased pituitary height and raised edges, which is consistent with pituitary changes during puberty ⁽¹⁷⁾. MRI can reflect changes in the structure and function mentioned above; therefore, these parameters can serve as potential indicators for diagnosing CPP.

Some studies have indicated an association between vitamin D deficiency and precocious puberty because insufficient vitamin D inhibits the absorption and metabolism of calcium and phosphorus in the body, affecting thyroid function and bone development ⁽¹⁸⁾. Abnormal development in children with CPP may lead to excessive growth in height before adulthood, but rapid fusion of epiphyseal plates can result in short stature in adulthood ⁽¹⁹⁾. The results of this study show that the FT4 level was higher and the 25-(OH) D3 level was significantly lower in the study group than in the control group. An increase in FT4 level suggests thyroid dysfunction, indirectly promoting estrogen stimulation of the

body, providing conditions for the occurrence of CPP. It has been suggested that 25-(OH) D3 acts on vitamin D receptors to regulate the immune system and the hypothalamic-pituitary-gonadal axis⁽²⁰⁾. Deficiency in 25-(OH) D3 affects these functions, leading to the occurrence of CPP.

Building upon previous research, this study jointly analyzed differences in sex hormone levels, pituitary MRI-related parameters and morphology, thyroid function-related parameters, and 25-(OH) D3 between female children with CPP and normal children. The results of this study show that the AUC values for the combined diagnosis of CPP using pituitary height, coronal height, E2, LH, FSH, FT4 and 25-(OH) D3 were higher than when each indicator was used separately, indicating a higher diagnostic value of the combined indicators. However, this study also has limitations, such as a small sample size and being a single-center study, which require further expansion of the sample size for in-depth analysis in the future.

In interpreting these findings, it is essential to consider the limitations noted in this study, such as the small sample size and the study being confined to a single center. These factors may affect the generalizability of the results, and thus, further studies with a larger cohort and multiple centers are warranted to substantiate these findings.

Ultimately, this research enhances our understanding of CPP and underscores the importance of a comprehensive diagnostic approach that utilizes both advanced imaging and detailed hormonal profiling. Such approaches are likely to improve diagnostic precision and lead to better-targeted interventions, which are vital for managing the potential complications associated with CPP.

In conclusion, there are significant differences in pituitary MRI morphology parameters, sex hormones, 25-(OH) D3, and FT4 levels in female children with CPP, which are of great significance in the diagnosis of central precocious puberty.

Conflict of interests: The authors declare that they have no conflict of interests.

Funding: This work was supported by the Project supported by Hainan Province Clinical Medical Center (QWYH202175).

Ethical consideration: This study was approved by the ethics committee of Hainan Women & Children's Medical Center (Approval no. HWC-MC-1302). Signed written informed consents were obtained from the patients and/or guardians.

Authors' contributions: Zhiyu Zhang, Yong Wei: Conceptualization, methodology, writing original draft preparation. Yaqin Zhang, Jiaoling Wen: Investigation, software, statistical analysis. Yi Lin, All authors read and approved the final manuscript.

REFERENCES

- Shi L, Jiang Z and Zhang L (2022) Childhood obesity and central precocious puberty. *Frontiers in Endocrinology*, **13**: 1056871.
- Moise-Silverman J and Silverman LA (2022) A review of the genetics and epigenetics of central precocious puberty. *Frontiers in Endocrinology*, **13**: 1029137.
- Maione L, Bouvattier C and Kaiser UB (2021) Central precocious puberty: Recent advances in understanding the aetiology and in the clinical approach. *Clinical Endocrinology*, **95**(4): 542-555.
- Ceraudo M, Criminelli RD, Di Iorgi N, Cama A, Piatelli G and Consales A (2022) Pediatric pituitary adenoma with mixed FSH and TSH immunostaining and FSH hypersecretion in a 6-year-old girl with precocious puberty: case report and multidisciplinary management. *International Journal of Neuroscience*, **132**(4): 362-369.
- Soriano-Guillen L and Argente J (2019) Central precocious puberty, functional and tumor-related. *Best Practice & Research Clinical Endocrinology & Metabolism*, **33**(3): 101262.
- Brito VN, Canton A and Seraphim CE, et al. (2023) The Congenital and Acquired Mechanisms Implicated in the Etiology of Central Precocious Puberty. *Endocrine Reviews*, **44**(2): 193-221.
- Calcaterra V, Rossi V and Massini G, et al. (2022) Precocious puberty and microbiota: The role of the sex hormone-gut microbiome axis. *Frontiers in Endocrinology*, **13**: 1000919.
- Zevin EL and Eugster EA (2023) Central precocious puberty: a review of diagnosis, treatment, and outcomes. *Lancet Child & Adolescent Health*, **7**(12): 886-896.
- Shi Y, Ma Z, Yang X, Ying Y, Luo X and Hou L (2022) Gonadotropin-releasing hormone analogue and recombinant human growth hormone treatment for idiopathic central precocious puberty in girls. *Frontiers in Endocrinology*, **13**: 1085385.
- Lee HS (2023) Central precocious puberty: is routine brain MRI screening necessary for girls? Commentary on "Brain magnetic resonance imaging (MRI) findings in central precocious puberty patients: is routine MRI necessary for newly diagnosed patients?". *Annals of Pediatric Endocrinology & Metabolism*, **28**(3): 155-156.
- Yeh SN, Ting WH and Huang CY, et al. (2021) Diagnostic evaluation of central precocious puberty in girls. *Pediatrics and Neonatology*, **62**(2): 187-194.
- Calcaterra V, De Filippo G and Albertini R, et al. (2021) Effectiveness of basal LH in monitoring central precocious puberty treatment in girls. *Journal of Pediatric Endocrinology & Metabolism*, **34**(1): 45-50.
- Phadte A, Sarathi V and Budyal S, et al. (2023) Gonadotropin-Dependent Precocious Puberty: Single-Center Experience from Western India. *Indian Pediatrics*, **60**(6): 463-466.
- Vurali D, Gonc EN, Alikasifoglu A, Kandemir N and Ozon ZA (2021) Central nervous system imaging in girls with central precocious puberty: when is necessary? *Archives of Endocrinology Metabolism*, **64**(5): 591-596.
- Canton A and Latronico AC (2021) Brain MRI in Girls with Central Precocious Puberty: A Time for New Approaches. *Journal of Clinical Endocrinology & Metabolism*, **106**(7): e2806-e2808.
- Yang XD, Shi JX and Liao WC, et al. (2022) Intervention of Compound Xueshuantong Capsule on the incidence of heart failure in patients with acute myocardial infarction after PCI based on the combination of disease and syndrome: A multi-center, randomized, double-blind, controlled trial. *Medicine*, **101**(50): e32311.
- Helvacioğlu D, Demircioğlu TS and Guran T, et al. (2021) Cranial MRI Abnormalities and Long-term Follow-up of the Lesions in 770 Girls with Central Precocious Puberty. *Journal of Clinical Endocrinology & Metabolism*, **106**(7): e2557-e2566.
- Yu W, Lu Y and Chen T, et al. (2023) Frequency-dependent alterations in regional homogeneity associated with puberty hormones in girls with central precocious puberty: A resting-state fMRI study. *Journal of Affective Disorders*, **332**: 176-184.
- Chen T, Lu Y and Wang Y, et al. (2019) Altered Brain Structure and Functional Connectivity Associated with Pubertal Hormones in Girls with Precocious Puberty. *Neural Plasticity*, **2019**: 1465632.
- Zou P, Zhang L and Zhang R, et al. (2023) Development and Validation of a Combined MRI Radiomics, Imaging and Clinical Parameter-Based Machine Learning Model for Identifying Idiopathic Central Precocious Puberty in Girls. *Journal of Magnetic Resonance Imaging*, **58**(6): 1977-1987.

