

Analysis of the application value of BI-RADS classification grading diagnosis based on imaging examinations for predicting atypical breast ductal hyperplasia and breast cancer

Z. Jiang^{1#}, D. Xu^{2#}, S. Wang³, X. Chen², S. Gao⁴, Y. Zhang^{2*}, J. Ma^{2*}

¹Department of Ultrasound Medicine, Nanjing Drum Tower Hospital Affiliated to Nanjing University Medical School, Nanjing, Jiangsu, 210008, China

²Department of General Surgery, Nanjing Drum Tower Hospital, The Affiliated Hospital of Nanjing University Medical School, Nanjing, Jiangsu, 210008, China

³Department of General Surgery, Medical School of Southeast University Nanjing Drum Tower Hospital, Nanjing, Jiangsu, 210008, China

⁴Department of Breast, Women's Hospital of Nanjing Medical University (Nanjing Maternity and Child Health Care Hospital), Nanjing Medical University, Nanjing, Jiangsu, 210008, China

ABSTRACT

► Original article

*Corresponding authors:

Jingjing Ma & Yin Zhang,

E-mail:

majingjing202312@163.com,

zhangyinglyy203@163.com

Received: January 2024

Final revised: February 2024

Accepted: February 2024

Int. J. Radiat. Res., October 2024;
22(4): 985-989

DOI: 10.61186/ijrr.22.4.985

Keywords: Comprehensive nursing, lung cancer, radiotherapy, respiratory function test, quality of life, self-care ability.

#These authors contributed equally to this work as co-first author.

Background: To investigate the application value of Breast Imaging Reporting and Data System (BI-RADS) classification grading diagnosis based on breast ultrasound, molybdenum target radiography mammography and MRI imaging for predicting atypical breast ductal hyperplasia (ADH) and breast cancer (BC). **Materials and Methods:** Retrospective analysis of patients who visited the Department of Mammary Gynecology and Obstetrics of Nanjing Medical University for breast lumps between January 2015 and July 2021, based on the pathological findings of breast lumps, included 150 patients with benign breast usual ductal hyperplasia (UDH), 100 patients with atypical breast hyperplasia ADH, and 100 patients with breast cancer BC. The masses were evaluated and graded according to the fifth edition of the BI-RADS criteria, and the receiver operating characteristic (ROC) curves were drawn based on ultrasound, molybdenum target radiography mammography, and MRI for BI-RADS grading to identify atypical hyperplasia (ADH) and breast cancer and the feasibility of the three imaging methods for predicting breast atypical hyperplasia ADH and breast cancer BC was compared. **Results:** The best cut-off value for breast ultrasound prediction of breast atypical hyperplasia ADH and breast cancer BC was BI-RADS grade 3 and the best cut-off value for molybdenum target radiography mammography and MRI prediction of breast atypical hyperplasia ADH and breast cancer BC was BI-RADS grade 4A, with corresponding area under the curve (AUC) of 0.691, 0.757, 0.866; the Jorden index was 0.363, 0.448, 0.662; the sensitivity was 56.30%, 48.20%, 71.20%; specificity 80.00%, 96.60%, 95.00%; positive predictive value 78.87%, 97.22%, 98.11%; negative predictive value 57.97%, 53.43%, 47.50%, respectively. **Conclusion:** BI-RADS classification grading diagnosis based on imaging examination has a high value in predicting breast dysplasia ADH and breast cancer BC. BI-RADS classification grading can be given priority in clinical prediction of breast dysplasia ADH and breast cancer BC to reduce unnecessary invasive examination.

INTRODUCTION

In China, the incidence and mortality rate of breast cancer is consistently high among female malignancies ^(1,2). The main methods used to assist in the diagnosis of breast disease include breast ultrasound, mammography molybdenum target radiography and magnetic resonance imaging (MRI) ⁽³⁾. The American College of Radiology introduced the Breast Imaging Reporting and Data System (BI-RADS) in 2003 ⁽⁴⁾. The BI-RADS grading scale provides a standardized and unified imaging format to improve the accuracy of imaging in the differential diagnosis

of breast masses ^(5,6).

In the clinical diagnosis of breast cancer, there is still a large overlap between benign, precancerous and malignant breast lesions. This situation is particularly evident in atypical hyperplasia of the breast and breast cancer. Atypical hyperplasia of the breast is a long-standing precancerous lesion ⁽⁷⁾. Approximately 16.7% of clinically reported atypical hyperplasia is associated with the development of breast cancer, which represents a 9% increased risk of breast cancer compared to the general hyperplasia population ⁽⁸⁾. At present, the commonly used clinical imaging tests cannot directly diagnose breast atypical

hyperplasia or breast cancer, and as a high-risk lesion, the preferred treatment is surgical biopsy^(9,10). Surgical biopsy is the gold standard for the diagnosis of breast atypical hyperplasia and breast cancer, but biopsy is invasive, making it an urgent challenge to effectively differentiate benign breast tumors from breast atypical hyperplasia and breast cancer and to reduce unnecessary invasive testing^(11,12). This study retrospectively analyzed the BI-RADS grading characteristics of ultrasound, mammography molybdenum target radiography and MRI in patients with pathologically confirmed benign breast tumors, atypical breast hyperplasia and breast cancer to analyze the value of the BI-RADS grading technique for predicting atypical breast hyperplasia and breast cancer and to improve the predictive efficacy of imaging examinations for atypical breast hyperplasia and breast cancer prior to biopsy and to provide a reference for surgical biopsy.

MATERIALS AND METHODS

General data

A total of 100 patients diagnosed with breast cancer, 100 patients diagnosed with atypical hyperplasia of the breast and 150 patients diagnosed with benign breast tumors were collected from January 2015 to July 2021 after breast pathological examination at the Maternity Hospital of Nanjing Medical University. Patients with benign breast tumors were used as the control group, and patients with atypical hyperplasia of the breastADH and breast cancerBC were used as the study group. Patients' imaging data were collected and diagnosed according to the BI-RADS, a classification proposed by American Radiology. All imaging results were graded by two imaging physicians who were trained in BI-RADS diagnosis. Some patients did not receive all imaging examinations, so there were missing cases in all imaging examinations. The study was approved by the Ethics Committee of the Maternity Hospital of Nanjing Medical University, and all subject information was kept strictly confidential.

Methods

Ultrasonography

MyLab60 B ultrasound machine with LA435 linear probe with a probe frequency of 10.0 MHZ, Italy, for 2D imaging.

Mammography molybdenum target radiography

A GE-2000DS molybdenum target radiography machine from General Motors, USA, was used for routine bilateral axial (Cranioca-udel, CC) and lateral oblique (Mediolateral oblique, MLO) molybdenum target radiography of the patient.

MRI scan + enhancement

The patient is placed in a prone position with the

breast naturally drooping bilaterally, and a conventional plain scan and dynamic contrast-enhanced MRI are performed using a Philips MRI system Achiva 1.5T.

BI-RADS classification

According to the BI-RADS classification and its significance, there are four groups: BI-RADS grade 2: benign lesions; BI-RADS grade 3: benign lesions are more likely and require follow-up; BI-RADS grade 4A: low risk of malignancy; BI-RADS grade 4B and above, high risk of malignancy.

Statistics

SPSS 25.0 software was used to process the data. Count data were expressed as mean \pm standard deviation and t-test was used to compare significance after testing for compliance with normal distribution, while measurement data were expressed as absolute counts (percentages). The value of each method in predicting breast atypical hyperplasia and breast cancer was assessed by drawing ROC curves based on breast ultrasound, molybdenum target radiography and MRI for BI-RADS grading of breast atypical hyperplasia and breast cancer based on pathological findings. $P < 0.05$ was considered to be a significant difference.

RESULTS

Pathological diagnosis results

The 150 patients with benign breast tumors included 108 fibroadenomas, of which 23 were associated with adenopathy, 30 with adenopathy alone, 6 with intraductal papillomas, 4 with lipomas and 2 with benign tumors. The 100 patients with atypical hyperplasia of the breastADH included 16 cases of fibroadenoma with atypical hyperplasiaADH, 57 cases of intraductal papilloma with atypical hyperplasiaADH, 22 cases of adenopathy with atypical hyperplasiaADH, 3 cases of benign lobular tumors with atypical hyperplasiaADH and 2 cases of simple ductal epithelial atypical hyperplasiaADH. The 100 cases of breast cancerBC included 97 invasive carcinomas, including one combined with Paget's disease, one intraductal carcinoma, one mucinous carcinoma and one cystic carcinoma.

Basic characteristics of the cases

The study group was significantly older than the control group, and both the study and control groups were seen primarily for the detection of breast masses. Depending on the patient's condition, signs, age and financial factors, some patients did not receive all three methods of examination at the same time. Ultrasound, mammographymolybdenum target radiography and MRI of the breast were missing in 0, 3 and 110 cases respectively in patients with benign breast tumors. In patients with atypical

hyperplasiaADH, ultrasound, mammographymolybdenum target radiography and MRI were missing in 1, 7 and 51 cases respectively. Breast ultrasound, mammographymolybdenum target radiography and MRI were absent in 1, 0 and 3 cases respectively in breast cancer patients. No statistical difference in the proportion of patients were found between the two groups at BI-RADS levels 2 and 4A for ultrasound, and at BI-RADS level 4A for molybdenum target radiography, but the rest were statistically different ($p < 0.05$).

In ultrasound, mammographymolybdenum target radiography and MRI, the proportion of patients with

BI-RADS grade 4A or higher was significantly higher in study group than in the control group, while the proportion of patients with 4A grade or lower was significantly lower in the study group than in the control group. The BI-RADS grade of ultrasound, mammography, and MRI was 4A and the case was pathologically diagnosed as ductal carcinoma in situ (figure 1). The number and proportion of patients with different BI-RADS grades in each of the three groups for each imaging study are shown in table 1, with P being the test level for the study group versus the control group.

Table 1. Basic information on imaging examinations of all patients.

Methods	BI-RAD Sgrading	Control group	Study group		P
		Benign tumour (n=150)	Atypical hyperplasia (n=100)	Breast cancer (n=100)	
Age	-	41.29±10.61	46.36±9.76	49.63±7.95	<0.001
Signs/symptoms					
Breast lump	-	124 (82.67)	69 (69.00)	94 (94.00)	-
Bleeding nipples	-	8 (5.33)	24 (24.00)	0 (0.00)	-
Nipple discharge	-	7 (4.67)	0 (0.00)	0 (0.00)	-
Periodic painful swelling of the breast	-	0 (0.00)	5 (5.00)	0 (0.00)	-
Calcification of the breast	-	7 (4.67)	0 (0.00)	0 (0.00)	-
Nipple breakdown and erosion	-	0 (0.00)	1 (1.00)	3 (3.00)	-
Other signs	-	4 (2.67)	1 (1.00)	2 (2.00)	-
No specific signs	-	0 (0.00)	1 (1.00)	1 (1.00)	-
Ultrasound (349 cases)	Grade 2 (21 cases)	6 (18.67)	12 (12.12)	3 (3.03)	0.17
	Grade 3 (186 cases)	114 (76.00)	56 (56.57)	16 (16.16)	<0.001
	Grade 4A (70 cases)	28 (18.67)	26 (26.26)	16 (16.16)	0.56
	Grade 4A or above (72 cases)	2 (1.33)	6 (6.06)	64 (64.65)	<0.001
Molybdenum target radiography (340 cases)	Grade 2 (81 cases)	53 (36.05)	26 (27.96)	2 (2.00)	<0.001
	Grade 3 (86 cases)	51 (34.69)	26 (27.96)	9 (9.00)	<0.001
	Grade 4A (75 cases)	38 (25.85)	27 (29.03)	10 (10.00)	0.14
	Grade 4A or above (98 cases)	5 (3.40)	14 (15.05)	79 (79.00)	<0.001
MRI (186 cases)	Grade 2 (9 cases)	7 (17.50)	1 (2.04)	1 (1.03)	<0.001
	Grade 3 (35 cases)	18 (45.00)	17 (34.69)	0 (0.00)	<0.001
	Grade 4A (36 cases)	13 (32.50)	19 (38.78)	4 (4.12)	0.02
	Grade 4A and above (106 cases)	2 (5.00)	12 (24.49)	92 (94.85)	<0.001

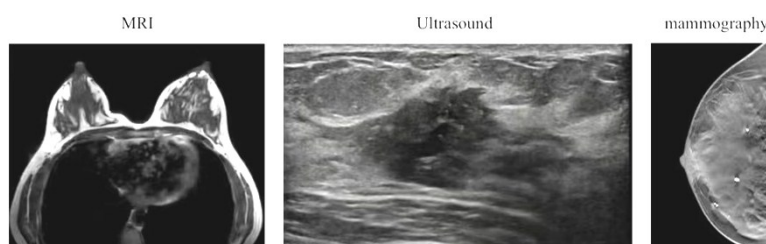


Figure 1. The BI-RADS grade of MRI, ultrasound, mammography and was 4A.

ROC curves and predictive performance

The ROC curve was plotted by excluding missing values (figure 21) and the area under the curve (AUC) for differentiating benign breast tumors from atypical breast hyperplasiaADH and breast cancerBC based on BI-RADS grading of breast ultrasound, mammographymolybdenum target radiography and MRI was 0.691, 0.757 and 0.866, respectively; the Youden index was 0.363, 0.448 and 0.662; sensitivity was 56.30% and 48.20%, 71.20%; specificity 80.00%,

96.60%, 95.00%; positive predictive value 78.87%, 97.22%, 98.11%; negative predictive value 57.97%, 53.43%, 47.50%, respectively. Mammography Molybdenum target radiography and MRI have very high diagnostic specificity and positive predictive values for atypical hyperplasiaADH and breast cancerBC, but low diagnostic sensitivity and negative predictive values. MRI had the highest predictive efficacy and ultrasound the lowest.

Table 2. Predictive efficacy of three imaging methods for atypical hyperplasia of the breastADH and beyondBC.

Methods	AUC	P	Yordon Index	Sensitivity	Specificity	Positive predictive value	Negative predictive value
Ultrasound	0.691	0.000	0.363	56.30%	80.00%	78.87%	57.97%
Molybdenum target radiography	0.757	0.000	0.448	48.20%	96.60%	97.22%	53.43%
MRI	0.866	0.000	0.662	71.20%	95.00%	98.11%	47.50%

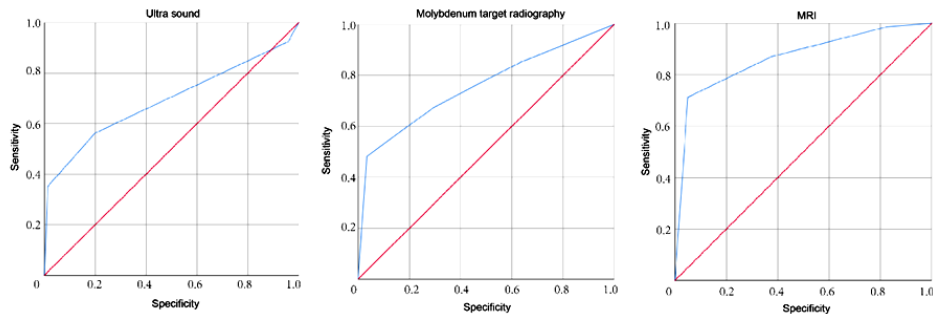


Figure 2. ROC curve for the differential diagnosis of atypical breast hyperplasiaADH and breast cancerBC by BI-RADS classification.

DISCUSION

Atypical hyperplasiaADH of the breast, as a precancerous lesion of breast cancer, is often characterized by clinical symptoms and signs, but its pathological features are between benign and malignant breast disease, and it is often difficult to distinguish from breast cancer (13). Imaging plays an important role in the early detection, treatment and prognosis of breast cancer, as 16.7% of breast atypical hyperplasiaADH is associated with breast cancer (7). How to improve the detection of breast atypical hyperplasiaADH and breast cancerBC through imaging and reduce the use of invasive investigations is still a challenge that needs to be addressed.

The BI-RADS classification is the most commonly used method for the diagnosis and screening of breast cancer by standardizing the terminology used to characterize and report breast lesions and it can improve the diagnostic efficacy of breast cancer by excluding bias in breast cancer imaging (14). BI-RADS grading of breast masses helps to communicate risk stratification of breast masses between the imaging physician and the clinician, and allows the clinician to make a reasonable judgement of breast disease (15,16). Several studies have shown that the use of the BI-RADS classification can improve the accuracy of imaging in the diagnosis of adjuvant breast cancer (17,18). Thus, we hope that the BI-RADS classification will improve the predictive efficacy of imaging for breast atypical hyperplasiaADH and breast cancerBC in order to reduce unnecessary invasive investigations.

In our study, atypical hyperplasiaADH and breast cancerBC were studied as the study group and benign breast tumours were used as the control group to investigate the value of the BI-RADS classification of the base and imaging examinations in predicting breast atypical hyperplasiaADH and breast cancerBC. The results of the study showed that imaging based on the BI-RADS classification had

good predictive efficacy for breast atypical hyperplasiaADH and breast cancerBC, but the diagnostic sensitivity of all three methods was not high, with MRI having the highest diagnostic sensitivity of 71.20%, meaning that the BI-RADS classification had a high rate of missed diagnosis but a relatively low rate of misdiagnosis when used to predict breast atypical hyperplasiaADH and breast cancerBC. Breast ultrasound has the lowest predictive efficacy of the three imaging methods and is not the first choice of adjunctive test to predict atypical hyperplasiaADH and breast cancerBC. MammographyMolybdenum target radiography has been widely accepted as the preferred method of screening for breast cancer because of its intermediate predictive performance between the other two tests (19). The relatively low sensitivity and negative predictive value of mammographymolybdenum target radiography may be due to the difficulty of differentiating microscopic lesions in the breast and the relatively demanding location of the tumor (20,21).

In our study, some women did not undergo MRI due to financial factors, and the cost effect of breast cancer screening methods has been widely discussed in recent years (22,23), which leads us to consider the cost effect. MRI has the highest efficacy in predicting breast atypical hyperplasiaADH and breast cancerBC, but the cost of MRI is much higher than ultrasound and mammography, and MRI cannot be prioritized as the first choice in clinical work differential tool. In conclusion, the value of the three types of imaging based on the BI-RADS classification in predicting breast atypical hyperplasiaADH and breast cancerBC is positive and reasonable reference to the BI-RADS classification results of imaging examinations can effectively reduce unnecessary invasive investigations.

It should be noted that our study was a retrospective study with a high number of confounding factors and it was not possible to effectively exclude the influence of confounding

factors therefore, a multicenter, large sample size prospective study is urgently needed. Secondly, prospective studies to exclude bias are necessary as some patients are prone to bias during analysis due to the lack of imaging data. MRI is mostly performed when clinicians consider a breast mass as a more likely malignant lesion.

In conclusion, the value of BI-RADS-based ultrasound, mammography, molybdenum target radiography and MRI in predicting breast atypical hyperplasia/ADH and breast cancer/BC is positive, with MRI having the highest predictive efficacy and mammography having both higher predictive efficacy and economic value. Imaging based on BI-RADS classification is worth promoting in clinical practice to predict breast atypical ductal hyperplasia and breast cancer and to reduce the need for unnecessary invasive investigations.

Conflicts of Interest: The authors report no conflict of interest.

Availability of data and materials: The data that support the findings of this study are available from the corresponding author upon reasonable request.

Ethics: The study was approved by the Ethics Committee of the Maternity Hospital of Nanjing Medical University, (NO.2021KY-087)

Funding: This study was supported by the Scientific Research Initiation Project for Introducing Talents in Nanjing Gulou Hospital, (NO.RC2022-029).

Author contributions: Y.Z. and J.M. designed the study, Z.J. and D.X. wrote the manuscript, S.W. and X.C. collected and analyzed data, S.G. revised the manuscript, Z.J. and D.X. made equal contributions in this work. All authors read and approved the final submitted manuscript.

REFERENCES

1. Lei S, Zheng R, Zhang S, et al. (2021) Global patterns of breast cancer incidence and mortality: A population-based cancer registry data analysis from 2000 to 2020. *Cancer Communications*, **41**(11): 1183-1194.
2. Eshaghi M (2020) The effect of pain management on pain reduction in women with breast cancer. *Sjmsm*, **2**(2):1-5.
3. He Z, Chen Z, Tan M, et al. (2020) A review on methods for diagnosis of breast cancer cells and tissues. *Cell Proliferation*, **53**(7): e12822.
4. Liberman L and Menell JH (2002) Breast imaging reporting and data system (BI-RADS). *Radiologic Clinics*, **40**(3): 409-430.
5. Orel S (2008) Who should have breast magnetic resonance imaging evaluation? *Journal of Clinical Oncology*, **26**(5): 703-711.
6. Magny SJ, Shikhman R and Keppke AL (2022) Breast imaging reporting and data system. In StatPearls [Internet]: StatPearls publishing.
7. Said SM, Visscher DW, Nassar A, et al. (2015) Flat epithelial atypia and risk of breast cancer: a Mayo cohort study. *Cancer*, **121**(10):1548-1555.
8. Rudin AV, Hoskin TL, Fahy A, et al. (2017) Flat epithelial atypia on core biopsy and upgrade to cancer: a systematic review and meta-analysis. *Annals of Surgical Oncology*, **24**: 3549-3558.
9. Rageth CJ, O'Flynn EA, Pinker K, et al. (2019) Second international consensus conference on lesions of uncertain malignant potential in the breast (B3 lesions). *Breast Cancer Research and Treatment*, **174**: 279-296.
10. Pinder S, Shaaban A, Deb R, et al. (2018) NHS Breast Screening multidisciplinary working group guidelines for the diagnosis and management of breast lesions of uncertain malignant potential on core biopsy (B3 lesions). *Clinical radiology*, **73**(8): 682-692.
11. Zubor P, Kubatka P, Kajo K, et al. (2019) Why the gold standard approach by mammography demands extension by multiomics? Application of liquid biopsy miRNA profiles to breast cancer disease management. *International Journal of Molecular Sciences*, **20**(12): 2878.
12. Cykowska A, Marano L, D'Ignazio A, et al. (2020) New technologies in breast cancer sentinel lymph node biopsy; from the current gold standard to artificial intelligence. *Surgical Oncology*, **34**: 324-335.
13. Hartmann LC, Degnim AC, Santen RJ, et al. (2015) Atypical hyperplasia of the breast—risk assessment and management options. *New England Journal of Medicine*, **372**(1): 78-89.
14. Jung HK, Kuzmiak CM, Kim KW, et al. (2017) Potential use of American College of Radiology BI-RADS mammography atlas for reporting and assessing lesions detected on dedicated breast CT imaging: preliminary study. *Academic Radiology*, **24**(11): 1395-1401.
15. D'Orsi C, Bassett L, Feig S (2018) Breast imaging reporting and data system (BI-RADS). Breast imaging atlas, 4th edn. American College of Radiology, Reston.
16. Berg WA, Campassi C, Langenberg P, et al. (2000) Breast imaging reporting and data system: Inter- and intraobserver variability in feature analysis and final assessment. *American Journal of Roentgenology*, **174**(6): 1769-1777.
17. Sirous M, Shahnani PS, Sirous A (2018) Investigation of frequency distribution of breast imaging reporting and data system (BI-RADS) Classification and epidemiological factors related to breast cancer in Iran: A 7-year Study (2010–2016). *Advanced Biomedical Research*, **7**.
18. Eghtedari M, Chong A, Rakow-Penner R, et al. (2021) Current status and future of BI-RADS in multimodality imaging, from the AJR special series on radiology reporting and data systems. *American Journal of Roentgenology*, **216**(4): 860-873.
19. Tollens F, Baltzer PA, Dietzel M, et al. (2021) Cost-effectiveness of MR-mammography in breast cancer screening of women with extremely dense breasts after two rounds of screening. *Frontiers in Oncology*, **11**: 724543.
20. Hu Y, Zhang Y, Cheng J (2019) Diagnostic value of molybdenum target combined with DCE-MRI in different types of breast cancer. *Oncology Letters*, **18**(4): 4056-4063.
21. Gu WQ, Cai SM, Liu WD, et al. (2022) Combined molybdenum target X-ray and magnetic resonance imaging examinations improve breast cancer diagnostic efficacy. *World Journal of Clinical Cases*, **10**(2): 485.
22. Kaiser CG, Dietzel M, Vag T, et al. (2021) Cost-effectiveness of MR-mammography vs. conventional mammography in screening patients at intermediate risk of breast cancer-A model-based economic evaluation. *European Journal of Radiology*, **136**: 109355.
23. Tollens F, Baltzer PA, Dietzel M, et al. (2021) Cost-effectiveness of digital breast tomosynthesis vs. abbreviated breast MRI for screening women with intermediate risk of breast cancer—how low-cost must MRI be? *Cancers*, **13**(6): 1241.

