

Clinical analysis of gamma knife radiosurgery for pituitary adenomas

J. Shan^{1*}, Y. Wen², Y. Guo³

¹Special Examination Department, Shandong Daizhuang Hospital, JiNing City, Shandong, China

²Lingcheng District Hospital of Traditional Chinese Medicine, Dezhou City, Shandong, China

³Gamma knife centre, Shandong Daizhuang Hospital, JiNing city, Shandong, China

ABSTRACT

► Original article

***Corresponding author:**

Junlai Shan, M.Sc.,

E-mail:

Shanaaa0410@163.com

Received: April 2024

Final revised: May 2024

Accepted: May 2024

Int. J. Radiat. Res., January 2025;
23(1): 61-68

DOI: 10.61186/ijrr.23.1.61

Keywords: Gamma Knife, radiosurgery, pituitary adenoma, risk factors, regression analysis.

Background: To evaluate the efficacy and safety of Gamma Knife radiosurgery in the treatment of pituitary adenomas. **Materials and Methods:** A retrospective analysis was conducted on 123 patients with pituitary adenomas who underwent Gamma Knife radiosurgery at Shandong Daizhuang hospital. All patients were followed up for 12 months post-treatment and complete follow-up data were obtained. Follow-up data included records of disease progression (medical history and physical examination changes), imaging and endocrine follow-up results at re-examination. Univariate analysis was performed to identify factors affecting tumor control and post-treatment complications, and factors with statistical significance ($P < 0.05$) were subjected to multivariate analysis. **Results:** Clinical data of 123 patients with pituitary adenomas were included in this study, with 51 patients in the postoperative group who had previously undergone surgical treatment, and 72 patients who were treated first with Gamma Knife radiosurgery. Except for age, there were no statistically significant differences in baseline data between the two groups. Tumor volume [$P=0.034$, odds ratio (OR)=1.071, 95% confidence interval (CI): 0.121-5.206] and tumor invasion ($P=0.005$, OR=0.233, 95% CI: 0.202-0.392) were predictive factors for tumor progression. The results of the 1-year follow-up showed no statistically significant difference in efficacy between patients with pituitary adenomas who had previously undergone surgical treatment and those who were first treated with Gamma Knife radiosurgery. **Conclusion:** Gamma Knife radiosurgery is an effective treatment option for patients with pituitary adenomas, regardless of whether they have previously undergone surgical treatment.

INTRODUCTION

Pituitary adenoma is a benign tumor that grows within the pituitary gland, located at the base of the brain, and represents a manifestation of dysfunction in the hypothalamic-pituitary-target gland axis (1, 2). Pituitary adenoma ranks second in the incidence of intracranial tumors, with an incidence rate of approximately 1 per 100,000, accounting for about 15% of primary central nervous system tumors (3). Pituitary adenoma is the most common tumor in the sellar region, accounting for approximately 10% of intracranial tumors, with a prevalence of 20% to 30% in autopsy studies. The age of onset of pituitary adenomas ranges from 10 to 90 years, with an average age of about 50 years, indicating a higher incidence in adults (4, 5). Symptoms of pituitary adenomas may vary depending on tumor type, size, and location, with common symptoms including persistent headaches, vision problems (visual field defects, blurriness, or diplopia), hormonal abnormalities (menstrual irregularities, breast enlargement, growth abnormalities, or Cushing's syndrome), and increased intracranial pressure (6-8). Pituitary

adenomas can be classified based on their hormonal function into functional and non-functional adenomas (9). Functional pituitary adenomas mainly include prolactinomas, growth hormone-secreting adenomas, adrenocorticotrophic hormone-secreting adenomas, and thyroid-stimulating hormone-secreting adenomas, while non-functional pituitary adenomas typically do not cause hormone overproduction, thus may not present obvious symptoms in the early stages (10, 11). When classifying pituitary adenomas based on tumor diameter on radiological imaging, those with a diameter ≤ 1 cm are classified as microadenomas, those with a diameter in the range of 1 to 4 cm are classified as macroadenomas, and those with a diameter > 4 cm are classified as giant adenomas (12). Hardy further divides pituitary tumors into macroadenomas and microadenomas, with diameters < 10 mm classified as microadenomas and diameters ≥ 10 mm classified as macroadenomas (13). Combining tumor size and radiological characteristics, Cuiot and Hardy classified pituitary adenomas into two types with 5 grades, namely the limited type and the invasive type, with the limited type including grades 0, I, and II, and the invasive

type including grades III and IV⁽¹⁴⁾. Macroadenomas or giant adenomas often exhibit typical invasiveness and infiltration of surrounding structures such as the dura mater, cavernous sinuses, and bone, while non-invasive adenomas simply compress or push adjacent tissues⁽¹⁵⁾. Although the majority of pituitary adenomas exhibit expansive growth, approximately 35% of pituitary adenomas display invasive growth, infiltrating surrounding tissues such as the dura mater, cavernous sinuses, and even damaging the floor of the sella or adjacent bone structures. Seeking rational and effective treatment modalities is a primary concern shared by healthcare professionals.

Treatment options for pituitary adenomas depend on the specific type of tumor, with the main modalities being a combination of endocrinology and neurosurgery⁽¹⁶⁾. Currently, common treatment methods include medical therapy, surgical intervention, and radiation therapy⁽¹⁷⁾. Among medical therapies, drugs for prolactinomas and growth hormone-secreting adenomas are most common, such as bromocriptine, cabergoline, and octreotide⁽¹⁸⁾. For patients with acromegaly due to growth hormone-secreting adenomas, commonly used drugs include octreotide and levodopa, particularly if the tumor does not exhibit invasive growth⁽¹⁸⁾. With the continuous development of endoscopic and neuro-navigation techniques, microscopic transcranial, microscopic transsphenoidal, and endoscopic transsphenoidal surgeries have become common approaches for pituitary adenomas. However, surgical complications such as intracranial infections, intracranial hematomas, visual impairments, and hypothalamic injuries should not be overlooked⁽¹⁹⁾. Radiation therapy can be utilized for pituitary adenomas that cannot be surgically removed or for residual tumors following surgery. Personalized treatment plans should be devised based on clinical circumstances to enhance patients' quality of life⁽²⁰⁾.

In 1968, Sweden successfully developed the world's first Gamma Knife treatment device, providing a new approach for treating pituitary tumors. With advancements in diagnostic tools and technology, the efficacy of Gamma Knife treatment for pituitary adenomas has continuously improved, making it one of the main treatment modalities for these tumors⁽²¹⁾. Magnetic Resonance Imaging (MRI) enables precise targeting for Gamma Knife treatment, and employing steep dose gradient lines, such as the -50% isodose line, can further reduce the likelihood of postoperative complications. Gamma Knife treatment can ameliorate clinical symptoms, control tumor growth, and reduce growth hormone levels in patients with pituitary adenomas. It is a viable option for patients with residual tumors after surgery, those unable to tolerate surgery, or those with persistently elevated growth hormone levels and unrelieved symptoms postoperatively. However,

radiation-induced brain injury (RIBI) is a neurologically damaging condition that can occur at any time following radiotherapy for head and neck tumors, leading to cerebral edema, demyelination, and necrosis, with symptoms primarily manifesting as headaches, memory impairment, and cognitive decline⁽²²⁾. To clarify the efficacy and safety of Gamma Knife treatment, we conducted this retrospective study, aiming to provide data references for improving patients' quality of life. The study compares, for the first time, the treatment outcomes of patients previously treated with surgery and those preferred to receive gamma knife therapy, and analyses the factors affecting tumor control and post-treatment complications, providing physicians with a greater basis for clinical decision-making.

MATERIALS AND METHODS

Study population

This retrospective analysis reviewed the clinical data of 446 patients with pituitary adenomas treated with Gamma Knife at the Daizhuang Hospital Gamma Knife center in Shandong province between January 2012 and January 2023. Among them, 123 patients had complete follow-up data (12 months), including records of disease progression, follow-up imaging, and endocrine assessments. Patients were divided into two groups based on whether they underwent surgical treatment before Gamma Knife therapy: the postoperative Gamma Knife treatment group (postoperative group) and the primary Gamma Knife treatment group (primary group).

This study posed a low risk to the study participants and no formal ethical approval was given, but the entire study process followed ethical principles and the data were anonymized.

Inclusion and exclusion criteria

Inclusion criteria: (1) Patients diagnosed with pituitary adenomas based on clinical symptoms, endocrine, and imaging examinations; (2) Accurate records of surgical treatment history; (3) Complete endocrinological and imaging-related examination data.

Exclusion Criteria: (1) Patients with concomitant other endocrine or metabolic diseases; (2) Patients receiving concomitant medication therapy; (3) Patients undergoing reoperation or radiotherapy during the follow-up period; (4) Patients with recurrent pituitary adenomas.

Pre-treatment clinical information

Endocrine parameters included prolactin (PRL), adrenocorticotrophic hormone (ACTH), cortisol (PTF), growth hormone (GH), luteinizing hormone (LH), follicle-stimulating hormone (FSH), E2, and testosterone levels. Visual field impairment was

graded based on the Visual Field Index (VFI), with normal VFI being 100%. Imaging parameters included axial, coronal, and enhanced MRI sequences. Knosp grading (0 to 4) was conducted based on the tumor's contact with the cavernous sinus and the carotid artery siphon⁽²³⁾.

Gamma Knife treatment

Patients underwent local anesthesia and were fitted with a Leksell G-type localization head frame (Elekta Instruments AB, Stockholm, Sweden). Magnetic Resonance Imaging (MRI) scans (Siemens, Germany, Erlangen) were performed in the axial and coronal planes to precisely delineate the lesion and surrounding critical structures. Treatment planning was conducted using Gamma-TPS software (Pinnacle TPS v. 8.0 d; Philips Radiation Oncology Systems, Milpitas, CA), with multiple target points designed using 4mm, 8mm, and 14mm collimators, and dose gradient lines set at 50%. Peripheral doses ranged from 14 to 30 Gy, while central doses ranged from 28 to 60 Gy. Additionally, efforts were made to ensure that doses to the optic nerves and optic chiasm were kept below 9 Gy. Treatment was delivered using the OUR-XGD rotary Gamma Knife (Shenzhen Oreworld International Science and Technology Development, Shenzhen, Guangdong Province, China). The interface of the TPS software is shown in figure 1.

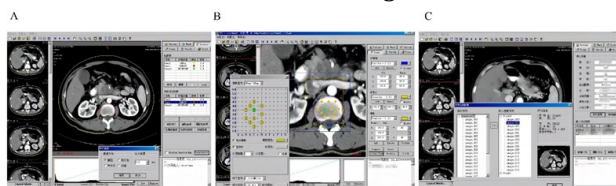


Figure 1. Development of Gamma Knife treatment plan based on MRI images (A. Data management and configuration patient image interface; B. Profile definition and 3D reconstruction interface; C. Treatment plan design and dose display)

The following sequences were used for cranial MRI scans. 1) Conventional T1 and T2-weighted images: These sequences are typically employed to delineate anatomical structures and tissue characteristics. T1-weighted images exhibit high signal intensity for cerebrospinal fluid, fat, and white matter, while T2-weighted images depict high signal intensity for cerebrospinal fluid and gray matter. 2) T1-weighted 3D MP-RAGE sequence: This high-resolution three-dimensional T1-weighted sequence provides clearer anatomical information, particularly suitable for evaluating small anatomical structures and lesions. 3) Diffusion-weighted imaging (DWI): This sequence detects the diffusion of water molecules within tissues, aiding in the assessment of microstructure and damage to brain tissue, commonly used in the diagnosis of stroke, tumors, and other conditions. 4) Time-of-flight MR angiography (TOF-MRA): This sequence generates images by utilizing the spin motion of blood, thereby

displaying the distribution and morphology of intracranial and cervical arterial vessels. It assists in evaluating vascular abnormalities and blood flow conditions. In all cases, radiological assessments were performed by independent neuroradiologists, ensuring professional and accurate evaluation of the MRI imaging results, providing crucial evidence for clinical diagnosis and treatment.

Follow-up protocol

Patients without adverse reactions after Gamma Knife treatment were followed-up at 1, 3, 6, and 12 months post-treatment. Follow-up primarily consisted of plain and enhanced MRI scans, along with endocrine and ophthalmological assessments to evaluate visual acuity. Clinical status changes were documented, and tumor volumes were calculated using gamma-plan dose planning system based on imaging results. Symptomatic treatment and relevant diagnostic and therapeutic interventions were administered if patients experienced disease progression or severe complications.

Efficacy criteria

Efficacy criteria for pituitary adenoma treatment included: (1) Tumor shrinkage: disappearance of the tumor or a reduction in tumor volume >10%; (2) Tumor stability: no change in tumor volume or a change <10%; (3) Tumor enlargement: an increase in tumor volume >10%. Tumor shrinkage and stability were defined as tumor control, while tumor enlargement indicated tumor progression.

Statistical analysis

Data were analyzed using IBM SPSS 20.0 statistical software. Continuous variables were presented as means or medians with ranges, while categorical variables were presented as frequencies and percentages. The chi-square test was used for categorical variable analysis. Univariate regression analysis was conducted to identify factors influencing prognosis and pituitary function, with odds ratios (ORs) and 95% confidence intervals calculated for relevant factors. Variables with significance ($p < 0.15$) in univariate analysis were further analyzed using binary logistic regression. A p -value < 0.05 was considered statistically significant.

RESULTS

Study population

This retrospective study included a total of 123 patients with pituitary adenomas (68 males and 55 females), as shown in table 1. Among them, 51 patients had previously undergone surgical treatment (postoperative group), while 72 patients were treated with gamma knife therapy as the initial choice (first-choice group). There were no statistically significant differences between the

postoperative group and the first-choice group in terms of gender ($P=0.943$), microadenoma quantity ($P=0.722$), macroadenoma quantity ($P=0.726$), giant adenoma quantity ($P=0.951$), adenoma classification ($P=0.790$), endocrine function ($P=0.977$), GH levels ($GH \leq 20$: $P=0.750$; $20 < GH \leq 40$: $P=0.009$; $GH > 40$: $P=0.145$), visual field defects ($P=0.835$), and MRI/CT imaging results ($P=0.835$) ($P > 0.05$). However, there was a statistically significant difference in age between the postoperative group and the first-choice group ($P=0.015 < 0.05$).

Table 1. General characteristics of included patients.

	Postoperative group (n=51)	Preferred group (n=72)	P value
Sex			0.943
Male	28	40	
Female	23	32	
Age	43.61±8.93	44.94±10.35	0.015
Adenoma size			
Microadenoma	12	15	0.722
Macroadenoma	31	46	0.726
Giant Adenoma	8	11	0.951
Classification of Adenomas			0.790
Functional	40	56	
Non-functional	11	16	
Endocrine function			0.977
Normal	36	51	
Abnormal	15	21	
Growth hormone (GH) (ng/ml)			
≤20	17	26	0.750
20<GH≤40	29	33	0.009
>40	5	13	0.145
Visual field defect			
Mild	15	30	0.164
Moderate	30	36	0.415
Severe	6	6	0.527
Imaging			0.835
Invasive	21	31	
Non-invasive	30	41	
knops' classification			
0	21	29	0.920
1	9	12	0.887
2	11	17	0.790
3	7	9	0.842
4	4	5	0.850
Median tumor volume (ml)	2.9(0.9-46.6)	2.1(0.2-50.4)	0.312

Values are presented as mean ± standard deviation or number of patients. Growth hormone :GH;

We provide MRI images of a patient before and after gamma knife treatment (figure 2). This patient was a 56-year-old male and the MRI results showed that the gamma knife treatment showed good clinical benefit.

Follow-up conducted to assess treatment efficacy

Any occurrence of tumor progression during any follow-up period was recorded as tumor progression. Among the postoperative group, there were 8 cases of pituitary adenoma progression, while in the

first-choice group, there were 4 cases of pituitary adenoma progression. In the postoperative group, there were 43 cases of pituitary adenoma control, including 30 cases of tumor reduction and 13 cases of tumor stabilization. In the first-choice group, there were 68 cases of pituitary adenoma control, including 48 cases of tumor reduction and 20 cases of tumor stabilization. The difference in tumor progression between the two groups was not statistically significant ($P=0.062$).

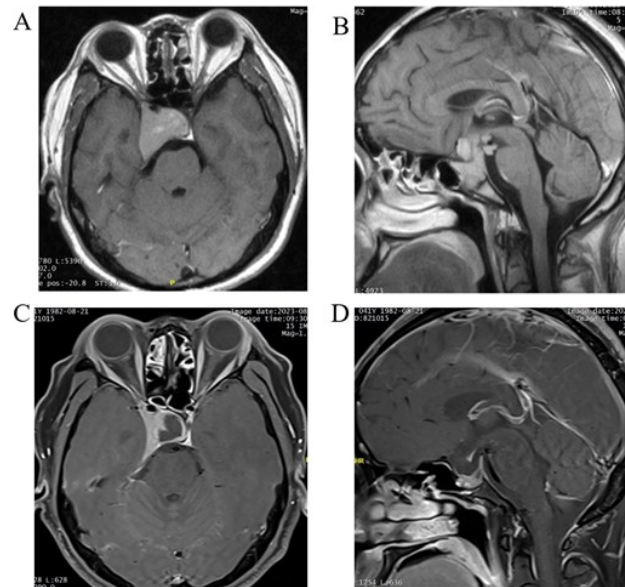


Figure 2. MRI contrast images of the patient before and after gamma knife treatment (A-B: MRI images of the patient before treatment; C-D: MRI images of the patient after treatment)

Table 2. Prognosis of pituitary adenoma patients after treatment.

	Postoperative group (n=51)	Preferred group (n=72)
Tumor progress	8	4
Tumor control	43	68
Tumor shrinkage	30	48
Tumor stabilization	13	20

Single factor analysis and multifactor analysis

The results of the univariate analysis of pituitary adenoma progression (table 3) indicate that tumor volume ($P=0.018$, $OR=1.174$, 95% CI: 0.254-1.670), tumor invasion ($P=0.003$, $OR=0.987$, 95% CI: 0.149-2.513), and marginal dose ($P=0.015$, $OR=0.872$, 95% CI: 0.448-4.191) are predictive factors for tumor progression. The results of the multivariate analysis show that tumor volume ($P=0.034$, $OR=1.071$, 95% CI: 0.121-5.206) and tumor invasion ($P=0.005$, $OR=0.233$, 95% CI: 0.202-0.392) are predictive factors for tumor progression. The control rates for patients with a marginal dose greater than or equal to 16 Gy were 95.9%, those with a dose greater than or equal to 18 Gy were 100%, and those with a dose greater than or equal to 20 Gy were 100%. This suggests that increasing the marginal dose during the treatment of pituitary adenomas results in more

significant efficacy.

Table 3. Univariate and multivariate analysis of predictors for pituitary adenoma progression.

Single factor analysis				
Influencing factors	standard error	deviation	OR(95%CI)	P-value
Gender	8.239	-5.717	0.205(0.037-1.234)	0.055
Treatment	3.291	-0.032	1.394(1.167-2.467)	0.672
Age	0.273	<0.001	0.977(-0.081-1.023)	0.432
Knosp classification	2.227	0.302	1.131(0.518-1.542)	0.527
Marginal Dose	0.116	-0.019	0.872(0.448-4.191)	0.015
MRI/CT Imaging - Invasion	1.245	-0.159	0.987(0.149-2.513)	0.003
Adenoma volume	0.331	-0.040	1.174(0.254-1.670)	0.018
multifactor analysis				
Imaging - Invasion	7.994	-3.265	0.233(0.202-0.392)	0.005
Adenoma volume	0.121	-0.034	1.071(0.121-5.206)	0.034
Marginal Dose	0.156	-0.026	0.965(0.157-1.332)	0.846

DISCUSSION

With the advancement of Gamma Knife technology and imaging techniques, the efficacy of Gamma Knife treatment for pituitary adenomas has been increasingly recognized by neurosurgeons, and numerous reports have demonstrated its effectiveness (24). Our study results show no statistically significant difference in efficacy between patients who previously underwent surgical treatment and those who underwent Gamma Knife treatment as the initial choice for pituitary adenomas. This suggests that Gamma Knife treatment is an effective option for treating pituitary adenomas, regardless of whether patients have undergone prior surgical treatment.

Previously, scholars believed that radiation therapies such as Gamma Knife could have adverse effects on patients' quality of life, such as affecting cognitive function. However, recent studies suggest that Gamma Knife can be used alone or as an adjunct for the treatment of pituitary adenomas, with research results indicating that Gamma Knife has no detrimental effect on cognitive function (25,26). Tooze *et al.* published two prospective studies in 2012 and 2018, respectively, involving 65 patients with pituitary adenomas who underwent Gamma Knife treatment. The results of both studies confirmed that stereotactic Gamma Knife radiation therapy had no significant impact on the cognitive function of patients with pituitary adenomas (27). Another study evaluated the efficacy of radiation therapy in 84 patients with pituitary adenomas, of which 45 underwent endonasal endoscopic surgery alone, and 39 received adjuvant radiation therapy following surgery. The results suggested that radiation therapy had no adverse effects on the cognitive function

(verbal memory and executive function) of patients with pituitary adenomas (28). Brummelman *et al.* conducted a study in 2012 involving 75 patients with non-functioning pituitary adenomas. They divided the patients into a radiotherapy group (30 cases, 1.8 Gy x 25 times = 45 Gy) and a non-radiotherapy group (45 cases). Among the radiotherapy group, three different subgroups were further categorized based on different techniques (10 cases with three-field irradiation, 15 cases with four-field irradiation, and 5 cases with five-field irradiation). All subjects underwent memory and executive function assessments. The results indicated that there was no significant difference in cognitive function between patients receiving three-field, four-field, or five-field techniques and those in the non-radiotherapy group. Our study results show no statistically significant difference in efficacy between postoperative radiotherapy and radiotherapy alone, and no significant cognitive impairment was observed in patients, consistent with previous studies.

Currently, there are many studies on predictive factors for the progression of pituitary adenomas. The main factors for progression include tumor volume, invasiveness, and extent of surgical resection (29). Zhang *et al.* retrospectively analyzed data from 121 patients with pituitary adenomas who underwent Gamma Knife treatment after surgical resection (30). The results showed that the rate of total tumor resection was an effective way to prevent recurrence of pituitary adenomas, and tumor invasiveness was an independent risk factor for recurrence. Our study results show that tumor invasiveness and tumor volume are risk factors affecting patient prognosis, consistent with Zhang *et al.*'s study. Another clinical study by Hsu showed that patients with high proliferating cell nuclear antigen (PCNA) index had a higher tumor progression rate after treatment. The results of Li *et al.*'s study suggested that Ki-67 could be used as an indicator to judge the invasiveness of pituitary adenomas, and it was positively correlated with tumor volume (31). Our study did not involve PCNA index measurement or cytokine assessment, which will be improved in further research. In addition to predictive factor analysis, some scholars have used radiomics to construct regression equations for pituitary adenomas, suggesting that volume fraction and ratio constants are features to distinguish pituitary adenoma progression, with sensitivities and specificities of 94.4% and 90.6%, respectively (32). The above studies suggest that incorporation of radiomics-based regression equations may further improve the accuracy of prediction, thus highlighting the importance of volumetric parameters in monitoring tumor progression. In conclusion, the evolving treatment of pituitary adenomas highlights the need for a personalized approach combining surgical, radiological and predictive strategies to

optimize patient prognosis and quality of life.

This study has certain limitations. Firstly, it is a retrospective study from a single treatment center. Secondly, we did not accurately record the surgical methods of the postoperative group (total resection/partial resection), which may be a factor influencing the progression of pituitary adenomas. In the next step of our research, we will design a prospective study to accurately record various information of the enrolled subjects and enrich the types of examination items.

CONCLUSION

Gamma Knife treatment has a stable effect on controlling pituitary adenomas. Individualized treatment plans should be developed based on the specific conditions and needs of patients during clinical treatment.

ACKNOWLEDGEMENTS

The authors declare that no commercial or financial relationships existed during the course of the study that could be perceived as a potential conflict of interest.

Conflicts of interest: The authors declare that the study was conducted in the absence of any business or financial relationship that could be interpreted as a potential conflict of interest.

Authors' contributions: J.S. designed and contributed to the research idea. Y.W. carried out the data collection and data analysis. Y.G. and Y.W. wrote the first draft of the article. J.S. reviewed the first draft. All authors approved the final manuscript.

Ethical Considerations: This was a retrospective data analysis study that used clinical data from Shandong Daizhuang Hospital (Shandong Province, China) but was not approved by a specialized ethical review board (IRB). We ensure that all patients' private information was kept strictly confidential and anonymized during data analysis and presentation of results. The research team strictly adhered to the basic principles of medical ethics and respected the rights of the patients. Despite the lack of ethical review, we will do our best to ensure the transparency and scientific integrity of the study and the protection of patient privacy.

Funding: This study was supported by no funding.

REFERENCES

- Nguyen MT and Lavi E (2015) Pituitary adenoma-neuronal choristoma is a pituitary adenoma with ganglionic differentiation. *Exp Mol Pathol*, **99**(3): 628-31.
- Feigl GC, Pistracher K, Berghold A, et al. (2010) Pituitary insufficiency as a side effect after radiosurgery for pituitary adenomas: the role of the hypothalamus. *J Neurosurg*, **113** Suppl: 153-59.
- Tsukamoto T and Miki Y (2023) Imaging of pituitary tumors: an update with the 5th WHO Classifications-part 1. Pituitary neuroendocrine tumor (PitNET)/pituitary adenoma. *Jpn J Radiol*, **41**(8): 789-806.
- Karavitaki N (2012) Prevalence and incidence of pituitary adenomas. *Ann Endocrinol (Paris)*, **73**(2): 79-80.
- Yamanaka R, Abe E, Sato T, et al. (2017) Secondary intracranial tumors following radiotherapy for pituitary adenomas: A systematic review. *Cancers (Basel)*, **9**(8): 103.
- Ogra S, Nichols AD, Stylli S, et al. (2014) Visual acuity and pattern of visual field loss at presentation in pituitary adenoma. *J Clin Neurosci*, **21**(5): 735-40.
- Pereira-Neto A, Borba AM, Mello PA, et al. (2010) Mean intrasellar pressure, visual field, headache intensity and quality of life of patients with pituitary adenoma. *Arq Neuropsiquiatr*, **68**(3): 350-4.
- Simander G, Eriksson PO, Lindvall P, et al. (2022) Intrasellar pressure in patients with pituitary adenoma - relation to tumour size and growth pattern. *BMC Neurol*, **22**(1): 82.
- Yavropoulou MP, Tsoli M, Barkas K, et al. (2020) The natural history and treatment of non-functioning pituitary adenomas (non-functioning PitNETs). *Endocr Relat Cancer*, **27**(10): R375-r390.
- Jha S and Kumar S (2009) TSH secreting pituitary adenoma. *J Assoc Physicians India*, **57**: 537-9.
- Cossu G, Daniel RT, Pierzchala K, et al. (2019) Thyrotropin-secreting pituitary adenomas: a systematic review and meta-analysis of postoperative outcomes and management. *Pituitary*, **22**(1): 79-88.
- Sathyakumar R, Chacko G (2020) Newer concepts in the classification of pituitary adenomas. *Neurol India*, **68**(Suppl): S7-s12.
- Mooney MA, Hardesty DA, Sheehy JP, et al. (2017) Rater Reliability of the Hardy Classification for Pituitary Adenomas in the Magnetic Resonance Imaging Era. *J Neurol Surg B Skull Base*, **78**(5): 413-8.
- Li P, Zhang D, Ma S, et al. (2021) Consistency of pituitary adenomas: Amounts of collagen types I and III and the predictive value of T2WI MRI. *Exp Ther Med*, **22**(5): 1255.
- Kim EH, Oh MC, Chang JH, et al. (2018) Postoperative Gamma Knife Radiosurgery for Cavernous Sinus-Involving Growth Hormone-Secreting Pituitary Adenomas. *World Neurosurg*, **110**: e534-e45.
- Elson A, Bovi J, Kaur K, et al. (2014) Effect of treatment modality on the hypothalamic-pituitary function of patients treated with radiation therapy for pituitary adenomas: hypothalamic dose and endocrine outcomes. *Front Oncol*, **4**: 73.
- Astafyeva LI, Kadashev BA, Sidneva YG, et al. (2020) Pituitary microadenomas - current diagnostic and treatment methods. *Zh Vopr Neirokhir Im N N Burdenko*, **84**(2): 110-20.
- Iida H, Komagata T, Tanaka H, et al. (2021) Novel platform for predicting drug effects in patients with acromegaly: Translational exposure-response evaluation of growth hormone-inhibitory effect of octreotide after growth hormone-releasing hormone stimulation. *J Pharmacol Exp Ther*, **379**(3): 400-8.
- Chen J, Liu H, Man S, et al. (2021) Endoscopic vs. microscopic transphenoidal surgery for the treatment of pituitary adenoma: A meta-analysis. *Front Surg*, **8**: 806855.
- Loeffler JS and Shih HA (2011) Radiation therapy in the management of pituitary adenomas. *J Clin Endocrinol Metab*, **96**(7): 1992-2003.
- Lee JH, Kim IY, Jung S, et al. (2023) Two-day fraction Gamma Knife radiosurgery for large brain metastasis. *J Korean Neurosurg Soc*, **67**(5): 560-567.
- Wang XF, Zhang S, Ye YH, et al. (2012) Clinicopathologic features of delayed radiation-induced brain injury after radiotherapy for brain tumor. *Zhonghua Bing Li Xue Za Zhi*, **41**(4): 224-8.
- Mooney MA, Hardesty DA, Sheehy JP, et al. (2017) Interrater and intrarater reliability of the Knosp scale for pituitary adenoma grading. *J Neurosurg*, **126**(5): 1714-9.
- Li P, Ren HB, Zhang ZL, et al. (2013) [Control of tumor with gamma knife in patients with pituitary adenomas]. *Sichuan Da Xue Xue Bao Yi Xue Ban*, **44**(3): 458-61.
- Kandregula S and Guthikonda B (2023) Gamma Knife radiosurgery. *Neurol India*, **71**(Suppl): S1.
- Tripathi M, Jani P, Bhatta R, et al. (2023) Development, Validation, and Impact of Patient Information Booklet for Gamma Knife Radiosurgery. *Neurol India*, **71**(Suppl): S224-s9.
- Honegger J, Nasi-Kordhishiti I, Giese S (2019) Pituitary adenomas. *Nervenarzt*, **90**(6): 568-77.
- Brummelman P, Elderson MF, Dullaart RP, et al. (2011) Cognitive functioning in patients treated for nonfunctioning pituitary macroadenoma and the effects of pituitary radiotherapy. *Clin Endocrinol (Oxf)*, **74**(4): 481-7.
- Sanmillán JL, Torres-Díaz A, Sánchez-Fernández JJ, et al. (2017) Radiologic predictors for extent of resection in pituitary adenoma surgery. A single-center study. *World Neurosurg*, **108**: 436-46.
- Zhang Y (2020) Risk factor analysis of postoperative recurrence of pituitary adenomas and experimental study of PVT1 in the progression of pituitary adenomas Ph.D., *Chinese People's Liberation Army Medical University, China*.
- Bălinișteanu B, Cîmpean AM, Ceașu AR, et al. (2017) High Ki-67 expression is associated with prolactin secreting pituitary adenomas. *Bosn J Basic Med Sci*, **17**(2): 104-8.
- Zhang Y, Chen C, Tian Z, et al. (2019) Differentiation of pituitary adenoma from Rathke cleft cyst: Combining MR image features with texture features. *Contrast Media Mol Imaging*, **2019**: 6584636.