

# Application value of low-dose computed tomography combined with serum tumor markers in diagnosis of early non-small cell lung cancer

R. Xu<sup>1</sup>, W. Xu<sup>1</sup>, D. Liu<sup>2#</sup>, S. Pan<sup>3#</sup>, J. Zhu<sup>2</sup>, Y. Shen<sup>4</sup>, C. Wang<sup>2\*</sup>, H. Shen<sup>1\*</sup>

<sup>1</sup>Department of Oncology, Affiliated People's Hospital of Jiangsu University, Zhenjiang City, Jiangsu, Province China

<sup>2</sup>Department of Thoracic Surgery, Shandong Public Health Clinical Center (Shandong Provincial Chest Hospital), Shandong Province, China

<sup>3</sup>Department of Laboratory Medicine, Shengli Oilfield Central Hospital, Shandong Province, China

<sup>4</sup>Department of Respiratory Medicine, Shandong Public Health Clinical Center (Shandong Provincial Chest Hospital), Shandong Province, China

## ► Original article

### \*Corresponding author:

Huiling Shen, MD. &

Cheng Wang, MD.,

### E-mail:

Shenhui0826@163.com;

qie85615604@163.com

Received: May 2024

Final revised: June 2024

Accepted: July 2024

Int. J. Radiat. Res., January 2025;  
23(1): 77-81

DOI: 10.61186/ijrr.23.1.77

**Keywords:** Computed tomography, early diagnosis, non-small cell lung cancer, serum; tumor markers.

#The two authors contributed equally to this study.

## ABSTRACT

**Background:** We aimed to explore the application value of low-dose computed tomography (LDCT) combined with serum tumor markers in the diagnosis of early non-small cell lung cancer (NSCLC). **Materials and Methods:** The clinical data of 176 patients suspected of early NSCLC screened from March 2017 to April 2022 were retrospectively collected. The diagnostic values of LDCT, serum tumor markers, and LDCT combined with serum tumor markers for early NSCLC were explored. **Results:** There were diverse imaging characteristics of early NSCLC, dominated by solid lesions, followed by part-solid nodules, but non-solid nodules were rare. The levels of serum carcinoembryonic antigen, cytokeratin 19 fragment antigen 21-1 and neuron specific enolase in patients with early NSCLC were higher than those in patients with benign lesions ( $P<0.05$ ). LDCT combined with serum tumor markers had a higher Kappa coefficient than LDCT and serum tumor markers, indicating that it had the highest consistency with pathological diagnosis results ( $P<0.05$ ). Both the sensitivity and accuracy of LDCT combined with serum tumor markers were higher than those of LDCT and serum tumor markers ( $P<0.05$ ). **Conclusion:** LDCT combined with serum tumor markers can significantly improve the diagnostic sensitivity and accuracy for early NSCLC and the consistency with pathological diagnosis results, and effectively reduce misdiagnosis and missed diagnosis.

## INTRODUCTION

As the most common type of lung cancer, non-small cell lung cancer (NSCLC) generally has no obvious symptoms in the early stage, and lung parenchymal lesions have no obvious specificity, so missed diagnosis and misdiagnosis are easily caused, and most patients have been in the mid-late stage when diagnosed <sup>(1)</sup>. As a result, patients have a poor prognosis and a low survival rate. Besides, the asymptomatic survival rate of patients with adenocarcinoma *in situ* and microinvasive adenocarcinoma who receive early diagnosis and radical surgery is almost up to 100% <sup>(2)</sup>. Therefore, early screening and diagnosis are highly recommended to effectively improve the prognosis of patients and to reduce the mortality rate.

Chest spiral computed tomography (CT) is

considered as the most effective examination method for asymptomatic or early lung cancer <sup>(3)</sup>. Generally, the definition of CT image is positively correlated with radiation dose. However, long-term exposure to high-dose radiation can easily cause harm to the human body, and may lead to cataract, fetal malformation, sterility, and even leukemia and other malignancies <sup>(4)</sup>. Later, low-dose CT (LDCT) was proposed and applied in early screening. The effective dose of LDCT is less than 1.5 mSv, far lower than that of routine CT <sup>(5)</sup>. Currently, LDCT is the only imaging screening method able to reduce the mortality of lung cancer <sup>(6)</sup>. In addition, it lowers the dose while ensuring high sensitivity, thus reducing radiation damage to the human body and medical expenses <sup>(7)</sup>. Kalinke *et al.* found that LDCT produced images whose quality reached the diagnostic standard while reducing the radiation dose, and the

shortened total scanning time helped prolong the service life of CT tubes and decrease the examination cost<sup>(8)</sup>. Reich showed that there were no significant differences in the detection rate of early lung cancer and the image quality score between LDCT and conventional-dose CT<sup>(9)</sup>. In addition, normal lung tissues have a high-contrast structure and contain a large amount of gas, thus reducing the X-ray absorption rate<sup>(10)</sup>. Therefore, LDCT is highly suitable for the screening and diagnosis of early asymptomatic lung cancer.

Serum tumor markers have diagnostic values for NSCLC<sup>(11)</sup>. CEA is highly expressed in malignancies such as lung cancer and closely related to tumor growth and metastasis, which is currently the most widely-used serum tumor marker<sup>(12)</sup>. Additionally, CYFRA21-1 has a high diagnostic value for a variety of types of lung cancers, which can effectively reflect the changes in tumor volume and predict the chemotherapy effect on patients in the advanced stage<sup>(13)</sup>. Moreover, NSE secreted by neuroendocrine tissues and neurogenic cells is a protease considered as an ideal tumor marker for small cell lung cancer. Its level also rises in the case of NSCLC, which can predict the prognosis of patients<sup>(14)</sup>.

Until now, there are few reports on the diagnostic value of LDCT combined with serum tumor markers for NSCLC.

In the present study, therefore, the pathological, imaging and serological data of 176 patients suspected of NSCLC were retrospectively analyzed, aiming to assess the diagnostic value of LDCT combined with serum tumor markers for early NSCLC detection.

## MATERIALS AND METHODS

### General data

The clinical data of 176 patients suspected of early NSCLC screened in our hospital from March 2017 to April 2022 were retrospectively collected. This study has been reviewed and approved by the medical ethics committee of our hospital on March 4th, 2017 (approval No. SPCH201703002). There were 101 males and 75 females aged ( $60.26 \pm 7.38$ ) years old on average.

The inclusion criteria were as follows: patients definitely diagnosed by histology and cytology after fiberoptic bronchoscopy, needle biopsy or tissue specimens surgically resected; first-diagnosed early cases without receiving any treatment before this study; those with complete clinical data; those undergoing LDCT and serum tumor marker detection; those who and whose families signed the informed consent.

The exclusion criteria were as follows: patients with other types of lung cancer or complicated with malignancies of other organs; those with obvious damage or severe dysfunction of vital organs; those

with consciousness or mental disorders.

### LDCT and image analysis

The patient received breathing training prior to the scan, and then lay on the CT bed on the back, followed by continuous scan using 64-row 128-slice CT scanner (GE Healthcare, USA) under plain scan and volume scan modes from the superior aperture of thorax to the bilateral adrenal glands during a single end-inspiratory breath-hold. Iohexol was utilized as the contrast agent (GE Healthcare, USA). The scanning parameters were set as follows: tube voltage: 100-120 kV, fixed or automatic tube current modulation, tube current: 30-50 mAs, slice thickness: 5.0 mm, reconstruction slice thickness and interval: 1.0 mm, FOV: 350 mm/350 mm, matrix: 512/512, filter function was reconstructed using lung algorithm and standard algorithm, and the effective scanning dose should be less than 1.5 mSv.

After the scan, the images were transferred to the image workstation of the CT scanner for post-processing, and independently and blindly interpreted by two experienced chest imaging diagnosticians. The assessment results were based on the principle of consistency. In the case of disagreement, the images were interpreted and analyzed by a third senior physician.

### Detection of serum tumor markers

Within 2 weeks after LDCT and before treatment, 5 mL of fasting peripheral venous blood was drawn from each patient, and the levels of serum carcinoembryonic antigen (CEA, normal range: 0-4.3 ng/mL), cytokeratin 19 fragment antigen 21-1 (CYFRA21-1, normal range: 0-2.17 ng/mL) and neuron specific enolase (NSE, normal range: 0-15.2 ng/mL) were detected using Cobas 6000 chemiluminescence meter (Roche, Switzerland) and supporting kits strictly according to the manufacturer's instructions (Thermo Fisher Scientific, USA). One or more serum tumor markers exceeding the normal range were considered positive, while all tumor markers within the normal range were considered negative.

### Detection of serum tumor markers combined with LDCT

If any one of serum tumor markers (CEA, CYFRA21-1 and NSE) and LDCT showed positive result, the patient was diagnosed with NSCLC.

### Diagnostic indices

True positive means that the subject has a disease and is actually determined as positive, while false positive means that the subject has no disease but is determined as positive. True negative means that the subject has no disease and is actually determined as negative, while false negative means that the subject has a disease but is determined as negative. Sensitivity is also known as true positive rate:

sensitivity = true positive cases / (true positive cases + false negative cases). Specificity is also known as true negative rate: specificity = true negative cases / (true negative cases + false positive cases). Accuracy = (true positive cases + true negative cases) / (true positive cases + true negative cases + false positive cases + false negative cases)  $\times 100\%$ .

### Statistical analysis

SPSS 21.0 software (IBM Inc., USA) was used for statistical analysis. Numerical data were expressed as percentage [n (%)], and compared using the  $\chi^2$  test. Measurement data were expressed as mean  $\pm$  standard deviation ( $\bar{x} \pm s$ ), and compared using the independent-samples *t* test. The consistency was analyzed by the Kappa test. The Kappa coefficients of 0.41-0.60, 0.61-0.80 and 0.81-1.00 indicated moderate, high and markedly high consistency, respectively.  $\alpha=0.05$  was set as the test level, and  $P<0.05$  was considered statistically significant.

## RESULTS

### Pathological diagnosis results

Among the 176 suspected patients, there were 142 cases of early NSCLC, including 64 cases of squamous cell carcinoma and 78 cases of adenocarcinoma. Benign lesions were found in the remaining 34 cases, including 26 cases of inflammatory lesions and 8 cases of tuberculosis.

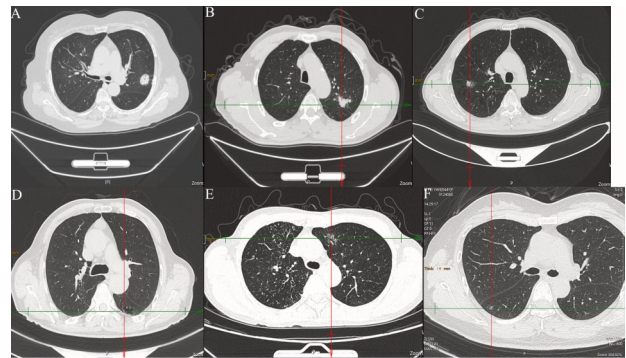
### LDCT imaging characteristics of patients with early NSCLC

Among the 142 cases of early NSCLC, there were 81 cases of solid lesions, including 59 cases of typical solid nodules, mainly manifested as solid nodules, with pleural traction, speculated sign and lobulated sign, and ventilated bronchial tubes or vacuoles in a few nodules. There were 12 cases of atypical nodules, in which one type had imaging characteristics of chronic inflammatory lesions or benign tumors, irregular shape, thick-long cord- and sharp angle-like changes, and no ventilated bronchial tubes inside, and the other type had no lobules and spicules but only shallow lobules with smooth edges. Additionally, there were 10 cases of irregular types, manifested as highly irregular non-nodular lesions, with ventilated bronchial tubes inside and cord-like shadow around, pleural traction or shrinkage.

Among the 55 cases of part-solid nodules, there were 34 cases of part-solid nodular type, manifested as uneven density inside the nodules and ground-glass opacity of unequal components, with ventilated bronchial tubes, vacuoles and pleural traction. There were 11 cases of part-solid cystic cavity type, *i.e.* part- or total-solid wall nodules manifested as irregular cystic wall thickening. Moreover, there were 10 cases of part-solid irregular type, similar to solid irregular lesions, but with ground-glass opacity at the edge.

The non-solid nodular lesions in the remaining 6 cases were manifested as pure ground-glass opacity with uneven density.

The diameter of tumors was 0.71-3.32 cm, with an average of  $(2.35 \pm 0.64)$  cm. The lesions were located in the superior lobe of left lung in 48 cases, inferior lobe of left lung in 31 cases, superior lobe of right lung in 32 cases, and inferior lobe of right lung in 25 cases. The representative LDCT images of different types of lesions are exhibited in figure 1.



**Figure 1.** LDCT imaging characteristics of patients with early NSCLC. **A:** Typical solid nodule; **B:** irregular solid nodule; **C:** part-solid nodule; **D:** part-solid cystic cavity type; **E:** part-solid irregular type; **F:** non-solid nodular lesion. LDCT: Low-dose computed tomography; NSCLC: non-small cell lung cancer.

### Levels of serum tumor markers in patients with early NSCLC

The levels of serum CEA, CYFRA21-1 and NSE in patients with early NSCLC were significantly higher than those in patients with benign lesions ( $P<0.001$ ) (table 1).

**Table 1.** Levels of serum tumor markers in patients with early NSCLC.

Pathological diagnosis	n	CEA (ng/mL, $\bar{x} \pm s$ )	CYFRA21-1 (ng/mL, $\bar{x} \pm s$ )	NSE (ng/mL, $\bar{x} \pm s$ )
NSCLC	142	$48.58 \pm 9.61$	$4.02 \pm 1.35$	$25.19 \pm 8.33$
Benign lesion	34	$3.02 \pm 0.73$	$1.31 \pm 0.52$	$9.58 \pm 2.67$
<i>t</i>		27.565	11.482	10.774
<i>P</i>		<0.001	<0.001	<0.001

CEA: Carcinoembryonic antigen; CYFRA21-1: cytokeratin 19 fragment antigen 21-1; NSCLC: non-small cell lung cancer; NSE: neuron specific enolase.

### Comparisons between different examination methods and pathological results

Among the 142 patients with early NSCLC, there were 119 positive cases and 23 negative cases by LDCT, 125 positive cases and 17 negative cases by tumor marker detection, and 137 positive cases and 5 negative cases by combined examination. Among the 34 patients with benign lesions, there were 8 positive cases and 26 negative cases by LDCT, 6 positive cases and 28 negative cases by tumor marker detection, and 4 positive cases and 30 negative cases by combined examination (table 2).

### Consistency between different examination methods and pathological results

LDCT combined with serum tumor markers had a



higher Kappa coefficient than those of LDCT and serum tumor markers, indicating that it had the highest consistency with pathological diagnosis results ( $P < 0.001$ ) (table 3).

**Table 2.** Comparisons between different examination methods and pathological diagnosis results.

Pathological diagnosis	n	LDCT		Tumor marker		Combined examination	
		Positive	Negative	Positive	Negative	Positive	Negative
NSCLC	142	119	23	125	17	137	5
Benign lesion	34	8	26	6	28	4	30

LDCT: Low-dose computed tomography; NSCLC: non-small cell lung cancer.

**Table 3.** Consistency between different examination methods and pathological diagnosis results.

Examination method	Kappa coefficient	95% confidence interval	P
LDCT	0.516	0.371 ~ 0.661	<0.001
Tumor marker	0.626	0.489 ~ 0.763	<0.001
Combined examination	0.838	0.735 ~ 0.941	<0.001

LDCT: Low-dose computed tomography.

### Diagnostic values of different examination methods

No significant difference was found in the specificity among the three examination methods ( $P = 0.445$ ). Both sensitivity and accuracy of LDCT combined with serum tumor markers were higher than those of LDCT and serum tumor markers ( $P = 0.002$  and  $0.001$ ) (table 4).

**Table 4.** Diagnostic values of different examination methods.

Examination method	Sensitivity (%)	Specificity (%)	Accuracy (%)
LDCT	119/142(83.80)	26/34(76.47)	145/176(82.39)
Tumor marker	125/142(88.03)	28/34(82.35)	153/176(86.93)
Combined examination	137/142(96.48) <sup>ab</sup>	30/34(88.24)	167/176(94.89) <sup>ab</sup>
$\chi^2$	12.523	1.619	13.410
P	0.002	0.445	0.001

LDCT: Low-dose computed tomography. a $P < 0.05$  vs. LDCT; b $P < 0.05$  vs. tumor markers.

## DISCUSSION

In this study, the levels of serum CEA, CYFRA21-1 and NSE in patients with early NSCLC were significantly higher than those in patients with benign lesions, being consistent with the results of previous literatures<sup>(12, 15)</sup>. Besides, we screened the subjects suspected of early NSCLC. The number of pathologically confirmed cases significantly increased compared with ordinary or high-risk populations, similar to the findings of a previous study<sup>(16)</sup>.

Zhang *et al.* found that the Kappa coefficient of serum tumor markers combined with CT was 0.765 in the diagnosis of peripheral lung cancer, higher than that of tumor markers (CEA, NSE and CYFRA21-1), squamous cell carcinoma antigen test or CT alone, and the combined examination had a higher

consistency with the pathological diagnosis results<sup>(17)</sup>. In addition, Chu *et al.* found in the feasibility analysis of the early diagnosis of lung cancer that the positive detection rate by LDCT combined with tumor markers was obviously higher than that by a single tumor marker (pleiotrophin, NSE, CYFRA21-1 or CEA) and combined examination of the 4 tumor markers<sup>(18)</sup>. Moreover, Jiang *et al.* confirmed that both the sensitivity and accuracy of positron emission tomography-CT combined with serum tumor markers were significantly higher than those of them alone in the detection of lung cancer<sup>(19)</sup>. Likewise, we herein found that the sensitivity and accuracy of LDCT combined with tumor markers were significantly higher than those of LDCT or tumor markers alone in the diagnosis of early NSCLC, and the combined examination results had the highest consistency with the pathological diagnosis results.

The advantage of combined detection may be attributed to the following reasons. The levels of serum tumor markers can be affected by a variety of factors, easily causing misdiagnosis and missed diagnosis<sup>(20)</sup>. The image quality and detection rate of LDCT are not reduced compared with those of conventional-dose CT, but the imaging characteristics of NSCLC are diverse, and solid lesions have more complicated manifestations, so the nature of most lesions can only be determined by the morphology<sup>(8)</sup>. Moreover, early lesions have small volumes and unobvious characteristics<sup>(21)</sup>.

In conclusion, LDCT combined with serum tumor markers can significantly improve the diagnostic sensitivity and accuracy for early NSCLC and the consistency with pathological diagnosis results, and effectively reduce misdiagnosis and missed diagnosis, so it is worthy of clinical popularization and application.

**Funding:** The study was not financially supported.

**Conflicts of interests:** The authors declare no conflict of interest.

**Ethical consideration:** This study has been reviewed and approved by the medical ethics committee of our hospital on March 4th, 2017 (approval No. SPCH201703002).

**Authors' contributions:** Ran Xu and Huilin Shen designed this study and significantly revised the manuscript; Jiankun Zhu, Yang Shen and Cheng Wang performed this study and drafted the manuscript.

## REFERENCES

1. Sarihan SÜ, Tunç S, İrem Z, Kahraman AY (2024) Stereotactic radiotherapy for brain metastases in patients with non-small cell lung cancer: CyberKnife-M6 experience. *Int J Radiat Res*, **22**(1): 117-124.
2. Chen H, Laba JM, Boldt RG, *et al.* (2018) Stereotactic ablative radiotherapy versus surgery in early lung cancer: a meta-analysis of propensity score studies. *Int J Radiat Oncol Biol Phys*, **101**(1): 186-194.
3. Passiglia F, Cinquini M, Bertolaccini L, *et al.* (2021) Benefits and

- harms of lung cancer screening by chest computed tomography: a systematic review and meta-analysis. *J Clin Oncol*, **39**(23): 2574-2585.
4. Jiang T, Ren S, Zhou C (2020) Multi-cancer blood testing combined with PET-CT: road for hope to screen for cancer and guide intervention. *Signal Transduct Target Ther*, **5**(1): 95.
  5. Gholizadeh-Ansari M, Alirezaie J, Babyn P (2020) Deep learning for low-dose CT denoising using perceptual loss and edge detection layer. *J Digit Imaging*, **33**(2): 504-515.
  6. O'Dowd EL and Ten Haaf K (2019) Lung cancer screening: enhancing risk stratification and minimising harms by incorporating information from screening results. *Thorax*, **74**(9): 825-827.
  7. Grover H, Ross T, Fuller E (2020) Implementation of targeted screening for lung cancer in a high-risk population within routine NHS practice using low-dose computed tomography. *Thorax*, **75**(4): 348-350.
  8. Kalinke L, Thakrar R, Janes SM (2021) The promises and challenges of early non-small cell lung cancer detection: patient perceptions, low-dose CT screening, bronchoscopy and biomarkers. *Mol Oncol*, **15**(10): 2544-2564.
  9. Reich JM (2006) Estimated impact of LDCT-identified stage IA non-small-cell lung cancer on screening efficacy. *Lung Cancer*, **52**(3): 265-271.
  10. Sivunen J, Piirilä P, Karlberg S, et al. (2020) Restriction of lung volumes but normal function of pulmonary tissue in mulibrey nanism. *Pediatr Pulmonol*, **55**(1): 122-129.
  11. Tokito T, Azuma K, Yamada K, et al. (2019) Prognostic value of serum tumor markers in patients with stage iii nscl treated with chemoradiotherapy. *In Vivo*, **33**(3): 889-895.
  12. Dal Bello MG, Filiberti RA, Alama A, et al. (2019) The role of CEA, CYFRA21-1 and NSE in monitoring tumor response to Nivolumab in advanced non-small cell lung cancer (NSCLC) patients. *J Transl Med*, **17**: 74.
  13. Qu T, Zhang J, Xu N, et al. (2019) Diagnostic value analysis of combined detection of Trx, CYFRA21-1 and SCCA in lung cancer. *Oncol Lett*, **17**(5): 4293-4298.
  14. Oya Y, Yoshida T, Uemura T, Murakami Y, Inaba Y, Hida T (2018) Serum ProGRP and NSE levels predicting small cell lung cancer transformation in a patient with ALK rearrangement-positive non-small cell lung cancer: A case report. *Oncol Lett*, **16**(4): 4219-4222.
  15. Yuan J, Sun Y, Wang K, et al. (2022) Development and validation of reassigned CEA, CYFRA21-1 and NSE-based models for lung cancer diagnosis and prognosis prediction. *BMC Cancer*, **22**(1): 686.
  16. Lv X, Cao J, Dai X, Rusidanmu A (2018) Survival rates after lobectomy versus sublobar resection for early-stage right middle lobe non-small cell lung cancer. *Thorac Cancer*, **9**(8): 1026-1031.
  17. Zhang Z, Yuan F, Chen R, et al. (2020) Dynamics of serum tumor markers can serve as a prognostic biomarker for Chinese advanced non-small cell lung cancer patients treated with immune checkpoint inhibitors. *Front Immunol*, **11**: 1173.
  18. Chu GCW, Lazare K, Sullivan F (2018) Serum and blood based biomarkers for lung cancer screening: a systematic review. *BMC Cancer*, **18**(1): 181.
  19. Jiang R, Dong X, Zhu W, et al. (2017) Combining PET/CT with serum tumor markers to improve the evaluation of histological type of suspicious lung cancers. *PLoS One*, **12**(9): e0184338.
  20. Rao S, Smith DA, Guler E, et al. (2021) Past, present, and future of serum tumor markers in management of ovarian cancer: a guide for the radiologist. *Radiographics*, **41**(6): 1839-1856.
  21. Padinharayil H, Varghese J, John MC, et al. (2023) Non-small cell lung carcinoma (NSCLC): Implications on molecular pathology and advances in early diagnostics and therapeutics. *Genes Dis*, **10**(3): 960-989.

