

# Efficacy of microwave ablation therapy for uterine fibroids

J. Zhao, W. Chen, C. Li, H. Xiao, Y. Jin, Y. Wang, J. Gao\*

Department of Obstetrics and Gynecology, Beijing Luhe Hospital, Capital Medical University, Beijing, China

## ABSTRACT

### ► Original article

#### \*Corresponding author:

Jie Gao, M.D.,

E-mail: [yjsjy1981@126.com](mailto:yjsjy1981@126.com)

Received: May 2024

Final revised: May 2024

Accepted: July 2024

Int. J. Radiat. Res., January 2025;  
23(1): 91-96

DOI: 10.61186/ijrr.23.1.91

**Keywords:** Uterine fibroids, leiomyoma, laparoscopy, microwave ablation.

**Background:** To investigate the efficacy of laparoscopic combined with microwave ablation therapy in treating multiple uterine fibroids and its impact on patients' quality of life. **Materials and Methods:** This study included a total of 100 patients with uterine fibroids, divided into a laparoscopic group (50 cases) and a laparoscopic combined with microwave ablation group (50 cases), treated with either laparoscopic surgery alone or laparoscopic combined with microwave ablation therapy. General information of the patients, MRI images before and after treatment, contrast-enhanced ultrasound before and after treatment, intraoperative blood loss, operation time, length of hospital stay, time to postoperative ambulation, VAS score, and ovarian function were collected and analyzed. **Results:** Compared with laparoscopic surgery alone, the laparoscopic combined with microwave ablation group had lower postoperative pain scores, less intraoperative blood loss, and faster postoperative recovery. There was no significant difference in ovarian function indicators after surgery compared with before surgery, indicating no difference in ovarian function and reserve between the two surgical methods. Additionally, the total effective rate of the combined treatment group reached 98%, significantly higher than the 92% in the laparoscopic group. Imaging analysis showed that the structure of surrounding tissues and vascular layout were restored closer to the normal state after combined treatment. **Conclusion:** Laparoscopic combined with microwave ablation therapy shows superior efficacy and safety in treating multiple uterine fibroids compared to laparoscopic surgery alone, making it an effective method for treating multiple uterine fibroids, worthy of further clinical promotion and application.

## INTRODUCTION

Uterine fibroids, also known as uterine leiomyomas, are among the most common benign tumors of the female reproductive system <sup>(1)</sup>. They typically occur within the uterine wall of women of reproductive age, resulting from abnormal growth of uterine smooth muscle cells <sup>(2,3)</sup>. While many patients with uterine fibroids may remain asymptomatic, in certain cases, they can cause a range of issues including but not limited to abnormal vaginal bleeding, abdominal distension, frequent urination, and infertility, thus impacting patients' quality of life and fertility <sup>(4,5)</sup>. The exact etiology of uterine fibroids remains incompletely understood, but research suggests a close association with elevated estrogen levels. Additionally, genetic factors, lifestyle, and dietary habits are also considered potential factors influencing the development of uterine fibroids.

Traditionally, treatment methods for uterine fibroids mainly include medication and surgical intervention. Medical treatment aims to alleviate symptoms and reduce the size of fibroids but cannot completely remove them and may lead to regrowth <sup>(6,7)</sup>. Surgical treatment methods include hysterectomy and myomectomy, which may significantly affect patients both physically and psychologically,

especially for women desiring to preserve fertility <sup>(8,9)</sup>. With advancements in medical technology, more minimally invasive treatment methods have been introduced into the management of uterine fibroids to reduce patient suffering and recovery time. Laparoscopy, as a minimally invasive surgical method involves accessing the abdominal cavity through small incisions, utilizing a camera and specialized instruments, has been widely employed for fibroid removal <sup>(10,11)</sup>. In recent years, microwave ablation technology, as an innovative treatment modality, has demonstrated great potential in treating uterine fibroids by directly destroying fibroid cells using high-frequency electromagnetic waves <sup>(12,13)</sup>.

Although both laparoscopic surgery and microwave ablation have shown advantages in treating uterine fibroids individually, research on their combined application in improving treatment efficiency, reducing postoperative recurrence rates, and preserving patients' fertility is still in its early stages. Therefore, exploring the efficacy of laparoscopic combined with microwave ablation therapy for multiple uterine fibroids is of great theoretical and practical significance for expanding treatment options for uterine fibroids and improving patients' quality of life.

This study investigates the novel combination of

laparoscopic surgery and microwave ablation therapy for the treatment of multiple uterine fibroids. By integrating these two minimally invasive techniques, this research aims to enhance treatment efficiency, minimize postoperative recurrence rates, and better preserve fertility compared to conventional methods. The innovative approach of combining laparoscopy with microwave ablation is expected to provide a comprehensive treatment solution, potentially setting a new standard in the management of uterine fibroids and significantly improving patient outcomes and quality of life.

## MATERIALS AND METHODS

### Study Subjects

A total of 100 patients with uterine fibroids who underwent treatment at our hospital from January 2021 to January 2023 were selected according to inclusion and exclusion criteria and divided into two groups: (1) Laparoscopic group (50 cases), undergoing laparoscopic myomectomy for multiple uterine fibroids, aged 29-50 years with a mean age of  $(41.42 \pm 4.39)$  years; (2) Combined group (50 cases), undergoing laparoscopic combined with microwave ablation for multiple uterine fibroids, aged 27-49 years with a mean age of  $(40.89 \pm 5.85)$  years, followed up for 1 year.

**Inclusion Criteria:** 1. Age >18 years, premenopausal females; 2. Multiple uterine fibroids; 3. No prior treatment for uterine fibroids; 4. Absence of intrauterine devices; 5. No acute infectious diseases such as acute pelvic inflammatory disease or vaginitis.

**Exclusion Criteria:** 1. Patients with single uterine fibroids or other types of non-fibroid uterine lesions; 2. Patients with severe heart, liver, kidney, or other major organ dysfunction; 3. Patients who have received other treatments for uterine fibroids recently (such as medical treatment, other types of surgical treatment, etc.); 4. Patients who refuse to participate in the study or cannot provide informed consent; 5. Patients with other reproductive system diseases that may affect the evaluation of treatment efficacy (such as ovarian tumors, cervical lesions, etc.); 6. Patients who are pregnant or planning to become pregnant during the study period; 7. Patients with malignant tumors inside or outside the uterus; 8. Patients prone to intraoperative or postoperative bleeding.

### Classification criteria for uterine fibroids

According to the International Federation of Gynecology and Obstetrics (FIGO), uterine fibroids are classified as follows: Type 0: Pedunculated submucosal fibroids.

Type I: Intramural fibroids without a pedicle,

expanding into the muscle layer  $\leq 50\%$ . Type II: Intramural fibroids without a pedicle, expanding into the muscle layer  $> 50\%$ .

Type III: Intramural fibroids located near the endometrial cavity, with the edge of the tumor  $\geq 5$  mm away from the endometrial layer. Type IV: Intramural fibroids located close to the endometrial layer, with the edge of the tumor  $< 5$  mm away from the endometrial layer. Type V: Fibroids penetrating all layers of the uterine muscle. Type VI: Fibroids protruding towards the serosa. Type VII: Fibroids completely located beneath the serosa (with a pedicle). Type VIII: Other special types or locations of fibroids (e.g., cervical, corneal, broad ligament fibroids).

### Treatment Methods

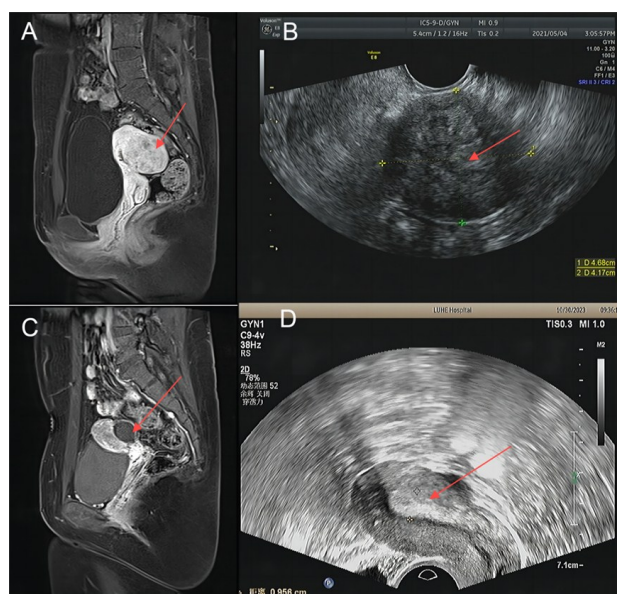
#### Laparoscopic Group

Laparoscopic uterine fibroid resection is done under general anesthesia. The patient was positioned with the head lower than the buttocks. An incision below the umbilicus allows insertion of an insufflation needle to create pneumoperitoneum at 12 mm Hg. A laparoscope is used to observe the fibroids. Trocars are inserted at the umbilicus, left side of the umbilicus, and lower abdomen on both sides. Bipolar electrocoagulation and ultrasonic knives are used. Oxytocin is injected around the fibroids, which are incised and resected. Hemostasis is achieved with electrocoagulation. The fibroids are removed in an endoscopic retrieval bag. The myometrium and tumor bed are sutured, anti-adhesion materials applied, and the pelvic cavity rinsed with saline. The gas is expelled, and the incisions are sutured.

#### Combined Group

After laparoscopic operation, ultrasound scanning (Philips EPIQ 7, Netherlands) of the lower abdomen is performed to select, locate, and determine the puncture site. An appropriate amount of coupling agent (Aquasonic 100, USA) is applied to the surface of the probe, and a sterile probe cover is applied. A puncture guide frame is installed. Under real-time ultrasound guidance, a microwave antenna is percutaneously inserted into the lesion. The microwave production for ablation is achieved using a commercially available microwave ablation system. The specific details are as follows: Microwave Ablation System: Commercial Brand Name: Covidien Microwave Ablation System; Manufacturer: Covidien; Country of Origin: USA; Microwave Wavelength: 2450 MHz (2.45 GHz). The number and length of microwave antennas inserted are determined based on the size of the lesion. For fibroids  $< 5$  cm or those with poor blood supply, one anterior pole microwave antenna with a length of 1.1 cm is inserted. For fibroids  $> 5$  cm or those with rich blood supply, two electrodes are inserted. Microwave output power is

set at 50 watts (W) or 60 W, and radiofrequency is set at 80-120 W (depending on the size of the fibroid and the blood supply status of the lesion) for ablation. During ablation, real-time ultrasound scanning is performed to monitor changes in echogenicity of the ablation zone and adjacent tissues. Microwave radiation is stopped when high echogenicity reaches the edge of the predetermined ablation zone. Echogenicity changes in the uterine cavity are monitored in real-time during ablation. Microwave radiation is stopped when high echogenicity flow is observed in the uterine cavity to prevent endometrial thermal injury. After ablation, the ablation effect is evaluated: color Doppler flow imaging (CDFI) is performed after microwave radiation ceases. Venous ultrasound is performed after the absence of color flow signals in the ablation zone. The range without contrast agent perfusion in the ablation zone is considered the effective ablation area. If there are still blood flow signals or contrast agent perfusion areas within the target of ablation, additional ablation should be performed immediately. After ablation, the cessation of microwave radiation is confirmed, and the microwave antenna is removed. Comparisons of patient images before and after microwave ablation therapy is shown in figure 1.



**Figure 1.** Comparison of patient images before and after microwave ablation treatment. **A:** Preoperative MRI images; **C:** postoperative MRI images; **B:** preoperative ultrasound images; **D:** postoperative ultrasound images.

### Observation indicators

Observation of intraoperative blood loss, preoperative and postoperative levels of FSH, LH, and AMH, length of hospital stay, time to postoperative ambulation, VAS score, and all patients underwent dynamic enhanced MRI scanning (MAGNETOM Skyra, Germany; Contrast Agent: Gadovist, Germany). The MRI process is as follows: Initial MRI scans are performed without the contrast agent to obtain

baseline images of the uterus and fibroids. Sequences include T1-weighted, T2-weighted, and diffusion-weighted imaging (DWI) to assess the morphology and size of the fibroids. Gadovist (Gadobutrol) is administered intravenously at a dose of 0.1 mmol/kg body weight. The contrast agent is injected using an automatic injector at a flow rate of 2 mL/second, followed by a saline flush. Dynamic contrast-enhanced MRI (DCE-MRI) sequences are initiated immediately after the contrast injection. Clinical efficacy assessment: a. Cure: Complete removal of fibroids confirmed by examination, no observation of fibroids in the uterus, achieving a cure. b. Significant improvement: Fibroids significantly reduced in size or symptoms markedly improved. Symptoms such as pain and bleeding were effectively controlled. c. Effective: The volume of fibroids decreased, but did not disappear completely, or symptoms improved but did not disappear completely. d. Ineffective: No significant change in fibroid volume or symptoms did not improve at all. Total effective rate = (Cure + Significant improvement + Effective) cases / total cases  $\times 100\%$ .

### Statistical Analysis

Statistical analysis was performed using SPSS 21.0, presented as mean  $\pm$  standard deviation ( $X \pm SD$ ), and t-test was conducted. Statistical significance was considered when  $P < 0.05$ .

## RESULTS

### Comparison of general data between two groups of patients

The clinical data of the two groups of patients are shown in table 1, with no significant differences ( $P > 0.05$ ).

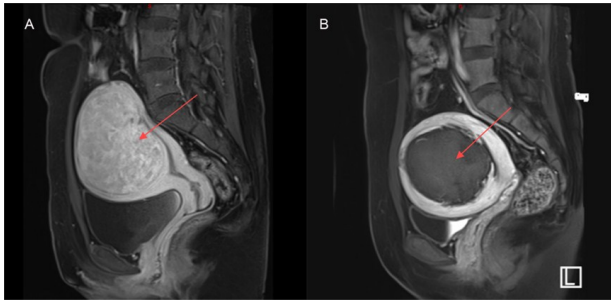
**Table 1.** Comparison of clinical data between the two groups of patients

Index	Laparoscopic Group (n=50)	Combined Group (n=50)	P-value
Age (years)	41.42 $\pm$ 4.39	40.89 $\pm$ 5.85	0.610
Menstrual cycle			0.795
Regular	42 (21%)	40 (20%)	
Irregular	8 (4%)	10 (5%)	
Uterine position			0.706
Anterior	13 (6.5%)	12 (6%)	
Mid	19 (9.5%)	16 (8%)	
Posterior	18 (9%)	22 (11%)	
Fibroid type			0.836
Type 0	1 (2%)	4 (46%)	
Type I	3 (6%)	3 (40%)	
Type II	1 (2%)	3 (14%)	
Type III	9 (18%)	11 (22%)	
Type IV	6 (12%)	5 (10%)	
Type V	8 (16%)	7 (14%)	
Type VI	8 (16%)	6 (12%)	
Type VII	10 (20%)	6 (12%)	
Type VIII	4 (8%)	5 (10%)	



### Comparison of pre- and post-treatment MRIs in the combined group

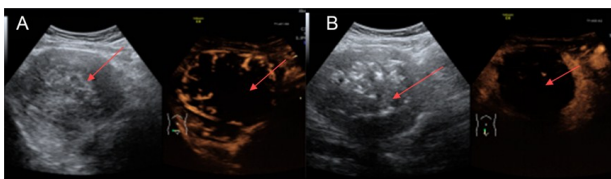
The pre-treatment MRI showed uniform enhancement within the fibroid before fibroid ablation therapy. The post-treatment MRI revealed no enhancement within the fibroid after fibroid ablation therapy, indicating the absence of vascularity within. Microwave ablation led to coagulative necrosis and dehydration within the fibroid, resulting in a reduction in volume of fibroids in both groups post-treatment, thereby alleviating compression on surrounding tissues (figure 2).



**Figure 2.** Before and after images of fibroids treated with laparoscopy combined with microwave ablation. **A:** Preoperative MRI of Fibroid **B:** Postoperative MRI of Fibroid.

### Comparison of pre- and post-treatment contrast-enhanced ultrasound in the combined group

Comparison of pre- and post-treatment contrast-enhanced ultrasound images showed that before ablation, the fibroid exhibited rich blood flow in the contrast agent perfusion area, while after ablation, there was no blood flow signal inside the fibroid, and the blood flow signals inside and around the fibroid disappeared. Contrast-enhanced ultrasound revealed complete lack of enhancement within the uterine fibroid, presenting a "cavity sign" (figure 3).



**Figure 3.** Preoperative and postoperative ultrasound images of uterine fibroids treated with laparoscopy combined with microwave ablation. Preoperative: **A**, Postoperative: **B**.

### Comparison of pre- and post-operative and clinical indicators between the two groups

The combined group showed significantly lower VAS scores compared to the laparoscopic group, indicating that combined surgery can significantly reduce patient pain. Furthermore, the combined group had significantly less intraoperative blood loss than the laparoscopic group, indicating higher safety. Although the operative time was longer in the combined group, possibly due to increased surgical complexity, postoperative recovery indicators such as hospital stay and time to ambulation were better than those in the laparoscopic group, indicating a

faster and more effective overall recovery from combined surgery. Regarding hormone levels, FSH, LH, and AMH data before and after surgery showed no significant differences between the two groups, indicating no significant differences in ovarian function and reserve despite the different surgical methods (table 2).

**Table 2.** Clinical indicators of laparoscopic group and combined group ( $\pm$ SD).

Indicator	Laparoscopic Group (n=50)	Combined Group (n=50)	t-value	P-value
VAS Score (points)	5.63 $\pm$ 1.36	2.34 $\pm$ 1.13	14.24	<0.001
Intraoperative Blood loss (mL)	52.05 $\pm$ 21.69	22.79 $\pm$ 17.13	9.17	<0.001
Operation time (min)	115.65 $\pm$ 28.53	142.09 $\pm$ 80.21	-2.51	0.014
Postoperative Hospital sStay (days)	6.58 $\pm$ 2.07	4.89 $\pm$ 1.44	5.42	<0.001
Time to Ambulation post-surgery (days)	1.96 $\pm$ 0.65	1.07 $\pm$ 0.34	8.58	<0.001
Preoperative FSH (U/L)	8.84 $\pm$ 2.29	9.10 $\pm$ 2.13	0.59	0.557
Postoperative FSH (U/L)	8.41 $\pm$ 4.62	8.39 $\pm$ 8.50	0.573	0.568
Preoperative LH (U/L)	11.05 $\pm$ 3.17	11.93 $\pm$ 2.94	1.184	0.239
Postoperative LH (U/L)	10.13 $\pm$ 4.49	11.18 $\pm$ 3.07	-1.365	0.175
Preoperative AMH (ng/mL)	2.74 $\pm$ 0.21	2.69 $\pm$ 0.30	1.45	0.154
Postoperative AMH (ng/mL)	2.67 $\pm$ 0.27	2.61 $\pm$ 0.24	1.47	0.142

### Comparison of clinical efficacy between the two groups

The combined group showed significantly better treatment outcomes than the laparoscopic group (table 3). The total effective rate in the combined group reached 98%, while in the laparoscopic group, it was 92%, indicating a significant difference between the two groups. This suggests that the combined treatment method has an advantage in improving the success rate of treatment, thereby increasing the cure rate and overall treatment effectiveness for specific diseases.

**Table 3.** Comparison of clinical efficacy between laparoscopic group and combined Group.

Group	Number of Cases	Cured	Markedly Effective	Effective	Ineffective	Total Effective Rate (%)
Laparoscopic Group	50	8	21	16	5	44(92%)
Combined Group	50	15	19	15	1	49(98%)
t						-9.83
P						<0.001

### Comparison of postoperative recovery, complications, and recurrence between the two groups

The combined treatment group showed better outcomes in terms of the number of patients with good menstrual outcomes and those with restored uterine morphology compared to the laparoscopic group. Additionally, it demonstrated better

performance in reducing infection rates, avoiding complications, and significantly reducing the recurrence rate (table 4). Therefore, the combined

treatment method is effective in increasing the cure rate, promoting health recovery, and reducing long-term health risks.

**Table 4.** Comparison of postoperative recovery, complications, and recurrence between laparoscopic group and combined group.

Group	Number of Cases	Menstrual Outcome (cases)	Normal Uterine Morphology (cases)	Infection (cases)	Complications (cases)	Recurrence Rate (%)
Laparoscopic Group	50	21	11	9	3	6 (12%)
Combined Group	50	28	16	5	0	1 (2%)
t						1.998
P						0.038

## DISCUSSION

The findings of this study demonstrate the significant advantages of combining laparoscopy with microwave ablation in the treatment of multiple uterine fibroids. This combined approach offers improvements in several key areas, aligning with and expanding upon existing research in the field. Previous studies have established various treatment options for uterine fibroids, including surgical and non-surgical methods. Radiofrequency ablation (RFA) and laparoscopic myomectomy (LM) are commonly used surgical techniques. A meta-analysis comparing these two methods showed that RFA has advantages in terms of intraoperative blood loss, hospital stay, surgery duration, and recovery time<sup>(14)</sup>. Similarly, our study found that the combined approach of laparoscopy with microwave ablation significantly reduces intraoperative blood loss, shortens hospital stays, and accelerates recovery times compared to traditional laparoscopic surgery alone. Furthermore, the use of laparoscopic ultrasound has been shown to improve the detection and removal of fibroids, reducing the rates of residual and recurrent fibroids<sup>(15)</sup>. Our findings corroborate these results, showing that the combined technique is effective in removing both visible and invisible fibroids, thus minimizing recurrence rates.

The significant reduction in intraoperative blood loss observed in our study can be attributed to the precise targeting capabilities of microwave ablation, which minimizes damage to surrounding tissues. This is consistent with the findings of the meta-analysis on RFA<sup>(16)</sup>, suggesting that precise thermal ablation techniques can enhance surgical outcomes by reducing blood loss and surgical trauma. Our study also highlights the benefits of the combined approach in terms of postoperative recovery and patient satisfaction. These advantages are crucial for improving patient quality of life and reducing the overall burden of uterine fibroids<sup>(17)</sup>. The findings align with the current trend towards minimally invasive surgical techniques, which prioritize patient safety and comfort. The combined approach of laparoscopy and microwave ablation addresses some of the limitations of traditional treatments. For instance, while laparoscopic surgery is effective for certain types of fibroids, it may not be suitable for all cases<sup>(18)</sup>. Microwave ablation, on the other hand, can

effectively treat various types of fibroids, including those that are challenging to remove surgically<sup>(19)</sup>. This comprehensive approach enhances the overall effectiveness of the treatment, providing a more versatile solution for patients with different types of fibroids. Moreover, the lack of significant changes in ovarian function indices post-surgery is a crucial finding. This suggests that the combined method does not compromise ovarian function, which is vital for preserving fertility in reproductive-age women. This aligns with previous research indicating that minimally invasive techniques tend to have less impact on ovarian reserve<sup>(20-23)</sup>. To further validate our findings, future research should focus on larger sample sizes and extended follow-up periods. This will help to assess the long-term efficacy and safety of the combined approach. Additionally, exploring the treatment outcomes for patients with different types of fibroids and at various stages of the disease will provide more personalized and effective treatment options.

In conclusion, the combination of laparoscopy with microwave ablation presents a promising advancement in the treatment of multiple uterine fibroids. It offers significant benefits in terms of surgical outcomes, patient recovery, and long-term efficacy, thereby enhancing the quality of life for patients and expanding the therapeutic arsenal available to clinicians.

## ACKNOWLEDGMENT

None.

**Conflict of interests:** The authors declare that they have no conflict of interests.

**Funding:** This study was supported by Scientific research project of Tongzhou District (Grant no. KJ2023CX029).

**Authors' contributions:** J.Z. and J.G. designed the study and performed the experiments, W.C. and C.L. collected the data, H.X., Y.J. and Y.W. analyzed the data, J.Z. and J.G. prepared the manuscript. All authors read and approved the final manuscript.

**Ethical consideration:** This study was approved by the ethics committee of Beijing Luhe Hospital (Approval no. LH0022419). Signed written informed consents were obtained from the patients and/or guardians.

## REFERENCES

- Perez-Lopez FR, Ornat L, Ceausu I, et al. (2014) EMAS position statement: management of uterine fibroids. *Maturitas*, **79**(1): 106-116.
- Puchar A, Feyeux C, Luton D, Koskas M (2016) Therapeutic management of uterine fibroid tumors. *Minerva Ginecologica*, **68**(4): 466-476.
- Donnez J and Dolmans MM (2016) Uterine fibroid management: from the present to the future. *Hum Reprod Update*, **22**(6): 665-686.
- Rutanen EM (2000) Insulin-like growth factors and insulin-like growth factor binding proteins in the endometrium. Effect of intra-uterine levonorgestrel delivery. *Human Reproduction*, **15** (Suppl 3): 173-181.
- Zhou J, Dsupin BA, Giudice LC, Bondy CA (1994) Insulin-like growth factor system gene expression in human endometrium during the menstrual cycle. *Journal of Clinical Endocrinology & Metabolism*, **79**(6): 1723-1734.
- Iavazzo C, Mamais I, Gkegkes ID (2016) Robotic assisted vs laparoscopic and/or open myomectomy: systematic review and meta-analysis of the clinical evidence. *Arch Gynecol Obstet*, **294**(1): 5-17.
- Han VK, Carter AM, Chandarana S, Tanswell B, Thompson K (1999) Ontogeny of expression of insulin-like growth factor (IGF) and IGF binding protein mRNAs in the guinea-pig placenta and uterus. *Placenta*, **20**(4): 361-377.
- Csatlos E, Rigo JJ, Laky M, Joo JG (2013) Gene expression patterns of insulin-like growth factor 2 in human uterine fibroid tissues: a genetic study with clinical correlations. *Gynecologic and Obstetric Investigation*, **75**(3): 185-190.
- Csatlós E, Rigó J Jr, Laky M, Joó JG (2013) Gene expression patterns of insulin-like growth factor 2 in human uterine fibroid tissues: a genetic study with clinical correlations. *Gynecol Obstet Invest*, **75** (3): 185-190.
- Gloudemans T, Prinsen I, Van Unnik JA, Lips CJ, Den Otter W, Sussenbach JS (1990) Insulin-like growth factor gene expression in human smooth muscle tumors. *Cancer Research*, **50**(20): 6689-6695.
- Han VK, Bassett N, Walton J, Challis JR (1996) The expression of insulin-like growth factor (IGF) and IGF-binding protein (IGFBP) genes in the human placenta and membranes: evidence for IGF-IGFBP interactions at the feto-maternal interface. *Journal of Clinical Endocrinology & Metabolism*, **81**(7): 2680-2693.
- Tang H, Dong Z, Qin Z, et al. (2022) Preliminary Analysis of Safety and Feasibility of a Single-Hole Laparoscopic Myomectomy via an Abdominal Scar Approach. *Frontiers in Surgery*, **9**: 916792.
- Qin S, Jiang Y, Wang F, Tang L, Huang X (2023) Development and validation of a combined model based on dual-sequence MRI radiomics for predicting the efficacy of high-intensity focused ultrasound ablation for hysteromyoma. *International Journal of Hyperthermia*, **40**(1): 2149862.
- Liu L, Xiao YH, Zhou XH (2023) Effects of humanized nursing care on negative emotions and complications in patients undergoing hysteromyoma surgery. *World Journal of Clinical Cases*, **11**(28): 6763-6773.
- McDonald S, Page MJ, Beringer K, Wasiak J, Sprowson A (2014) Preoperative education for hip or knee replacement. *Cochrane Database of Systematic Reviews*, **2014**(5): CD003526.
- Dai Y, Chen H, Yu J, et al. (2024) Global and regional trends in the incidence and prevalence of uterine fibroids and attributable risk factors at the national level from 2010 to 2019: A worldwide database study. *Chinese Medical Journal*, **137**(21): 2583-2589.
- Tomas CC, Oliveira E, Sousa D, et al. (2016) Proceedings of the 3rd IPLeiria's International Health Congress: Leiria, Portugal. 6-7 May 2016. *BMC Health Services Research*, **16** Suppl 3(Suppl 3): 200.
- Gracia M, Rius M, Carmona F (2023) Clinical relevance of uterine fibroids: Epidemiology, risk and protective factors, and pathophysiology. *Medicina Clinica*, **161** (Suppl 1): S1-S4.
- Cardozo ER, Clark AD, Banks NK, Henne MB, Stegmann BJ, Segars JH (2012) The estimated annual cost of uterine leiomyomata in the United States. *American Journal of Obstetrics and Gynecology*, **206** (3): 211.
- Peddada SD, Laughlin SK, Miner K, et al. (2008) Growth of uterine leiomyomata among premenopausal black and white women. *Proceedings of the National Academy of Sciences of the United States of America*, **105**(50): 19887-19892.
- Vilos GA, Allaire C, Laberge PY, Leyland N (2015) The management of uterine leiomyomas. *Journal of Obstetrics and Gynaecology Canada*, **37**(2): 157-178.
- Yuk JS, Cho IC, Lee JH (2023) the risk of stress urinary incontinence after hysterectomy for uterine fibroids. *International Neurourology Journal*, **27**(4): 252-259.
- Baessler K, Christmann-Schmid C, Maher C, Haya N, Crawford TJ, Brown J (2018) Surgery for women with pelvic organ prolapse with or without stress urinary incontinence. *Cochrane Database of Systematic Reviews*, **8**(8): CD013108.