

Effects of laparoscopic ultrasound-guided microwave ablation in combination with surgical resection on liver function and immune function in primary liver cancer patients

L. Zhu¹, L. Chen^{2*}, C. Du¹, N. Tao¹, J. Pan¹

¹Department of Ultrasonic Medicine, Yichun City People's Hospital, Yichun 336000, Jiangxi, China

²Department of Ultrasonic Medicine, The First Affiliated Hospital of Nanchang University, Nanchang 330006, Jiangxi, China

ABSTRACT

► Original article

*Corresponding author:

Li Chen, M.D.,

E-mail: LICHEN7006@163.com

Received: June 2024

Final revised: August 2024

Accepted: August 2024

Int. J. Radiat. Res., April 2025;
23(2): 297-305

DOI: 10.61186/ijrr.23.2.297

Keywords: IMRT, Primary liver cancer, ultrasonography, microwave ablation, hepatectomy, liver function, immune function.

Background: To investigate the effects of laparoscopic ultrasound (LUS)-guided microwave ablation (MWA) combined with surgical resection on liver function and immune function of primary liver cancer (PLC) patients. **Materials and Methods:** Clinical data of 100 patients with PLC after surgery in our hospital from January 2021 to December 2023 were retrospectively analyzed, and divided into laparoscopic hepatectomy (LH group) and laparoscopic ultrasound-guided microwave ablation combined with laparoscopic hepatectomy (LMWA+LH group). Clinical indicators, clinical efficacy, liver function, tumor markers, immune function, incidence of complications, postoperative overall survival rate along with tumor free survival rate between groups were compared. **Results:** Compared with the LH group, the intraoperative blood loss and postoperative hospital stay was decreased in the LMWA+LH group ($P<0.05$). Total effective rate of the LMWA+LH group was 90.00%, higher than the 70.00% in LH group ($P<0.05$). After therapy, reduction in aspartate alanine aminotransferase (ALT), aminotransferase (AST), total bilirubin (TBIL), and the elevation in albumin (ALB) in the LMWA+LH group were more obvious ($P<0.05$). The LMWA+LH group showed more obvious elevation in CD4+ and CD4+/CD8+ levels and reduction in CD8+ level relative to the LH group ($P<0.05$). The complication incidence showed no statistical difference between groups ($P>0.05$). Postoperative survival and tumor free survival rates in the LMWA+LH group were higher than LH group ($P<0.05$). **Conclusion:** Laparoscopic ultrasound-guided microwave ablation combined with surgical resection promotes the postoperative recovery, improves liver function and immune function and improves patient survival rate, which might provide guidance for clinical practice.

INTRODUCTION

Primary liver cancer (PLC) is a commonly diagnosed and life-threatening malignancy worldwide ⁽¹⁾. With the continuous progress of imaging techniques, the detection rate of PLC is also increasing ⁽²⁾. In China, the annual new PLC cases are approximately 500000, accounting for over half of global new PLC cases ^(3, 4). Although traditional surgical resection is considered as the preferred option for PLC treatment that can remove the diseased tissue, the operation is more traumatic, and it is easy to damage the surrounding important tissues and blood vessels ⁽⁵⁾. For patients with multifocal liver cancers, surgical resection is limited with low resection rate, and local treatment methods such as microwave ablation (MWA) and chemotherapeutic embolization are recommended in clinical practice ⁽⁶⁾. As a new treatment method, microwave ablation has the advantages of precise

efficacy, small damage, and relatively high safety. With the advancement in imaging technology, the combined application of laparoscopic technology optimizes its therapeutic effects ⁽⁷⁾. Hence, it is of great significance to assess the clinical effects of LMWA in combination with laparoscopic hepatectomy (LH) on primary liver cancer.

Previous studies have revealed that laparoscopic hepatectomy and ultrasound-guided percutaneous microwave ablation have similar efficacy in treating primary liver cancer, preventing recurrence, as well as improving liver function ^(8, 9). Laparoscopic surgery directly resects cancer tissue, and ultrasound-guided percutaneous microwave ablation uses the microwave heat energy to promote cancer tissue coagulation, which are both effective for treating primary liver cancer ^(10, 11). Microwave ablation also possesses the advantages of high efficiency and fast rate compared with radiofrequency ablation in cancer treatment ⁽¹²⁾. Currently, the imaging-guided

modalities include computed tomography (CT), ultrasound (US), and others. CT has the defects in displaying small lesion due to the metal material artifacts, and US is regarded as safe, fast and effective for microwave ablation guidance⁽¹³⁻¹⁵⁾. However, few studies have explored the effects of laparoscopic ultrasound-guided microwave ablation combined with surgical resection of primary liver cancer in clinic. Therefore, the purpose of this study was to further evaluate this method, explore its feasibility and efficacy in clinical practice, and provide a more effective choice for clinical treatment of primary liver cancer. By comparing the safety and efficacy of combined LH and LUS-guided MWA therapy with those of LH therapy alone, findings of this study might guide the design of operative protocol in clinic.

MATERIALS AND METHODS

General data

Clinical data of 100 primary liver cancer patients after surgery in our hospital from January 2021 to December 2023 were retrospectively analyzed, and were categorized into laparoscopic hepatectomy (LH) group and laparoscopic ultrasound-guided microwave ablation combined with laparoscopic hepatectomy (LMWA+LH) group. The LH group contained 24 male patients and 26 female patients, at an average of 43.56 ± 5.47 years old (35 to 72 years). The tumor diameter ranged from 4 to 11 cm, at an average of 6.13 ± 1.89 cm. The LMWA+LH group contained 25 male patients and 25 female patients, at an average of 3.62 ± 5.52 years old (34 to 73 years). The tumor diameter ranged from 3 to 11 cm, at an average of 6.17 ± 1.92 cm. No statistical difference was discovered in general data between groups ($P > 0.05$).

Inclusion criteria: (1) Preoperative diagnosis of primary hepatocellular carcinoma by imaging or pathological biopsy; (2) no more than 3 intrahepatic tumor lesions, including intrahepatic metastatic lesions, and the maximum diameter of metastatic lesions was no more than 3 cm; (3) Liver function was Child A or B; (4) Preoperative imaging examination did not find vascular invasion and metastasis of other organs outside the liver. Exclusion criteria: (1) Severe jaundice and refractory ascites; (2) Severe dysfunction of the heart, lung, or other systems, unable to tolerate surgery; (3) History of upper abdominal surgery.

Methods

The LH group received laparoscopic hepatectomy. Briefly, preoperative three-dimensional spiral computed tomography (CT, Siemens, Germany) was used to accurately locate the boundary, size, location, and adjacency of the patient's tumor tissue. After anesthesia and disinfection, a pneumoperitoneum of 12 mm CO₂ was established, and laparoscopy was

placed on the umbilicus, and operating holes were established under both ribs. During the operation, the first, second and third hepatic portal could be accurately dissected with the help of B-ultrasound. The scope of resection was defined by electrotome and was performed according to the preoperative three-dimension construction. The blood flow was selectively blocked for different liver lobes and liver segments according to the intraoperative needs, and the precise resection was performed according to the scope of the ischemic liver.

The LMWA+LH group received laparoscopic ultrasound-guided microwave ablation combined with laparoscopic hepatectomy, the method of laparoscopic hepatectomy was the same as LH group, and the method of laparoscopic ultrasound-guided microwave ablation was as follows: after the patient was supine and pneumoperitoneum was established, the ultrasound probe (CA541) was used to select the puncture location under the guidance of ultrasound with ultrasonic apparatus (Mylab ClassC Advanced, Italy). The location of the operation hole was determined based on the location of the tumor. The shape, number, and distribution of peripheral blood vessels of the tumor were first observed by ultrasound to avoid missing lesions, etc. After determining the location of the lesion, abdominal wall puncture with microwave ablation needle (ECO Medical Technology (Nanjing) Co., Ltd., Nanjing, China) was performed, during which dynamic changes could be observed to change the puncture point and multiple puncture was avoided. After insertion into the liver, the probe was repeatedly rotated axially to determine the relationship between the microwave needle and the location of the lesion. If deviation occurred, the needle should be removed and re-puncture until the tumor was accurately penetrated. The hepatic vessels or bile ducts were protected during puncture. The ablation time should be determined based on the size, location, as well as degree of sclerosis of the tumor. The ablation time of each injection was 5-15 min, and the power was 40-60 W. When necessary, re-puncture ablation was performed to ensure the ablation is complete. After the ablation, the needle was ablated when the needle was removed to prevent bleeding or tumor metastasis of the needle. Both groups were treated with anti-infection, analgesic and hormone drugs after operation.

Regular postoperative follow-up

Serum alpha-fetoprotein and abdominal enhanced CT or MRI were examined one month after surgery, every three months in the first year, and semi-annually in the second and third years.

CT was performed using a dual-source CT scanner (Siemens, Germany). Patients were asked to put hands aside of their heads, and instructed with breath-holding training before the scanning. Plain

scanning was conducted with matrix set as 512×512, pitch set as 1.2 mm, tube voltage at 120KV, tube current was set as 80-200mAs, the layer thickness was set as 1.0 mm, the layer spacing was set as 3.0 mm, and gantry rotation speed was set as 0.5 s/r.

For MRI, a 3.0 T MRI system (GE Healthcare, USA) was applied, and patients received breath-holding training before the scanning. The plain MRI scan was performed, including T1-weighted imaging (T1WI) with the time of repetition (TR) adjusted to 4 ms and the time of echo (TE) adjusted to 2 ms, and the T2WI with TR=6316ms, and TE=73 ms, layer thickness was set as 4.0 mm and layer spacing was set as 1.0 mm, and field of view (FOV) at 32cm×32cm (figure 1).

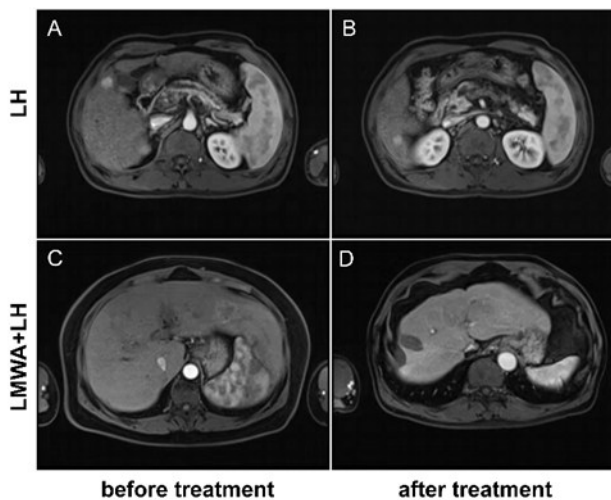


Figure 1. Representative MRI images of primary liver cancer patients in the LH group and LMWA+LH group before and after treatment. (A) before LH. (B) after LH. (C) before LMWA+LH. (D) after LMWA+LH.

Observation indicators

(1) Clinical indicators including intraoperative blood loss and hospital stay in both groups were analyzed.

(2) One month post operation, the clinical efficacy of treatment was assessed based on the evaluation criteria for solid tumor⁽¹⁶⁾. Complete remission: the lesion disappeared after treatment. Partial remission: the lesion baseline diameter was decreased by ≥30%. Stable disease: there was no increase or decrease in the baseline length of the lesion <30%. Progressive disease: the lesion baseline diameter was increased or new lesions appeared. Total response rate = (number of complete remission+ number of partial remission)/ total cases ×100%.

(3) Liver function indicators: Automatic biochemical analyzer of Beckman Coulter's AU680 model (Beckman Coulter, USA) was adopted to calculate and compare the liver function levels of patients such as total bilirubin (TBIL), albumin (ALB), alanine aminotransferase (ALT), as well as aspartate aminotransferase (AST).

(4) Tumor markers: Fasting venous blood was taken from both groups before and 3 days after

surgery, and serum was taken by centrifugation at a rate of 3000 r/min. The levels of alpha-fetoprotein (AFP, ab108838, abcam, UK), carbohydrate antigen 199 (CA199, EHCA199, Invitrogen, USA) as well as carcinoembryonic antigen (CEA, ab264604, abcam, UK) were determined using enzyme-linked immunosorbent assay (ELISA).

(5) Before and after operation, T lymphocyte subsets, including CD3⁺, CD4⁺ and CD4⁺/CD8⁺, were detected by flow cytometry (BD Biosciences, USA) in both groups.

(6) After operation, the two groups were observed continuously for 7 days to observe whether there were complications such as pleural effusion, chest infection, and incision congestion.

(7) The rate of overall survival as well as tumor free survival in two groups was analyzed and compared.

Statistical analysis

SPSS 20.0 (SPSS, Inc., USA) was adopted for data analysis. Measurement data were shown as the ($\bar{x} \pm s$) and t test was adopted for comparison between groups. Categorical data were exhibited as [n (%)], and were measured by χ^2 test. $P < 0.05$ indicated statistical significance.

RESULTS

Clinical indicators of primary liver cancer patients in two groups

As shown in figure 1, the intraoperative blood loss was 93.1 ± 10.7 in the LH group, while the LMWA+LH group reduced the level to 72.8 ± 11.9 mL ($P < 0.0001$, figure 2A). Additionally, those in the LMWA+LH group had average hospital stay of 6.9 ± 1.1 days, which was reduced relative to the 9.1 ± 0.9 days in the LH group ($P < 0.0001$, figure 2B). The outcomes indicate that LMWA+LH group has better postoperative recovery in comparison with the LH group.

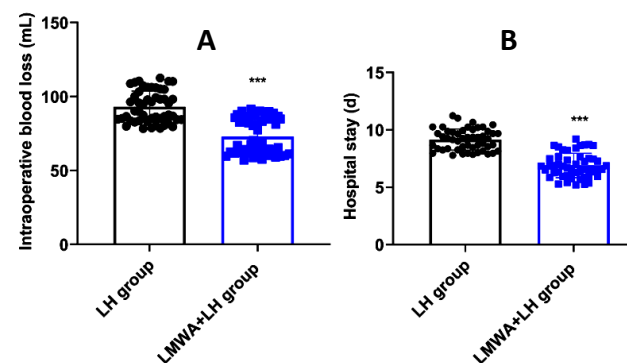


Figure 2. Clinical indicators of primary liver cancer patients in two groups. (A) The intraoperative blood loss of patients in the LH or LMWA+LH groups. (B) The hospital stays of patients in the LH or LMWA+LH groups. *** $P < 0.001$.

The clinical response of patients in two groups was monitored and evaluated one month after

surgery. In the LMWA+LH group, 26 patients had complete remission and 19 patients showed partial remission, and the total effective rate reached 90.00%. In the LH group, totally 18 patients had complete remission and 17 patients showed partial remission, and the total effective rate was 70.00%, which was significantly lower than that of the LMWA+LH group, with statistical significance ($P=0.012$, table 1).

Table 1. Clinical efficacy of two interventions on primary liver cancer patients.

Groups	N	Complete remission	Partial remission	Stable disease	Progressive disease	Total response rate
LH group	50	18	17	7	8	35 (70.00%)
LMWA+LH group	50	26	19	3	2	45 (90.00%)
χ^2						6.250
P						0.012

N, number; LH, laparoscopic hepatectomy; LMWA, laparoscopic ultrasound-guided microwave ablation.

Liver function of primary liver cancer patients in two groups

Prior to therapy, no difference was discovered in liver function indexes such as AST ($P=0.813$), ALT ($P=0.985$), TBIL ($P=0.856$), as well as ALB ($P=0.967$) between the LH and LMWA+LH groups ($P>0.05$). After therapy, AST, ALT and TBIL were declined ($P<0.0001$) while ALB was elevated in the LH group ($P=0.01$) as well as the LMWA+LH ($P<0.0001$) group, and the LMWA+LH group showed more obvious reduction of AST ($P<0.0001$), ALT ($P<0.0001$) and TBIL ($P=0.027$) as well as the elevation of ALB ($P=0.017$) when comparing with the LH group (figure 3A-D).

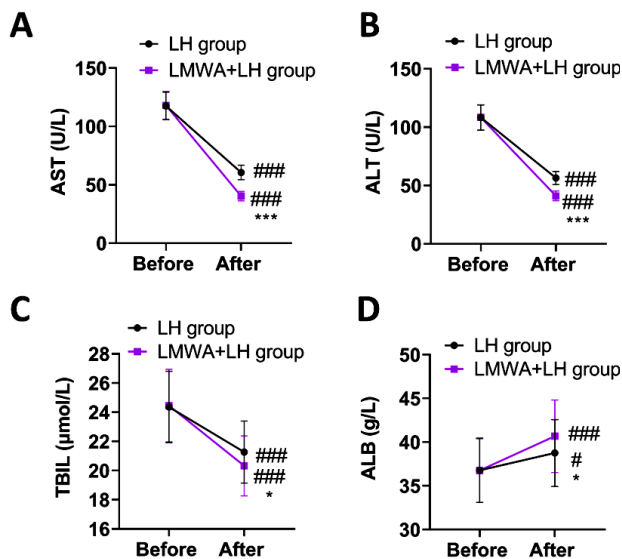


Figure 3. Liver function of primary liver cancer patients before and after treatment in two groups. (A) AST, (B) ALT, (C) TBIL and (D) ALB level in patient serum was examined before and after the LH or LMWA+LH therapy. In contrast to before therapy, # meant $P<0.05$, ### meant $P<0.001$. In contrast to LH, * meant $P<0.05$, *** meant $P<0.001$.

Detection of cancer biomarkers in primary liver cancer patients in two groups

Prior to therapy, the serum levels of tumor markers including AFP, CEA and CA199 in the LH and LMWA+LH groups were not statistically different ($P>0.05$). After therapy, AFP, CEA and CA199 levels were declined in two groups ($P<0.0001$), and those in the LMWA+LH group presented lower levels when comparing with the LH group ($P<0.0001$, figure 4).

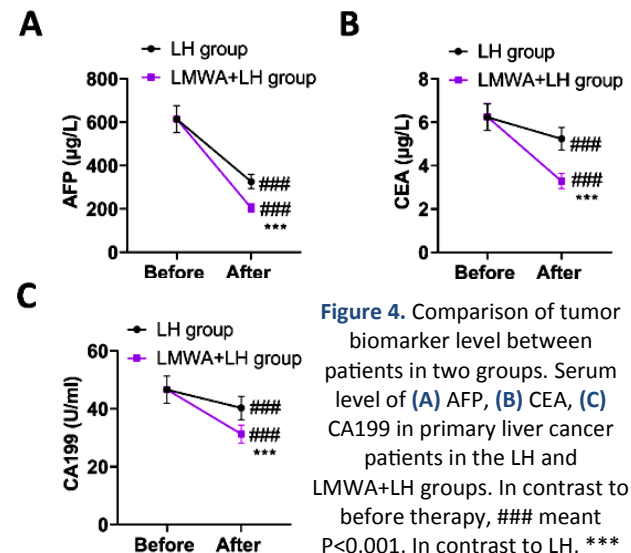


Figure 4. Comparison of tumor biomarker level between patients in two groups. Serum level of (A) AFP, (B) CEA, (C) CA199 in primary liver cancer patients in the LH and LMWA+LH groups. In contrast to before therapy, ### meant $P<0.001$. In contrast to LH, *** meant $P<0.001$.

Detection of T lymphocyte subsets in 2 groups

The T lymphocyte subsets were detected to evaluate the immune function of primary liver cancer patients in two groups before and after treatment. Prior to therapy, we found no statistical difference in T lymphocyte subsets between LH and LMWA+LH groups ($P>0.05$). After therapy, $CD4^+$ and $CD4^+/CD8^+$ levels were elevated while $CD8^+$ level was declined in both groups ($P<0.0001$). Relative to LH group, the elevation of $CD4^+$ and $CD4^+/CD8^+$ levels as well as the reduction of $CD8^+$ level in the LMWA+LH group was more dramatic ($P<0.0001$, figure 5).

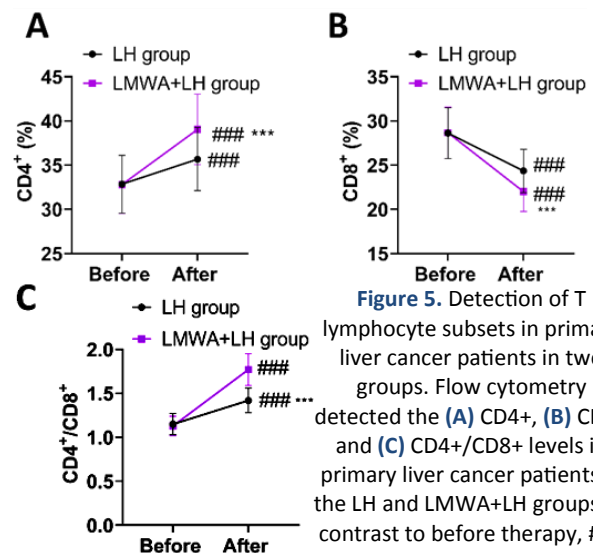


Figure 5. Detection of T lymphocyte subsets in primary liver cancer patients in two groups. Flow cytometry detected the (A) $CD4^+$, (B) $CD8^+$ and (C) $CD4^+/CD8^+$ levels in primary liver cancer patients in the LH and LMWA+LH groups. In contrast to before therapy, ### meant $P<0.001$. In contrast to LH, *** meant $P<0.001$.

Incidence of complications in primary liver cancer patients in two groups

As shown in table 2, 4 patients had complications in the LMWA+LH group, with a total incidence of 8.0%, and 3 patients in the LH showed complications with a total incidence of 6.0%. The incidence of complications showed no statistical difference between 2 groups ($P=0.695$).

Table 2. Incidence of complications in 2 groups.

Groups	N	Pleural effusion	Chest infection	Incision congestion	Total incidence rate
LH group	50	1	1	1	3 (6.00%)
LMWA+LH group	50	2	1	1	4 (8.00%)
χ^2					0.154
P					0.695

N, number; LH, laparoscopic hepatectomy; LMWA, laparoscopic ultrasound-guided microwave ablation.

Postoperative survival rate and tumor free survival rate in both groups

We also compared the survival outcomes between patients in the LH and LMWA+LH groups. As displayed in figure 5, the postoperative tumor free survival rate ($P=0.014$) as well as the overall survival rate ($P=0.028$) in the LMWA+LH group was more favorable relative to the LH group ($P<0.05$, figure 6A-B).

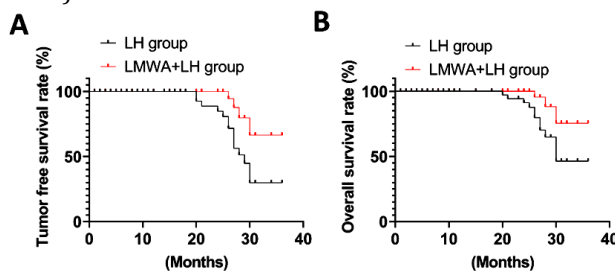


Figure 6. Postoperative survival rate and tumor free survival rate in both groups. (A) Tumor free survival rate (%) and (B) overall survival rate (%) of primary liver cancer patients in the LH group or LMWA+LH group.

DISCUSSION

The incidence of primary liver cancer in China is relatively high, and the incidence and fatality rate are still rising ⁽¹⁷⁾. At present, the pathogenesis of primary liver cancer remains largely unknown, which might be the result of multi-factor synergism ⁽¹⁸⁾. According to relevant epidemiological investigations, primary liver cancer is mostly related to cirrhosis, viral hepatitis, alcoholic liver disease, family history and genetic factors ⁽¹⁹⁾. Surgery, liver transplantation and radiofrequency ablation are the main treatment methods for primary liver cancer ⁽²⁰⁾. Radiofrequency ablation has significant effect on small tumors, but for large tumors, the internal ablation temperature cannot meet the requirements, which is easy to lead to tumor cell residue, which affects the therapeutic effect to a certain extent ⁽²¹⁾. At present,

ultrasound-guided microwave ablation has been gradually applied in clinical practice ⁽²²⁾. By rubbing tumor cells to generate heat through microwave, it can rapidly generate heat inside the tumor and maintain a high temperature ⁽²³⁾. In recent years, it has become a hot spot in the research of primary liver cancer ⁽²⁴⁾.

The clinical application of LMWA combined with surgical resection of primary liver cancer has important research significance and clinical application value ⁽²⁵⁾. First of all, laparoscopic ultrasound-guided microwave ablation or ultrasound-guided microwave ablation combined with laparoscopic surgery, shows great technical advantages. The laparoscopic ultrasound probe is high-frequency ultrasound, which can obtain high-resolution ultrasound images, conduct comprehensive liver scan, achieve accurate tumor location, and promote cancer tissue coagulation through microwave ablation, which is comparable to surgical resection ⁽²⁶⁾. Compared with traditional surgical resection methods, laparoscopic surgery has less trauma and smaller surgical wounds, and has obvious advantages in reducing patients' pain and rapid recovery ⁽²⁷⁾. Secondly, the clinical application of LMWA combined with surgical resection of primary liver cancer can avoid the risk of traditional surgical resection of important tissues and blood vessels around the injury, especially for the pathological tissues adjacent to the main blood vessels, the risk of traditional surgical resection is greater ⁽²⁸⁾. Pre-coagulation of tumor tissue through microwave ablation can better protect the integrity of surrounding tissues and blood vessels and reduce the risk of surgery ⁽²⁹⁾. In addition, laparoscopic ultrasound-guided microwave ablation in combination with surgical resection of primary liver cancer can also enhance the immune function of patients. Previous studies have shown that percutaneous radiofrequency ablation can enhance immune function and lessen the levels of tumor markers such as alpha-fetoprotein ⁽³⁰⁾. Therefore, laparoscopic ultrasound-guided microwave ablation in combination with surgical resection of primary liver cancer may have a positive impact on the immune function and the level of tumor markers in patients.

Previous studies have compared the effects between local ablation and laparoscopic surgery for liver disease therapy. For example, ultrasound-guided thermal ablation shows significantly less trauma with reduced operation time, intraoperative bleeding volume and normal liver tissue loss compared with the laparoscopic surgery for treating focal nodular hyperplasia of the liver ⁽²⁷⁾. Ultrasound-guided microwave ablation is also demonstrated to not only reduce the operation time, blood loss, hospital stay, but also the ALT and AST levels compared with treatment with laparoscopic

surgery in small liver cancer patients ⁽³¹⁾. The Ultrasound-guided microwave ablation is revealed to be highly tolerated with high complete ablation rate in hepatocellular carcinoma patients ⁽³²⁾. Consistently, in our study, the LMWA+LH group showed improved operation outcomes such as reduced postoperative hospital stay and intraoperative blood loss when comparing with the LH group (figure 2), the total effective rate of the LMWA+LH group was 90.00%, higher than that of the LH group (70.00%) (table 1), and the reduction of AST, ALT and TBIL as well as the elevation of ALB in the LMWA+LH group were more obvious when comparing with the LH group (figure 3), suggesting that laparoscopic ultrasound-guided microwave ablation in combination with surgical resection was effective in the treatment of primary liver cancer and could promote the postoperative recovery and reduce liver injury. The reason may be that LMWA has the advantages of minimal trauma, simple operation and quick postoperative recovery ⁽³³⁾. It can be performed repeatedly, and it can be directly and locally radical for small focal tumors, and it is also very convenient to treat recurrent and multiple lesions. The microwave ablation curing zone is about 1 cm, and the liver tissue outside the curing zone will not be damaged ⁽³⁴⁾.

Tumor markers play an important role in tumor screening, disease observation, efficacy evaluation as well as prognosis evaluation ⁽³⁵⁾. AFP is of great significance in the diagnosis of liver cancer ⁽³⁶⁾. The early clinical diagnosis of liver cancer is mainly based on the results of imaging tests and AFP level ⁽³⁷⁾. AFP is an acidic glycoprotein, which is mainly secreted in large quantities during the fetal period ⁽³⁸⁾. Because the cancerous liver cells can restore the embryonic AFP synthesis function, such as the AFP value in the blood >400 ng/ mL, more than 95% of the probability can be confirmed as liver cancer ⁽³⁹⁾. CEA is a glycoprotein of 180 kDa molecular weight, which is present in the epithelial cells of colon cancer and embryonic colon mucosa ⁽⁴⁰⁾. When malignant changes occur, tumor cells abnormally synthesize CEA and enter the blood and lymphatic circulation, resulting in abnormal increase of serum CEA ⁽⁴¹⁾. CA199 belongs to the oligosaccharide tumor-associated antigen secreted by digestive system tumor cell line, which has certain effect in the diagnosis of digestive system malignant tumor diseases, especially liver cancer, colon cancer and pancreatic cancer ^(42, 43). In this study, AFP, CEA and CA199 after therapy showed lower levels in the LMWA+LH group relative to the LH group (figure 4), suggesting that laparoscopic ultrasound-guided microwave ablation in combination with surgical resection could decline the level of tumor markers in primary liver cancer patients, which was consistent with previous studies ^(44, 45).

CD4⁺ can help regulate the phagocytic function of

phagocytic cells, which is positively correlated with body immunity ⁽⁴⁶⁾. CD8⁺ is a toxic T cell that participates in the body's immune suppression and is negatively correlated with the body's immunity ⁽⁴⁷⁾. CD4⁺/CD8⁺ can reflect the balance of immune cells of the subject, and the larger the ratio within the normal range, the stronger the immunity of the patient ⁽⁴⁸⁾. In our study, the results displayed that after therapy, the elevation of CD4⁺ and CD4⁺/CD8⁺ levels as well as the reduction of CD8⁺ level in the LMWA+LH group were more obvious when comparing with the LH group (Figure 5), suggesting that laparoscopic ultrasound-guided microwave ablation combined with surgical resection could effectively restore the balance of T lymphocyte subsets and improve the immunity of patients. The reason may be that laparoscopic ultrasound-guided microwave ablation combined with surgical resection can effectively kill tumor cells and reduce immune dysfunction on the one hand; on the other hand, microwave ablation promotes lesion coagulation, accelerates the elimination of various immunosuppressive molecules, and improves the immune response of patients, thus achieving better immune improvement effects ⁽⁴⁹⁾. Moreover, clinical outcomes of US-guided MWA and surgical resection for liver cancer treatment have been previously compared. An et al. have reported that patients receiving US-guided MWA and surgical resection have similar five-year overall survival (63%, 48.1%) as well as disease-free survival (67.5%, 48.8%)⁽⁵⁰⁾. In our study, we found that the postoperative survival rate as well as tumor free survival in the LMWA+LH group was more favorable relative to the LH group (figure 6), implying that laparoscopic ultrasound-guided microwave ablation combined with surgical resection had obvious advantages in improving the clinical outcomes of patients.

In conclusion, laparoscopic ultrasound-guided microwave ablation combined with surgical resection accelerates the postoperative recovery, improves liver function and immune function, reduces tumor biomarker levels, and improves patient survival rate, which might provide clues for the clinical management of primary liver cancer.

ACKNOWLEDGMENTS

Not applicable.

Funding: Not applicable.

Conflicts of interests: The authors declare no conflicts of interest.

Ethical consideration: The present study was approved by the Ethics Committee of the Yichun City People's Hospital (approval number: 2024-131).

Author contribution: L.Z.: Conceptualization, data analysis, manuscript preparation; L.C.: Conceptualization, data analysis, manuscript revision; C.D., N.T., J.P.: data acquisition and analysis,

manuscript review. All authors read and approved the final version of the manuscript.

REFERENCES

- Liu CY, Chen KF, Chen PJ (2015) Treatment of Liver Cancer. *Cold Spring Harb Perspect Med*, **5**(9): a021535.
- Jeong S, Zheng B, Wang H, et al. (2018) Nervous system and primary liver cancer. *Biochim Biophys Acta Rev Cancer*, **1869**(2): 286-92.
- Sung H, Ferlay J, Siegel RL, et al. (2021) Global Cancer Statistics 2020: GLOBOCAN Estimates of Incidence and Mortality Worldwide for 36 Cancers in 185 Countries. *CA: a Cancer Journal for Clinicians*, **71**(3): 209-49.
- Feng M, Pan Y, Kong R, et al. (2020) Therapy of primary liver cancer. *Innovation (Cambridge (Mass))*, **1**(2): 100032.
- Orcutt ST, Anaya DA (2018) Liver resection and surgical strategies for management of primary liver cancer. *Cancer Control*, **25**(1): 1073274817744621.
- Xu ZJ, Wei MJ, Zhang XM, et al. (2022) Effects of microwave ablation on serum Golgi protein 73 in patients with primary liver cancer. *World J Gastroenterol*, **28**(29): 3971-80.
- Liu F, Hou B, Li Z, et al. (2023) Microwave ablation of multifocal primary liver cancer guided by real-time 3.0T MRI. *Int J Hyperthermia*, **40**(1): 2228519.
- Zhang W, Zhu W, Yang J, et al. (2021) Augmented reality navigation for stereoscopic laparoscopic anatomical hepatectomy of primary liver cancer: preliminary experience. *Front Oncol*, **11**: 663236.
- Liang P, Yu J, Lu MD, et al. (2013) Practice guidelines for ultrasound-guided percutaneous microwave ablation for hepatic malignancy. *World J Gastroenterol*, **19**(33): 5430-8.
- Yoshida H, Taniat N, Yoshioka M, et al. (2019) Current status of laparoscopic hepatectomy. *J Nippon Med Sch*, **86**(4): 201-6.
- Ren H, An C, Liang P, et al. (2019) Ultrasound-guided percutaneous microwave ablation assisted by three-dimensional visualization treatment platform combined with transcatheter arterial chemoembolization for a single large hepatocellular carcinoma 5 cm or larger: a preliminary clinical application. *Int J Hyperthermia*, **36**(1): 44-54.
- Suwa K, Seki T, Aoi K, et al. (2021) Efficacy of microwave ablation versus radiofrequency ablation for hepatocellular carcinoma: a propensity score analysis. *Abdominal radiology (New York)*, **46**(8): 3790-7.
- Wang Y, Cheng Z, Yu J, et al. (2020) US-guided percutaneous microwave ablation for early-stage hepatocellular carcinoma in elderly patients is as effective as in younger patients: A 10-year experience. *Journal of Cancer Research and Therapeutics*, **16**(2): 292-300.
- Peng Y, Cui D, Li W, et al. (2021) Ultrasound-guided percutaneous microwave ablation for hepatocellular carcinoma originating in the caudate lobe: A pilot clinical study. *Journal of Cancer Research and Therapeutics*, **17**(3): 764-70.
- Minami Y, Nishida N, Kudo M (2014) Therapeutic response assessment of RFA for HCC: contrast-enhanced US, CT and MRI. *World Journal of Gastroenterology*, **20**(15): 4160-6.
- Nishino M (2018) Tumor Response Assessment for Precision Cancer Therapy: Response Evaluation Criteria in Solid Tumors and Beyond. *Am Soc Clin Oncol Educ Book*, **38**: 1019-29.
- Shi JF, Cao M, Wang Y, et al. (2021) Is it possible to halve the incidence of liver cancer in China by 2050? *Int J Cancer*, **148**(5): 1051-65.
- Li X, Ramadori P, Pfister D, et al. (2021) The immunological and metabolic landscape in primary and metastatic liver cancer. *Nat Rev Cancer*, **21**(9): 541-57.
- Salazar J, Le A (2021). The Heterogeneity of Liver Cancer Metabolism. *Adv Exp Med Biol*, **1311**: 127-36.
- Zhou H and Song T (2021). Conversion therapy and maintenance therapy for primary hepatocellular carcinoma. *Biosci Trends*, **15**(3): 155-60.
- Izzo F, Granata V, Grassi R, et al. (2019) Radiofrequency ablation and microwave ablation in liver tumors: an update. *Oncologist*, **24**(10): e990-e1005.
- Xu Z, Yang Z, Pan J, et al. (2018) Individualized laparoscopic B-ultrasound-guided microwave ablation for multifocal primary liver cancer. *Wideochir Inne Tech Maloinwazyjne*, **13**(1): 9-16.
- Fang L, Meng X, Luo W, et al. (2019) Treatment of primary hepatic carcinoma through ultrasound-guided microwave ablation. *Niger J Clin Pract*, **22**(10): 1408-11.
- Ran B, Chang YL, Qi J, et al. (2021) The clinical effects of ultrasound-guided microwave ablation in the treatment of primary hepatic carcinoma: Protocol for a retrospective clinical observation. *Medicine (Baltimore)*, **100**(48): e28045.
- Zhang D, Chen Z, Zhang L, et al. (2023) Application of Laparoscopic Hepatectomy Combined with Intraoperative Microwave Ablation in Colorectal Cancer Liver Metastasis. *J Vis Exp*, **3**: (193).
- Tinguly P, Fusaglia M, Freedman J, et al. (2017). Laparoscopic image-based navigation for microwave ablation of liver tumors-A multi-center study. *Surg Endosc*, **31**(10): 4315-24.
- Zhang DL, Chen S, Lin YC, et al. (2022) Ultrasound-guided thermal ablation versus laparoscopic surgery for focal nodular hyperplasia of the liver: A retrospective controlled study. *Frontiers in Oncology*, **12**: 932889.
- Senitko M, Oberg CL, Abraham GE, et al. (2022) Microwave ablation for malignant central airway obstruction: a pilot study. *Respiration*, **101**(7): 666-74.
- Thomas MN, Dieplinger G, Datta RR, et al. (2021). Navigated laparoscopic microwave ablation of tumour mimics in pig livers: a randomized ex-vivo experimental trial. *Surg Endosc*, **35**(12): 6763-9.
- Xia Y, Li J, Liu G, et al. (2020). Long-term Effects of repeat hepatectomy vs percutaneous radiofrequency ablation among patients with recurrent hepatocellular carcinoma: a randomized clinical trial. *JAMA Oncol*, **6**(2): 255-63.
- Zhong H, Hu R, Jiang YS (2022) Evaluation of short- and medium-term efficacy and complications of ultrasound-guided ablation for small liver cancer. *World Journal of Clinical Cases*, **10**(14): 4414-24.
- Ma S, Ding M, Li J, et al. (2017). Ultrasound-guided percutaneous microwave ablation for hepatocellular carcinoma: clinical outcomes and prognostic factors. *Journal of Cancer Research and Clinical Oncology*, **143**(1): 131-42.
- Krasnick BA, Sindram D, Simo K, et al. (2019) Tumor ablation using 3-dimensional electromagnetic-guided ultrasound versus standard ultrasound in a porcine model. *Surg Innov*, **26**(4): 420-6.
- Pan WD, Zheng RQ, Nan L, et al. (2010) Ultrasound-guided percutaneous microwave coagulation therapy with a "cooled-tip needle" for the treatment of hepatocellular carcinoma adjacent to the gallbladder. *Dig Dis Sci*, **55**(9): 2664-9.
- Lech G, Słotwiński R, Słodkowski M, et al. (2016) Colorectal cancer tumour markers and biomarkers: Recent therapeutic advances. *World J Gastroenterol*, **22**(5): 1745-55.
- Zhao K, Zhou X, Xiao Y, et al. (2022) Research Progress in alpha-fetoprotein-induced immunosuppression of liver cancer. *Mini Rev Med Chem*, **22**(17): 2237-43.
- Liu H, Xu Y, Xiang J, et al. (2017). Targeting alpha-fetoprotein (AFP)-MHC complex with CAR T-cell therapy for liver cancer. *Clin Cancer Res*, **23**(2): 478-88.
- Munson PV, Adamik J, Butterfield LH (2022) Immunomodulatory impact of α -fetoprotein. *Trends Immunol*, **43**(6): 438-48.
- Sun LY, Cen WJ, Tang WT, et al. (2022) Alpha-fetoprotein ratio predicts alpha-fetoprotein positive hepatocellular cancer patient prognosis after hepatectomy. *Dis Markers*, **2022**: 7640560.
- Bacac M, Fauti T, Sam J, et al. (2016) A novel carcinoembryonic antigen T-cell bispecific antibody (CEA TCB) for the treatment of Solid Tumors. *Clin Cancer Res*, **22**(13): 3286-97.
- Bray AW, Duan R, Malalur P, et al. (2022) Elevated serum CEA is associated with liver metastasis and distinctive circulating tumor DNA alterations in patients with castration-resistant prostate cancer. *Prostate*, **82**(13): 1264-72.
- Kong Y, Jing Y, Sun H, et al. (2022) The Diagnostic Value of Contrast-Enhanced Ultrasound and Enhanced CT Combined with Tumor Markers AFP and CA199 in Liver Cancer. *J Healthc Eng*, **2022**: 5074571.
- Scarà S, Bottoni P, Scatena R (2015) CA 19-9: Biochemical and clinical aspects. *Adv Exp Med Biol*, **867**: 247-60.
- Lin ZP, Huang DB, Zou XG, et al. (2023) Percutaneous microwave ablation and transcatheter arterial chemoembolization for serum tumor markers and prognostics of middle-late primary hepatic carcinoma. *World J Gastrointest Surg*, **15**(12): 2783-91.
- Chen YY, Yen HH (2011) Subcutaneous metastases after laparoscopic-assisted partial hepatectomy for hepatocellular carcinoma. *Surg Laparosc Endosc Percutan Tech*, **21**(1): e41-3.
- Ruterbusch M, Pruner KB, Shehata L, et al. (2020) In vivo CD4(+) T cell differentiation and function: Revisiting the Th1/Th2 paradigm. *Annu Rev Immunol*, **38**: 705-25.
- Reina-Campos M, Scharping NE, Goldrath AW (2021) CD8(+) T cell metabolism in infection and cancer. *Nat Rev Immunol*, **21**(11): 718-38.

48. Overgaard NH, Jung JW, Steptoe RJ, *et al.* (2015) CD4+/CD8+ double-positive T cells: more than just a developmental stage? *J Leukoc Biol*, **97**(1): 31-8.
49. Zhou W, Yu M, Mao X, *et al.* (2022) Landscape of the peripheral immune response induced by local microwave ablation in patients with breast cancer. *Adv Sci (Weinh)*, **9**(17): e2200033.
50. An C, Hu ZL, Liang P, *et al.* (2018) Ultrasound-guided percutaneous microwave ablation vs. surgical resection for thoracoabdominal wall implants from hepatocellular carcinoma: intermediate-term results. *International journal of hyperthermia*, **34**(7): 1067-76.