

Complications in CT-guided biopsy of tiny pulmonary nodules: a case-control study

G. Wang^{1*}, P. Liu², X. Qubie², C. Fan², Y. Fang²

¹Thoracic Surgery, Huoshan County Hospital, Anhui Province, China 237200

²Medical imaging department, Armed Police Force Hospital of Sichuan, Leshan 614000, Sichuan province

ABSTRACT

► Original article

*Corresponding author:

Guozhong Wang, M.D.,

E-mail:

wangguozhong8268@163.com

Received: October 2024

Final revised: February 2025

Accepted: February 2025

Int. J. Radiat. Res., October 2025;
23(4): 901-906

DOI: 10.61186/ijrr.23.4.10

Keywords: CT-guided percutaneous lung biopsy, diagnostic yield, cardiorespiratory changes, patient outcomes.

Background: This investigation explores the effectiveness and physiological consequences of CT-guided percutaneous lung biopsies, a common technique for analysing pulmonary nodules. **Materials and Methods:** The study involved a paired comparison involving 211 patients who received CT-guided lung biopsies and an equal number of matched controls who did not undergo the procedure. Variables such as demographic and baseline health characteristics, changes in cardiorespiratory parameters, and patient outcomes were meticulously recorded and analysed. **Results:** Both groups exhibited comparable baseline demographics and health statuses. The procedure confirmed the presence of malignancy or other diseases in 90% of cases (190 out of 211 patients). Significant physiological responses post-biopsy included elevated heart rate, increased systolic and diastolic blood pressure, enhanced respiratory rate, and reduced oxygen saturation levels, all statistically significant compared to controls. However, metrics such as hospital stay duration, rate of readmission within 30 days, and survival after one year showed no statistical difference between the groups. The incidence of complications following the biopsies was calculated at 15%. **Conclusion:** CT-guided percutaneous lung biopsy is a reliable diagnostic tool for pulmonary nodules, as evidenced by its high diagnostic yield. The procedure, however, leads to noticeable transient cardiorespiratory changes, underscoring the necessity for vigilant monitoring and supportive care during and after the procedure. Long-term patient outcomes did not differ significantly between the groups, indicating the procedure's safety profile in a clinical setting.

INTRODUCTION

CT-guided percutaneous lung biopsy is a critical procedure in the evaluation of pulmonary lesions, offering a less invasive option compared to traditional surgical methods. Its role in providing timely and precise diagnoses has established it as an essential technique in contemporary medical practice. However, the procedure comes with inherent risks, including potential cardiorespiratory alterations, which warrant careful evaluation⁽¹⁾.

The introduction of CT imaging has significantly transformed diagnostic radiology by enabling detailed visualization of internal structures. This advancement has been pivotal in refining CT-guided percutaneous lung biopsy methods, now a standard approach for sampling suspicious lung tissues. The high diagnostic yield of this technique is crucial for determining the nature of lung lesions, which in turn guides treatment strategies and impacts patient outcomes⁽²⁻⁶⁾. Despite its clinical benefits, the safety of CT-guided percutaneous lung biopsy must be rigorously assessed. Common complications include pneumothorax, haemorrhage, and air embolism⁽⁷⁾. Additionally, the procedure can induce various cardiorespiratory changes, such as fluctuations in heart rate and blood pressure, and in some cases,

more severe complications like arrhythmias. These changes are believed to result from a combination of patient-specific factors, procedural techniques, and the mechanical effects of the biopsy needle passing through pulmonary tissue⁽⁷⁻⁹⁾.

Studies have reported varying complication rates associated with this procedure, underscoring the need for a deeper understanding of the contributory factors⁽⁷⁻¹²⁾. Advances in biopsy technology, including the adoption of diverse needle types and the integration of real-time CT fluoroscopy, necessitate ongoing reassessment of the associated risks. Furthermore, literature suggests that the incidence and severity of complications may vary based on operator experience, lesion characteristics, and patient comorbidities, indicating that these variables need to be systematically evaluated⁽¹⁰⁻¹³⁾.

While previous studies⁽⁹⁻¹³⁾ have primarily focused on diagnostic yield and procedural complications, limited attention has been given to the real-time assessment of cardiorespiratory changes during CT-guided lung biopsy. This gap in knowledge presents an opportunity to explore and integrate findings on both diagnostic efficacy and the physiological impacts of the procedure.

In light of the indispensable role that CT-guided percutaneous lung biopsy plays in diagnosing

thoracic conditions and the imperative to thoroughly understand its risk profile, this case-control study aims to systematically evaluate the diagnostic efficacy of the procedure and investigate the incidence and predictors of cardiorespiratory changes. The study's novelty lies in its focus on the simultaneous assessment of diagnostic and physiological outcomes, integrating advancements in biopsy technology and procedural techniques to provide new insights into patient safety and procedural optimization.

MATERIALS AND METHODS

Research design and participant criteria

This retrospective case-control study evaluated data from January 2021 to December 2022, following approval by the Institutional Review Board. Informed consent was waived due to the retrospective design. Participants in the biopsy group included adults aged 18 years or older with indeterminate pulmonary nodules identified on prior imaging. The control group comprised individuals with similar demographic profiles and nodule characteristics who did not undergo biopsy. Exclusion criteria included contraindications to CT or biopsy procedures, such as coagulopathies, known allergies to contrast agents, or significant cardiorespiratory instability.

Equipment and Materials

The study utilized the following equipment and materials:

- CT scanner: Philips Brilliance 64-Slice CT scanner (Philips Healthcare, Netherlands).
- Fluoroscopy System: Real-time CT fluoroscopy (Siemens Healthineers, Germany).
- Biopsy Needles: 20-gauge guide needles and 18-gauge biopsy needles (Bard Monopty Biopsy Instrument, USA).
- Contrast Agent: Iohexol (Omnipaque 300, GE Healthcare, USA).
- Reagents for Immunohistochemistry (IHC): Primary antibodies and detection kits were sourced from Dako (Agilent Technologies, USA).

Histology Stains: Hematoxylin and eosin staining reagents (Thermo Fisher Scientific, USA).

Calculation of sample size

The study's sample size was calculated to ensure sufficient power to detect a 15% difference in diagnostic outcomes and associated cardiorespiratory changes between the groups. Assuming an alpha of 0.05 and a beta of 0.20 (80% power), the formula for comparing two proportions in matched case-control settings was applied. Adjustments were made for potential attrition, yielding a total sample size of 211 participants per group, with 422 participants in total.

Procedure description

CT-guided percutaneous lung biopsies were performed by experienced thoracic radiologists. Patients were positioned based on the nodule location, and a pre-procedure CT scan determined the optimal needle path. Local anesthetic (Lidocaine, AstraZeneca, Sweden) was administered at the insertion site. The procedure employed a coaxial technique using 20-gauge guide needles and 18-gauge biopsy needles under real-time CT fluoroscopy guidance. Post-procedure CT scans were conducted to identify immediate complications. Patients were observed for four hours post-biopsy to monitor for delayed adverse events. Figure 1 shows the initial CT image showing nodule positioning before the biopsy.

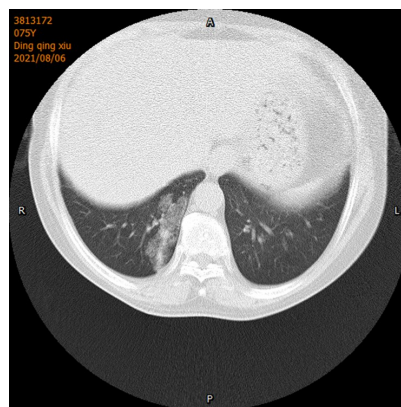


Figure 1. Nodule positioning before the biopsy.

Diagnostic evaluation

Biopsy samples were processed using standard histological methods, including hematoxylin and eosin staining. Immunohistochemistry assays were conducted using Dako primary antibodies and detection kits. The protocol involved deparaffinization, antigen retrieval, blocking, application of primary antibodies, and visualization with chromogen. Tissue adequacy was assessed by a pathologist, with non-diagnostic cases classified as samples that were insufficient or unrepresentative.

Monitoring and data collection

Cardiorespiratory parameters, including heart rate, blood pressure, respiratory rate, and oxygen saturation, were monitored at baseline, during the procedure, and after the intervention at standardized intervals. Data from both groups were collected retrospectively from electronic medical records.

Statistical methods

Data were analysed using SPSS (Version 26.0, IBM, USA). Descriptive statistics summarized patient demographics, nodule characteristics, and outcomes. Diagnostic yield and cardiorespiratory changes were compared between groups using appropriate statistical tests, with significance set at $p < 0.05$. Kaplan-Meier survival curves and scatter plots were generated to visualize the relationship between nodule characteristics and diagnostic outcomes.

Ethical framework

The study adhered to the ethical standards outlined in the Declaration of Helsinki. Approval was granted by the Institutional Review Board, with a waiver of informed consent. Patient anonymity was maintained throughout, and risks were carefully balanced against the benefits of conducting the research.

RESULTS

Table 1 outlines the demographic characteristics of the study participants, highlighting that the case and control groups were comparable in terms of age, gender distribution, smoking history, nodule size, and prevalence of comorbid conditions. Both groups demonstrated a similar balance in these key variables, with no significant differences observed. Comorbidities such as COPD, hypertension, and diabetes were consistently represented in both groups, ensuring a fair basis for comparison.

Table 1. Baseline characteristics of the assessed sample size.

Demographic Variable	Cases (n=211)	Cases (%)	Controls (n=211)	Controls (%)	p-value
Age (years)					
Mean (SD)	62.5 (8.3)	-	61.8 (7.9)	-	0.45
Gender					
Male	118	55.9	114	54.0	0.70
Female	93	44.1	97	46.0	0.70
Smoking History					
Non-smoker	85	40.3	89	42.2	0.68
Former smoker	66	31.3	62	29.4	0.62
Current smoker	60	28.4	60	28.4	1.00
Nodule Size (cm)					
Mean (SD)	3.2 (1.1)	-	3.1 (1.0)	-	0.52
Comorbidities					
COPD	32	15.2	30	14.2	0.76
Hypertension	101	47.9	96	45.5	0.58

Baseline cardiorespiratory measurements for both groups are summarized in table 2. Parameters such as heart rate, blood pressure (systolic and diastolic), respiratory rate, and oxygen saturation showed no significant differences between groups before the procedure, indicating comparable baseline cardiorespiratory health.

Table 2. Comparison of baseline cardiorespiratory parameters
(Note: Biopsy group refers to patients scheduled for percutaneous lung biopsy. Control group refers to patients undergoing assessment without a scheduled biopsy)

Parameter	Biopsy Group (n=80)	Mean \pm SD	Control Group (n=80)	Mean \pm SD	p-value
Heart Rate (beats per minute)	72.3 \pm 8.6	72.3 \pm 8.6	71.4 \pm 7.9	71.4 \pm 7.9	0.28
Systolic BP (mmHg)	128.5 \pm 12.7	128.5 \pm 12.7	126.9 \pm 13.4	126.9 \pm 13.4	0.33
Diastolic BP (mmHg)	80.6 \pm 8.3	80.6 \pm 8.3	79.8 \pm 7.7	79.8 \pm 7.7	0.41
Respiratory Rate (bpm)	16.3 \pm 2.2	16.3 \pm 2.2	16.1 \pm 2.1	16.1 \pm 2.1	0.52
Oxygen Saturation (%)	97.2 \pm 1.1	97.2 \pm 1.1	97.4 \pm 1.0	97.4 \pm 1.0	0.43

Post-procedure findings, detailed in table 3, reveal significant differences in cardiorespiratory parameters between the biopsy and control groups. The biopsy group exhibited a higher average heart rate (76.4 beats per minute, SD: 9.1) compared to controls (71.9 beats per minute, SD: 7.8, $p < 0.001$). Increases were also noted in systolic and diastolic blood pressures ($p = 0.01$ and $p = 0.02$, respectively) and respiratory rate (17.8 breaths per minute, SD: 2.4, versus 16.2 breaths per minute, SD: 2.1 in controls, $p < 0.001$). Additionally, a decrease in oxygen saturation was observed (96.5%, SD: 1.3, compared to 97.3%, SD: 1.0 in controls, $p = 0.001$).

Table 3. Comparative analysis of post-procedural cardiorespiratory parameters between groups.

Parameter	Biopsy Group Post-Procedure	Mean \pm SD	Control Group	Mean \pm SD	p-value
Heart Rate (beats per minute)	76.4 \pm 9.1	76.4 \pm 9.1	71.9 \pm 7.8	71.9 \pm 7.8	<0.001
Systolic BP (mmHg)	132.8 \pm 14.1	132.8 \pm 14.1	127.2 \pm 13.3	127.2 \pm 13.3	0.01
Diastolic BP (mmHg)	83.2 \pm 8.8	83.2 \pm 8.8	79.5 \pm 7.9	79.5 \pm 7.9	0.02
Respiratory Rate (bpm)	17.8 \pm 2.4	17.8 \pm 2.4	16.2 \pm 2.1	16.2 \pm 2.1	<0.001
Oxygen Saturation (%)	96.5 \pm 1.3	96.5 \pm 1.3	97.3 \pm 1.0	97.3 \pm 1.0	0.001

The outcomes and diagnostic yield are summarized in table 4. The diagnostic success rate of CT-guided percutaneous lung biopsies stood at 90% (190/211 cases). There were minor differences in hospital stay lengths, with the biopsy group averaging 2.7 days (SD: 1.5) compared to 2.5 days (SD: 1.2) for controls ($p = 0.22$). The 30-day readmission rate was slightly higher in the biopsy group at 5.7% (12/211) versus 4.3% (9/211) in the control group, but this difference was not statistically significant ($p = 0.42$). The complication rate in the biopsy group was reported at 15% (32/211 cases). One-year survival rates were similar between groups, 85% (179/211) for biopsy participants and 88% (186/211) for controls ($p = 0.37$). The study did not report one-year disease-free survival rates.

Table 4. Diagnostic yield and patient outcomes.

Outcome	Biopsy Group (n=211)	Mean \pm SD	Control Group (n=211)	Mean \pm SD	p-value
Diagnostic Yield (%)	90% (190/211)	90%	N/A	N/A	N/A
Length of Hospital Stay (days)	2.7 \pm 1.5	2.7 \pm 1.5	2.5 \pm 1.2	2.5 \pm 1.2	0.22
30-Day Readmission Rate (%)	5.7% (12/211)	5.7%	4.3% (9/211)	4.3%	0.42
Complication Rate (%)	15% (32/211)	15%	N/A	N/A	N/A
Overall Survival at 1 Year (%)	85% (179/211)	85%	88% (186/211)	88%	0.37
Disease-Free Survival at 1 Year (%)	N/A	N/A	N/A	N/A	N/A

The pre-biopsy axial CT scan (figure 2) highlights a left-sided pulmonary nodule with associated pleural

thickening and adjacent lung parenchymal involvement. The nodule appears well-defined, necessitating biopsy for histopathological confirmation. This image serves as a baseline representation of the lesion prior to intervention. The post-biopsy axial CT scan (figure 3) demonstrates the site of needle insertion and minor parenchymal changes surrounding the biopsy site. No immediate complications such as pneumothorax or haemorrhage are visible. This image confirms the successful retrieval of tissue while maintaining procedural safety.

Figure 2. Axial CT scan demonstrating a left-sided pulmonary nodule with adjacent pleural thickening and subtle lung parenchymal changes before biopsy.

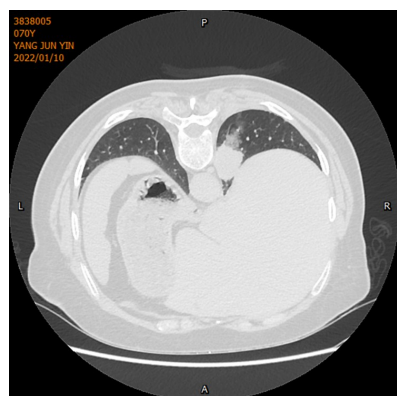
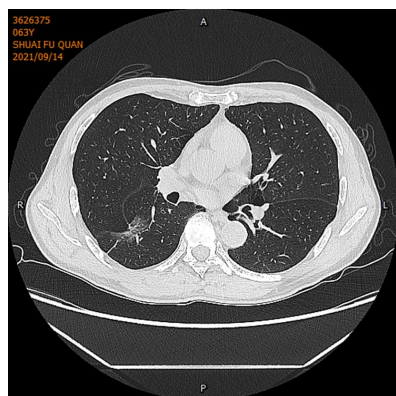


Figure 3. Axial CT scan post-biopsy showing the position of the needle tract and changes in the nodule's surrounding lung parenchyma.

DISCUSSION

Our investigation revealed that CT-guided percutaneous lung biopsies achieve a diagnostic success rate of 90% in securing accurate tissue samples for the evaluation of lung nodules and masses. This high efficacy is crucial for precise diagnosis, which is integral to determining the appropriate treatment plans for patients. However, the procedure also caused notable changes in cardiorespiratory parameters, including elevated heart rate and blood pressure, an increase in respiratory rate, and a decrease in oxygen saturation. These alterations underscore the necessity for vigilant monitoring and comprehensive management of patients undergoing these biopsies to ensure their safety.

Despite these immediate changes in cardiorespiratory functions, the study found no

substantial differences in long-term outcomes, such as overall survival rates, between the biopsy group and a control group. This indicates that while the biopsy procedure may influence cardiorespiratory functions temporarily, it does not adversely affect the long-term prognosis of patients. Nevertheless, the absence of data on disease-free survival after one year highlights a gap that requires further exploration to fully understand the impact of biopsies on disease progression and recurrence.

The analysis also emphasizes the importance of meticulous patient selection for undergoing CT-guided percutaneous lung biopsy. Factors such as age, gender, smoking history, nodule size, and existing comorbidities were comparable between the biopsy and control groups, suggesting that these may not significantly affect the decision-making process for this procedure. However, individual patient health and specific comorbidities should still be considered to assess the risk-benefit ratio effectively.

A review of the literature identifies several risk factors associated with the severity and occurrence of complications post-biopsy (12). Multivariate analyses have pointed out factors such as the lesion's location in the lung, the extent of pleural contact, the number of pleural punctures, and the volume of tissue samples collected as contributing to an increased risk of pneumothorax, a frequent complication (13-17).

Other studies have provided mixed results regarding the relationship between needle penetration depth and complication rates. Some research indicates a significant association between longer intrapulmonary paths and prolonged puncture times with higher rates of pneumothorax (18-21). Additionally, analyses comparing different biopsy techniques, such as fine-needle aspiration (FNAB) and cutting-needle biopsy (CNB), have identified various factors influencing complication rates, including lesion size, lesion depth, and patient demographic characteristics (21-23). Further research is warranted to continue refining the techniques and protocols associated with CT-guided lung biopsies, aiming to minimize risks while maintaining high diagnostic accuracy. The ongoing evaluation of procedural variables, patient-specific factors, and long-term outcomes will be critical in enhancing the safety and effectiveness of these procedures.

The findings of our study on complications and diagnostic outcomes in CT-guided percutaneous lung biopsy showed both similarities and differences when compared to previous studies, including those by Heerink *et al.* (24), Tamrazi *et al.* (25), Wu *et al.* (26), Huang *et al.* (27), and Iguchi *et al.* (28). Our study reported a diagnostic yield of 90%, which was consistent with the findings of Tamrazi *et al.* (25), who achieved a 97.9% diagnostic yield for small pulmonary nodules. Similarly, Huang *et al.* (27) reported diagnostic accuracies of 83.7% for nodules ≤ 15 mm and 96.8% for larger lesions. These results

reaffirmed that CT-guided core biopsies provided reliable diagnostic outcomes across a range of nodule sizes. Pneumothorax and pulmonary haemorrhage were the most common complications in our study, which aligned with the findings of Heerink *et al.* ⁽²⁴⁾, Wu *et al.* ⁽²⁶⁾, and Iguchi *et al.* ⁽²⁸⁾. Heerink *et al.* ⁽²⁴⁾ specifically noted that pneumothorax was a frequent complication, particularly in core biopsies, while Iguchi *et al.* ⁽²⁸⁾ highlighted higher rates of complications with the transpulmonary biopsy route. Additionally, our study identified smaller nodule size and longer needle path length as significant risk factors for complications, consistent with the findings of Huang *et al.* ⁽²⁷⁾.

There were, however, notable differences in complication rates. Heerink *et al.* ⁽²⁴⁾ reported overall complication rates of 38.8% for core biopsies and 24.0% for fine needle aspiration (FNA), which were higher than the 15% complication rate observed in our study. This discrepancy may have reflected advancements in biopsy techniques, operator expertise, or differences in patient populations. Similarly, major complications such as the need for chest tube placement were less frequent in our study, aligning with the low intervention rates reported by Tamrazi *et al.* ⁽²⁵⁾ (6.8%), but contrasting with the findings of Iguchi *et al.* ⁽²⁸⁾, where 18.6% of transpulmonary biopsies required chest tube placement. These variations underscored the influence of procedural techniques, such as the use of transpleural versus transpulmonary routes, on complication rates.

While Huang *et al.* ⁽²⁷⁾ reported lower diagnostic accuracy for smaller nodules, our study maintained a consistently high diagnostic yield across nodule sizes, suggesting that lesion size had less impact on diagnostic outcomes in our cohort. Heerink *et al.* ⁽²⁴⁾ also identified increased traversed lung parenchyma and larger needle diameter as risk factors for complications in FNA, whereas these factors were not significant in our study, possibly due to differences in needle types or procedural approaches.

Limitations

The study's limited sample size may have impacted its statistical power, potentially influencing the ability to detect significant differences in outcomes with low event rates, such as long-term survival and disease-free survival. A larger sample size would strengthen the data's reliability and improve its applicability to a broader range of populations. Furthermore, the absence of detailed long-term follow-up data, particularly regarding disease-free survival and recurrence rates, limits the ability to evaluate the enduring effects of CT-guided biopsies on patient management and outcomes. These aspects are critical for understanding the procedure's long-term clinical implications. Additionally, the study's single-centre design restricts the generalizability of its findings to other

institutions or diverse patient populations. Conducting multi-center studies would help validate the results and offer a more comprehensive perspective on the diagnostic and procedural aspects of CT-guided lung biopsies across varied settings.

CONCLUSION

The investigation confirmed the high diagnostic value of CT-guided percutaneous lung biopsy in obtaining tissue samples for analysing pulmonary nodules. Although associated with notable cardiorespiratory changes, these did not translate into adverse long-term outcomes when compared with controls. These findings highlight the importance of meticulous peri-procedural management and patient selection to ensure the procedure's safety and effectiveness without compromising long-term patient health.

Funding: The funding bodies had no role in the design, collection, analysis, or interpretation of the data, or in the writing of the manuscript.

Conflicts of interest: The authors declare no conflicts of interest regarding the publication of this study. The research was conducted independently, and there were no financial or personal relationships that could influence the study outcomes.

Ethical consideration: This study was approved by the Institutional Review Board (IRB). Informed consent was waived due to the retrospective nature of the research. The study adhered strictly to the principles of the Declaration of Helsinki, ensuring patient anonymity and confidentiality throughout the data collection and analysis process. All risks and benefits associated with the research were carefully considered, and measures were taken to ensure patient safety.

Author contributions: P.L.: Conceptualization, study design, data interpretation, and manuscript drafting. X.Q.: Data collection, statistical analysis, and review of diagnostic methodologies. C.F.: Oversight of the biopsy procedures, technical guidance, and quality assurance of clinical data. Y.F.: Critical revision of the manuscript, supervision of the study, and final approval of the submitted manuscript. All authors reviewed and approved the final manuscript. They contributed significantly to the work and accept full responsibility for the content of the article.

REFERENCES

1. Rivera MP, Mehta AC, Wahidi MM (2013) Establishing the diagnosis of lung cancer: diagnosis and management of lung cancer 3rd ed. American college of chest physicians' evidence-based clinical practice guidelines. *Chest*, **143**: e1425-e1655.
2. Mondoni M, Sotgiu G, Bonifazi M, *et al.* (2016) Transbronchial needle aspiration in peripheral pulmonary lesions: a systematic review and meta-analysis. *Eur Respir J*, **48**: 196-204.
3. Steinfurt DP, Khor YH, Manser RL, Irving LB (2011) Radial probe endobronchial ultrasound for the diagnosis of peripheral lung

- cancer: systematic review and meta-analysis. *Eur Respir J*, **37**: 902-910.
4. Ali MS, Trick W, Mba BL, Mohanane D, Setni J, Musani A (2017) Radial endobronchial ultrasound for the diagnosis of peripheral pulmonary lesions: A systematic review and meta-analysis. *Respirology*, **22**: 443-453.
 5. Zhan P, Zhu QQ, Miu YY, et al. (2017) Comparison between endobronchial ultrasound-guided transbronchial biopsy and CT-guided transthoracic lung biopsy for the diagnosis of peripheral lung cancer: A systematic review and meta-analysis. *Transl Lung Cancer Res*, **6**: 23-34.
 6. Fielding DI, Chia C, Nguyen P, et al. (2012) Prospective randomized trial of endobronchial ultrasound-guide sheath versus computed tomography-guided percutaneous core biopsies for peripheral lung lesions. *Intern Med J*, **42**: 894-900.
 7. Han Y, Kim HJ, Kong KA, et al. (2018) Diagnosis of small pulmonary lesions by transbronchial lung biopsy with radial endobronchial ultrasound and virtual bronchoscopic navigation versus CT-guided transthoracic needle biopsy: A systematic review and meta-analysis. *PLoS One*, **13**: e0191590.
 8. Hur J, Lee HJ, Nam JE, et al. (2009) Diagnostic accuracy of CT fluoroscopy-guided needle aspiration biopsy of ground-glass opacity pulmonary lesions. *Am J Roentgenol*, **192**: 629-634.
 9. Yamauchi Y, Izumi Y, Nakatsuka S, et al. (2011) Diagnostic performance of percutaneous core needle lung biopsy under multi-CT fluoroscopic guidance for ground-glass opacity pulmonary lesions. *Eur J Radiol*, **79**: e85-e89.
 10. Inoue D, Gobara H, Hiraki T, et al. (2012) CT fluoroscopy-guided cutting needle biopsy of focal pure ground-glass opacity lung lesions: Diagnostic yield in 83 lesions. *Eur J Radiol*, **81**: 354-359.
 11. Yamagami T, Yoshimatsu R, Miura H, et al. (2013) Diagnostic performance of percutaneous lung biopsy using automated biopsy needles under CT-fluoroscopic guidance for ground-glass opacity lesions. *Br J Radiol*, **86**: 20120447.
 12. Nakamura K, Matsumoto K, Inoue C, Matsusue E, Fujii S (2021) Computed tomography-guided lung biopsy: A review of techniques for reducing the incidence of complications. *Interv Radiol (Higashimatsuyama)*, **6**(3): 83-92.
 13. Khan MF, Straub R, Moghaddam SR, et al. (2008) Variables affecting the risk of pneumothorax and intrapulmonary haemorrhage in CT-guided transthoracic biopsy. *Eur Radiol*, **18**: 1356-1363.
 14. Kakizawa H, Toyota N, Hieda M, et al. (2010) Risk factors for severity of pneumothorax after CT-guided percutaneous lung biopsy using the single-needle method. *Hiroshima J Med Sci*, **59**: 43-50.
 15. Hiraki T, Mimura H, Gobara H, et al. (2010) Incidence of and risk factors for pneumothorax and tube placement after CT fluoroscopy-guided percutaneous lung biopsy: retrospective analysis of the procedures conducted over a 9-year period. *Am J Roentgenol*, **194**: 809-814.
 16. Loh SEK, Wu DDF, Venkatesh SK, et al. (2013) CT-guided thoracic biopsy: evaluating diagnostic yield and complications. *Ann Acad Med Singap*, **42**: 285-290.
 17. Nakatani M, Tanigawa N, Kariya S, Komemushi A, Yagi R, Sawada S (2012) Analysis of factors influencing accuracy and complications in CT-guided lung biopsy. *Minim Invasive Ther*, **21**: 415-422.
 18. Vagn-Hansen C, Pedersen MR, Rafaeisen SR (2016) Diagnostic yield and complications of transthoracic computed tomography-guided biopsies. *Dan Med J*, **63**: A5239.
 19. Modi P and Uppe A (2024) Lung Biopsy Techniques and Clinical Significance. In: StatPearls [Internet]. Treasure Island (FL): StatPearls Publishing. Available from: <https://www.ncbi.nlm.nih.gov/books/NBK563153/>.
 20. Haas BM, Clayton JD, Elicker BM, Ordovas KG, Naeger DM (2017) CT-guided percutaneous lung biopsies in patients with suspicion for infection may yield clinically useful information. *AJR Am J Roentgenol*, **208**(2): 459-463. doi: 10.2214/AJR.16.16255.
 21. Lee HN, Do KH, Kim EY, Choe J, Sung H, Choi SH, Kim HJ (2024) Comparative analysis of CT findings and clinical outcomes in adult patients with disseminated and localized pulmonary nocardiosis. *J Korean Med Sci*, **39**(11): e107. doi: 10.3346/jkms.2024.39.e107.
 22. Ming M, Lu N, Qian W (2023) Evaluation of computed tomography images under deep learning in the diagnosis of severe pulmonary infection. *Front Comput Neurosci*, **17**: 1115167. doi: 10.3389/fncom.2023.1115167.
 23. Watane GV, Hammer MM, Barile MF (2019) CT-guided core-needle biopsy of the lung is safe and more effective than fine-needle aspiration biopsy in patients with hematologic malignancies. *Radiol Cardiothorac Imaging*, **1**(5): e180030. doi: 10.1148/ryct.2019180030.
 24. Heerink WJ, de Bock GH, de Jonge GJ, et al. (2017) Complication rates of CT-guided transthoracic lung biopsy: meta-analysis. *Eur Radiol*, **27**: 138-148. doi: 10.1007/s00330-016-4357-8.
 25. Tamrazi A, Sundaresan S, Parvizi A, Eller A, Fujii J, Shaheen Z, Campbell A (2022) Clinical value of CT-guided biopsy of small (≤ 1.5 cm) suspicious lung nodules: Diagnostic accuracy, molecular characterization and long-term clinical outcomes. *Cancer Treat Res Commun*, **33**: 100626. doi: 10.1016/j.ctarc.2022.100626.
 26. Wu CC, Maher MM, Shepard JA (2011) Complications of CT-guided percutaneous needle biopsy of the chest: prevention and management. *AJR Am J Roentgenol*, **196**(6): W678-82. doi: 10.2214/AJR.10.4659.
 27. Huang MD, Weng HH, Hsu SL, Hsu LS, Lin WM, Chen CW, Tsai YH (2019) Accuracy and complications of CT-guided pulmonary core biopsy in small nodules: a single-center experience. *Cancer Imaging*, **19**(1): 51. doi: 10.1186/s40644-019-0240-6.
 28. Iguchi T, Hiraki T, Matsui Y, Tomita K, Uka M, Tanaka T, Munetomo K, Gobara H, Kanazawa S (2021) CT-guided biopsy of lung nodules with pleural contact: Comparison of two puncture routes. *Diagn Interv Imaging*, **102**(9): 539-544. doi: 10.1016/j.diii.2021.05.005.