

Effect of host anti-tumor immune response following endoscopic mucosal resection combined with photodynamic treatment in patients with early gastrointestinal cancer

B. Xia[#] and M. Qiu^{*,*}

Department of Gastroenterology, Fuzong Clinical Medical College of Fujian Medical University, 900TH Hospital of PLA Joint Logistics Support Force, Fuzhou City, Fujian Province, China

► Original article

*Corresponding author:

Minlian Qiu, M.D.,

E-mail:

15980276855@163.com

Received: May 2024

Final revised: June 2025

Accepted: June 2025

Int. J. Radiat. Res., October 2025;
23(4): 967-972

DOI: 10.61186/ijrr.23.4.19

Keywords: Photodynamic therapy, endoscopic mucosal resection, T cell response, gastrointestinal cancer, host immune modulation.

These authors contributed equally to this article.

ABSTRACT

Background: To investigate the host anti-tumor immune response induced by the combination of endoscopic mucosal resection (EMR) and photodynamic therapy (PDT) in patients with early gastrointestinal cancer (EGIC), and its impact on recurrence and immune modulation. **Materials and Methods:** A total of 120 patients diagnosed with EGIC were enrolled and divided into EMR-only (n=60) and EMR+PDT (n=60) groups. Peripheral blood samples were taken before treatment, and on days 7 and 30 post-treatment. Immune markers (CD4+, CD8+ T cells, NK cells) were measured by flow cytometry. Serum cytokines (IL-2, IL-6, IFN- γ , TNF- α , IL-10) were assessed using ELISA. Recurrence was tracked over 6 months using endoscopic follow-up. **Results:** At day 30, the EMR+PDT group showed significantly elevated CD8+ T cell counts ($P<0.01$), IFN- γ levels ($P<0.01$), and NK cell activity ($P<0.05$) compared to EMR-only. There was a marked decrease in Treg cells and IL-10 in the EMR+PDT group ($P<0.05$). Recurrence rate was 5% in the PDT group versus 18% in EMR-only ($P=0.01$). **Conclusion:** PDT combined with EMR enhances host immune responses against tumor cells via immunogenic cell death, improving clinical outcomes in early gastrointestinal cancers.

INTRODUCTION

Early-stage gastrointestinal cancers (EGIC), including early esophageal, gastric, and colorectal cancers, are typically confined to the mucosal or superficial submucosal layers and lack lymph node metastasis, often described as "intramucosal cancer" (1-4). With the advent of advanced endoscopic diagnostic techniques, the detection rate of these early malignancies has significantly increased, allowing for timely and potentially curative interventions (2, 5). Timely diagnosis and treatment in these early stages have been shown to improve long-term survival and quality of life in affected patients (5).

Standard treatments for EGIC include surgical resection, laparoscopic approaches, and increasingly, endoscopic techniques such as endoscopic mucosal resection (EMR) and endoscopic submucosal dissection (ESD) (6, 7). Compared with traditional open or laparoscopic surgery, EMR offers a minimally invasive alternative, utilizing the natural luminal

tract to access and remove the lesion, thus minimizing tissue trauma, reducing recovery time, and lowering costs. However, incomplete resections and microscopic residual disease remain a concern, contributing to local recurrence rates in a subset of patients (7, 8).

Photodynamic therapy (PDT) has emerged as a promising adjunct modality in the management of gastrointestinal malignancies. PDT involves the administration of a photosensitizer, which is selectively retained by tumor cells and then activated by a specific wavelength of light to produce reactive oxygen species, resulting in targeted cytotoxicity (9). Beyond its direct tumoricidal effect, PDT has been shown to induce immunogenic cell death (ICD), characterized by the release of damage-associated molecular patterns (DAMPs) such as calreticulin and HMGB1, which activate dendritic cells and promote adaptive anti-tumor immunity (5, 9).

Emerging evidence suggests that this PDT-induced ICD not only improves local tumor control but also primes systemic immune responses capable

of targeting micrometastatic disease, thus positioning PDT as both a local and immunomodulatory therapy (10-12). Despite these promising mechanisms, clinical studies quantifying the immune-enhancing effects of PDT in conjunction with EMR for early gastrointestinal cancers remain limited.

This study aims to investigate the immunological outcomes and recurrence rates associated with EMR combined with PDT in patients with EGIC. By evaluating immune cell populations and cytokine profiles pre- and post-treatment, we seek to determine whether PDT enhances host anti-tumor immune responses and improves clinical outcomes when used as an adjunct to EMR.

MATERIALS AND METHODS

Study design and population

This single-center, prospective, randomized controlled trial was conducted at the Department of Gastroenterology of the 900th Hospital of the Joint Logistics Support Force in Fuzhou, China, from October 2021 to October 2023. A total of 120 patients diagnosed with early-stage gastrointestinal cancer (EGIC) were enrolled and randomly assigned to one of two groups using a computer-generated randomization sequence. The control group underwent endoscopic mucosal resection (EMR) alone, while the intervention group received EMR followed by photodynamic therapy (PDT), with 60 patients allocated to each group. The study received ethical approval from the hospital's Institutional Ethics Committee (Approval No. JLSF900styu), and all participants provided written informed consent prior to enrollment.

Inclusion and exclusion criteria

Eligible patients were between 18 and 80 years old, with pathologically confirmed early-stage esophageal, gastric, or colorectal adenocarcinoma. All tumors were confined to the mucosa or superficial submucosa (T1N0M0) with no evidence of lymph node or distant metastasis, as confirmed by enhanced chest and abdominal computed tomography (CT) and endoscopic ultrasound. Tumor size was limited to ≤ 2 cm in diameter, and all lesions were accessible for fiber-optic PDT delivery. Additional inclusion criteria included an Eastern Cooperative Oncology Group (ECOG) performance status of 2 or less. Patients were excluded if they had hypersensitivity to porphyrin-based photosensitizers, concurrent esophageal varices, major vessel invasion, or bleeding risk, as well as severe cardiac (NYHA class III-IV), renal (eGFR <30 mL/min), or hepatic (Child-Pugh C) dysfunction. Other exclusion criteria included coagulation disorders, significant psychiatric illness or cognitive impairment, a history of prior oncologic therapies, pregnancy or lactation, or refusal to

participate.

Endoscopic mucosal resection (EMR) procedure

Before the EMR procedure, patients with colorectal lesions were prepared with 3 liters of polyethylene glycol solution (Nulytely®, Shanghai Pharmaceuticals, China), while those with upper gastrointestinal tumors fasted for at least eight hours. The procedure was carried out under conscious sedation using intravenous midazolam (Dormicum®, Roche, Switzerland) and pethidine (Dolantin®, Bayer, Germany). A therapeutic video endoscope was used: for upper gastrointestinal lesions, a GIF-HQ290 (Olympus, Japan) was employed, and for colorectal lesions, a CF-HQ290I (Olympus, Japan) was used. The electrosurgical unit utilized was an ERBE VIO 300D (ERBE Elektromedizin, Germany).

During the procedure, lesions were identified and demarcated with 0.4% indigo carmine dye (ChromoVision®, Guangzhou Tongjun Medical, China), and then elevated using a submucosal injection of 0.4% sodium hyaluronate solution (MucoUp®, Boston Scientific, USA). A snare resection was performed using an insulated-tip electrosurgical knife (DualKnife J®, Olympus, Japan). After resection, specimens were retrieved and pinned on cork for histopathological evaluation, following formalin fixation and paraffin embedding.

Photodynamic therapy (PDT) protocol

In the intervention group, PDT was administered 48 hours after EMR. Hematoporphyrin derivative (Photofrin®, Axcan Pharma, Canada) was infused intravenously at a dose of 2.0 mg/kg, diluted in 100 mL of 0.9% saline (Baxter, USA) over a 10-minute period. For light activation, a diode laser system (PD Laser 630, Diomed Ltd., UK) was used, which emitted red light at 630 nm. Light delivery was achieved through an optical fiber with a cylindrical diffuser (Optiguide® Fiber Optic Diffuser, Medlight SA, Switzerland), which was introduced through the endoscope. The laser settings were adjusted to deliver a light dose of 100 J/cm² at an output power of 300 mW/cm over 500 seconds, with calibration performed using a light dosimeter (LaserMate-Q®, Coherent, USA). Post-treatment, patients were advised to avoid sunlight and bright indoor lighting for 30 days and were provided with sunscreen (Anessa®, Shiseido, Japan) to prevent photosensitivity reactions.

Immunological evaluations

Peripheral blood (10 mL) was collected from all patients at baseline (T0), 7 days post-treatment (T1), and 30 days post-treatment (T2). Blood samples were centrifuged at 400×g for 10 minutes at 4°C using a Heraeus™ Labofuge 400R (Thermo Fisher Scientific, USA). Plasma aliquots were then stored at -80°C until further analysis. To isolate mononuclear

cells, Ficoll-Paque PLUS (GE Healthcare, USA) was used. The cells were stained with fluorochrome-conjugated monoclonal antibodies targeting CD3 (FITC), CD4 (PE), CD8 (APC), CD25 (PerCP), and FoxP3 (PE-Cy7), all from BioLegend (USA). These stained samples were analyzed using a BD FACSCanto II Flow Cytometer (BD Biosciences, USA), and data interpretation was carried out with FlowJo software (v10.8, Tree Star Inc., USA).

Natural killer (NK) cell cytotoxicity was assessed using the CytoTox 96® Non-Radioactive Cytotoxicity Assay Kit (Promega, USA), which quantifies lactate dehydrogenase (LDH) release. PBMCs were co-cultured with K562 target cells (ATCC, USA) at effector-to-target ratios of 10:1 and 20:1 for 4 hours at 37°C.

Cytokine analysis

Plasma levels of IL-2, IL-6, IL-10, IFN- γ , and TNF- α were measured using multiplex ELISA kits (Human Th1/Th2 Cytokine Kit II, BD OptEIA™, BD Biosciences, USA). The readings were taken using an Infinite M200 PRO microplate reader (Tecan Group Ltd., Switzerland) according to the manufacturer's instructions.

Clinical monitoring and follow-up

Patients were followed clinically for six months post-treatment. Surveillance endoscopy was performed at 3 and 6 months to assess for recurrence, which was defined as the presence of histologically confirmed malignant tissue at the original EMR site or adjacent mucosa. Adverse events, including bleeding, infection, perforation, and photosensitivity reactions, were documented and graded using the Common Terminology Criteria for Adverse Events (CTCAE) version 5.0.

Statistical analysis

Statistical analyses were performed using SPSS version 26.0 (IBM Corp., USA). Continuous variables were presented as mean \pm standard deviation and compared using independent-samples t-test or repeated measures ANOVA, as appropriate. Categorical data were analyzed using the Chi-square test or Fisher's exact test. A P-value <0.05 was considered statistically significant.

RESULTS

Baseline demographic and clinical characteristics

A total of 120 patients were enrolled in the study, with 60 allocated to the EMR-only group and 60 to the EMR+PDT group. The baseline demographic and tumor characteristics were statistically comparable between the two groups, ensuring balanced cohorts for subsequent comparisons. There were no significant differences in mean age (65 ± 10 years vs. 64 ± 11 years, $P=0.45$), sex distribution (40/20 vs.

38/22, $P=0.67$), tumor size (15 ± 5 mm vs. 16 ± 6 mm, $P=0.32$), or incidence of positive surgical margins (13% vs. 12%, $P=0.75$). Baseline patient characteristics is shown in table 1. These data confirm that any observed differences in outcomes were unlikely due to selection bias.

Table 1. Baseline patient characteristics.

Characteristic	EMR Only (n=60)	EMR+PDT (n=60)	p-value
Mean Age (years)	65 ± 10	64 ± 11	0.45
Male/Female Ratio	40 / 20	38 / 22	0.67
Tumor Size (mm)	15 ± 5	16 ± 6	0.32
Positive Margins	8 (13%)	7 (12%)	0.75

Peripheral T lymphocyte subset changes

Immunophenotyping revealed significant modulation of T cell populations in the EMR+PDT group. At day 7 and day 30 post-treatment, there was a marked and sustained increase in circulating CD8⁺ cytotoxic T lymphocytes. The mean CD8⁺ percentage increased from $24.7\% \pm 2.9\%$ at baseline to $35.6\% \pm 3.5\%$ by day 30 ($P<0.001$), compared to a non-significant change in the EMR-only group (from $24.3\% \pm 3.0\%$ to $26.2\% \pm 3.2\%$, $P>0.05$).

In parallel, the CD4⁺CD25⁺FoxP3⁺ regulatory T cell (Treg) population significantly declined in the PDT group, dropping from $8.4\% \pm 1.2\%$ to $5.6\% \pm 1.1\%$ by day 30 ($P<0.01$), indicating a shift away from immunosuppressive T cell dominance. These changes resulted in a decreased CD4⁺/CD8⁺ ratio (from 1.87 ± 0.26 to 1.12 ± 0.19), signifying an enhanced cytotoxic T cell response. No significant alterations in T cell subset ratios were observed in the EMR-only group. Figure 1 shows the percentage of CD8⁺ cytotoxic T lymphocytes in the EMR + PDT and EMR-only groups at baseline and day 30. The EMR + PDT group experienced a significant increase in CD8⁺ T cells, indicating enhanced cytotoxic immune responses, while the EMR-only group showed no significant change.

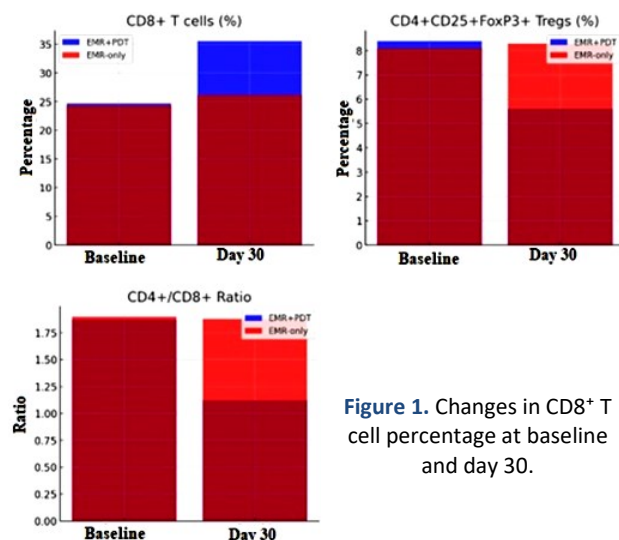


Figure 1. Changes in CD8⁺ T cell percentage at baseline and day 30.

Serum cytokine profiles

Serum cytokine assays conducted at three time points (baseline, day 7, day 30) revealed significant

upregulation of Th1-type immune responses in the EMR + PDT group.

- **IFN- γ** : A critical cytokine for antitumor immunity, IFN- γ levels rose from 9.2 ± 2.1 pg/mL at baseline to 18.6 ± 3.4 pg/mL at day 30 ($P < 0.001$).
- **IL-2**: Increased from 15.3 ± 3.7 pg/mL to 24.8 ± 4.2 pg/mL ($P < 0.01$), suggesting enhanced T cell proliferation and activation.
- **TNF- α** : Elevated from 12.1 ± 2.6 pg/mL to 19.7 ± 3.9 pg/mL ($P < 0.05$), contributing to tumor cytotoxicity and inflammation.

Table 2 shows the serum levels of various cytokines at baseline and day 30. The EMR + PDT group exhibited significant increases in pro-inflammatory cytokines (IFN- γ , IL-2, TNF- α) and significant decreases in immunosuppressive cytokines (IL-10, IL-6), whereas no such changes were observed in the EMR-only group.

Table 2. Serum cytokine levels at baseline and day 30.

Cytokine	Group	Baseline (pg/mL)	Day 30 (pg/mL)	P-value
IFN- γ	EMR + PDT	9.2 ± 2.1	18.6 ± 3.4	< 0.001
	EMR Only	9.3 ± 2.3	9.5 ± 2.1	> 0.05
IL-2	EMR + PDT	15.3 ± 3.7	24.8 ± 4.2	< 0.01
	EMR Only	15.5 ± 3.6	15.4 ± 3.9	> 0.05
TNF- α	EMR + PDT	12.1 ± 2.6	19.7 ± 3.9	< 0.05
	EMR Only	12.0 ± 2.4	12.2 ± 2.7	> 0.05
IL-10	EMR + PDT	11.4 ± 3.1	6.2 ± 2.2	< 0.01
	EMR Only	11.2 ± 3.0	11.3 ± 3.2	> 0.05
IL-6	EMR + PDT	13.9 ± 4.3	8.7 ± 3.5	< 0.05
	EMR Only	13.7 ± 4.1	13.8 ± 4.2	> 0.05

Conversely, immunosuppressive cytokines such as IL-10 declined significantly (from 11.4 ± 3.1 pg/mL to 6.2 ± 2.2 pg/mL, $P < 0.01$), as did IL-6 (a pleiotropic cytokine often associated with cancer progression), which dropped from 13.9 ± 4.3 pg/mL to 8.7 ± 3.5 pg/mL ($P < 0.05$) by day 30 in the PDT group. These findings suggest a favorable immunological shift toward a pro-inflammatory, anti-tumor microenvironment post-PDT. In contrast, cytokine levels in the EMR-only group remained relatively unchanged at all time points. The bar graph presented as figure 2 compares the levels of five key cytokines (IFN- γ , IL-2, TNF- α , IL-10, and IL-6) in serum at baseline and day 30 for both the EMR + PDT and EMR-only groups. The EMR + PDT group showed significant increases in pro-inflammatory cytokines (IFN- γ , IL-2, TNF- α) and decreases in immunosuppressive cytokines (IL-10, IL-6), indicating a favorable immune shift post-treatment.

NK cell cytotoxicity

Assessment of natural killer (NK) cell activity showed a significant enhancement in the EMR + PDT group. Using LDH-based cytotoxicity assays, NK cell-mediated lysis of K562 target cells increased from $26.8\% \pm 4.1\%$ at baseline to $39.2\% \pm 5.7\%$ at day 30 ($P < 0.01$). The EMR-only group showed a marginal increase from $27.1\% \pm 4.5\%$ to $30.2\% \pm 4.6\%$ ($P = 0.08$), which was not statistically significant. This indicates

that PDT stimulated both innate (NK cell) and adaptive (T cell) immune responses. Figure 3 illustrates the NK cell cytotoxicity percentages at baseline and day 30 for both groups. The EMR + PDT group demonstrated a significant increase in NK cell-mediated cytotoxicity, indicating enhanced innate immune response, while the EMR-only group showed a smaller, statistically insignificant increase.

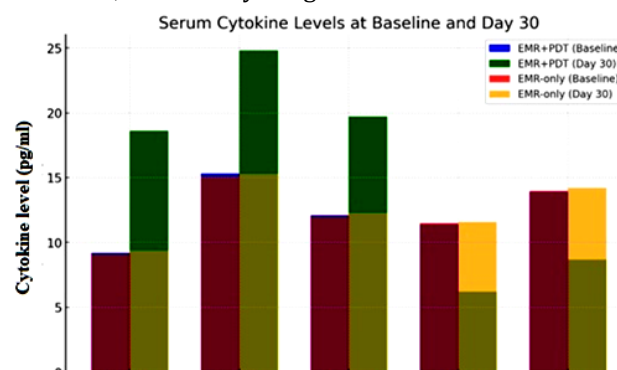


Figure 2. Serum cytokine levels at baseline and day 30.

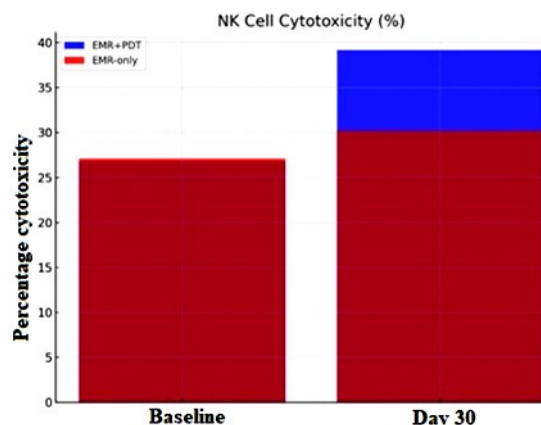


Figure 3. NK Cell Cytotoxicity at Baseline and Day 30

Tumor recurrence outcomes

Endoscopic surveillance at 3- and 6-months post-treatment identified significant differences in tumor recurrence rates. In the EMR-only group, 11 patients (18%) developed local recurrence confirmed by histopathology. In contrast, only 3 patients (5%) in the EMR + PDT group experienced recurrence ($P = 0.01$) (table 3). These findings suggest that PDT contributes not only to immediate cytotoxicity but also to durable immunological tumor control.

Table 3. Six-month local tumor recurrence rates.

Group	Recurrence (n/%)	p-value
EMR Only	11/60 (18%)	0.01
EMR + PDT	3/60 (5%)	

Adverse events and safety profile

Results of post-treatment adverse events is shown in table 4. The overall incidence of treatment-related adverse events was significantly lower in the EMR + PDT group. No Grade ≥ 3 toxicities were reported in either group. The PDT group reported only minor adverse effects, including transient skin

photosensitivity (n=5), mild post-procedural abdominal pain (n=3), and minor post-EMR bleeding (n=1), all of which resolved with conservative management.

In the EMR-only group, complications were more frequent and included infection (n=6), abdominal pain (n=8), delayed bleeding (n=5), and perforation requiring endoscopic clipping (n=3).

Table 4. Post-treatment adverse events.

Adverse Event	EMR Only (n=60)	EMR + PDT (n=60)	p-value
Infection	6	2	<0.05
Abdominal Pain	8	3	<0.05
Bleeding	5	1	<0.05
Perforation	3	1	<0.05
Photosensitivity	0	5	N/A
Total Events	22 (36.7%)	7 (11.7%)	<0.05

DISCUSSION

Endoscopic mucosal resection (EMR) has become a cornerstone in the treatment of early-stage gastrointestinal cancers (EGIC), offering a minimally invasive alternative to traditional surgical approaches. However, recurrence rates following EMR, while relatively low, remain a clinical concern, reported to range from 0.7% to 2.3% depending on lesion characteristics and resection completeness⁽¹³⁾. Several factors have been associated with recurrence, including tumor size, depth of invasion, presence of positive margins, and residual dysplasia or neoplastic tissue⁽¹⁴⁾. Despite advances in endoscopic techniques such as endoscopic submucosal dissection (ESD), which improves embolic resection rates, incomplete or microscopic residual lesions still occur in up to 14% of cases, particularly in challenging anatomical locations⁽¹⁵⁾.

Photodynamic therapy (PDT) represents a complementary modality that can address these limitations. By using tumor-selective photosensitizers and targeted light exposure, PDT induces local cytotoxicity via reactive oxygen species while sparing surrounding healthy tissue. Importantly, PDT is not only a local ablative therapy but also a potent inducer of immunogenic cell death (ICD)—a process that enhances systemic anti-tumor immunity through the release of danger signals and tumor-associated antigens^(16, 17).

In countries such as Japan, South Korea, and the United States, PDT has gained regulatory approval for the palliative treatment of esophageal and other GI malignancies^(15, 16). However, its use in early-stage disease as an adjunct to EMR remains underexplored. The present study provides evidence that combining PDT with EMR in EGIC patients not only reduces recurrence but also enhances systemic immune responses—thus offering both local control and immune-mediated tumor surveillance.

Our results demonstrated a significant reduction in local tumor recurrence in the EMR+PDT group

(5%) compared to the EMR-only group (18%) at 6 months, aligning with the hypothesis that PDT augments oncologic efficacy beyond the immediate resection zone. This finding suggests that PDT may eradicate microscopic residual lesions or pre-malignant fields surrounding the resected area, which might otherwise escape endoscopic visualization or histological sampling.

From an immunological standpoint, PDT-induced immune activation was evident through multiple parameters. Flow cytometry revealed a marked increase in cytotoxic CD8⁺ T lymphocytes, coupled with a decline in regulatory T cells (Tregs), indicating a favorable shift in the tumor-immune microenvironment. These changes were supported by significant upregulation of Th1-associated cytokines, particularly IFN- γ , IL-2, and TNF- α , all of which play central roles in anti-tumor immunity and cytotoxic T cell activation. Additionally, IL-10, a key immunosuppressive cytokine frequently elevated in cancer, was significantly reduced after PDT exposure, suggesting a reversal of the immunosuppressive milieu typically associated with tumor progression⁽¹⁶⁻¹⁸⁾. Natural killer (NK) cell activity was also significantly enhanced in the PDT group, further supporting the role of PDT in stimulating both innate and adaptive immunity. This multi-arm immune activation likely contributes to both the reduction in recurrence and the systemic anti-tumor surveillance seen in our study⁽¹⁹⁾.

Our safety analysis confirmed that PDT was well tolerated, with only mild and reversible adverse effects such as transient photosensitivity and abdominal discomfort. No grade ≥ 3 toxicities were observed, reinforcing PDT's role as a safe adjunct therapy when administered under controlled conditions with appropriate light shielding measures⁽²⁰⁾.

Collectively, these findings support a model in which EMR provides mechanical tumor removal, while PDT complements it by sterilizing residual tumor cells and triggering systemic immune responses. This dual mechanism addresses both the anatomical and biological aspects of cancer recurrence. These findings are consistent with emerging preclinical and clinical studies suggesting that ICD-inducing therapies, such as PDT, can serve as *in situ* cancer vaccines, priming the immune system for long-term tumor surveillance^(17, 21). This concept has significant implications not only for recurrence prevention in early-stage cancers but also for enhancing the efficacy of immune checkpoint blockade in advanced disease settings^(22, 23).

While the present study provides compelling evidence for the immunomodulatory and clinical benefits of PDT, it has several limitations. First, our follow-up duration was limited to 6 months, and longer-term outcomes such as overall survival and immune memory persistence remain to be assessed.

Second, while peripheral immune markers were measured, direct evidence of tumor-infiltrating lymphocyte changes or antigen-specific T cell responses was not evaluated. Future studies incorporating tumor biopsies, T cell receptor sequencing, and functional T cell assays would be valuable in elucidating the full immunological cascade initiated by PDT.

CONCLUSION

In summary, this study demonstrates that the combination of endoscopic mucosal resection with photodynamic therapy in patients with early-stage gastrointestinal cancer not only enhances local tumor control but also stimulates systemic anti-tumor immunity, as evidenced by increased CD8⁺ T cells, elevated Th1 cytokines, and reduced regulatory immune mechanisms. The treatment was safe, effective, and associated with a significantly lower recurrence rate compared to EMR alone. These results support the integration of PDT as a novel immuno-oncologic adjunct in the minimally invasive management of early gastrointestinal cancers.

Acknowledgments: We thank the staff of the 900th Hospital of Joint Logistics Support Force for support in patient care and data collection.

Conflicts of Interest: The authors declare no conflicts of interest.

Ethical Approval: This study was approved by the Ethics Committee of the 900th Hospital of Joint Logistics Support Force. Informed consent was obtained from all participants.

Funding: Supported by the Fujian Provincial Science and Technology Department (2022Y01010219).

Author Contributions: B.X. and M.Q.: Conceptualization, supervision. S.J. and J.M.: Data analysis. Y.X. and S.C.: Writing and revisions.

Data Availability: Available upon reasonable request.

REFERENCES

- Nishiguchi A, Kurihara Y, Taguchi T (2019) Underwater-adhesive microparticle dressing composed of hydrophobically-modified Alaska pollock gelatin for gastrointestinal tract wound healing. *Acta Biomater*, **99**: 387-96.
- Zhang H, Zhao C, Song C, Wu Y, Wei D, Li X (2023) Knowledge, attitude, and practice of healthcare workers on early gastrointestinal cancer in China. *Front Public Health*, **11**: 1191699.
- Ben-Aharon I, van Laarhoven HWM, Fontana E, Obermannova R, Nilsson M, Lordick F (2023) Early-onset cancer in the gastrointestinal tract is on the rise-evidence and implications. *Cancer Discov*, **13**(3): 538-51.
- Weinberg BA, Murphy CC, Freyer DR, Greathouse KL, Blancato JK, Stoffel EM, *et al.* (2025) Rethinking the rise of early-onset gastrointestinal cancers: a call to action. *JNCI Cancer Spectr*, **9**(1): pkaf002.
- Yanagida M, Hosoi Y, Kawano T, Otake Y, Yamanaka Y, Baba T, *et al.* (2024) Noniatrogenic meningitis caused by streptococcus salivarius associated with early esophageal cancer and early gastric cancer. *Intern Med*, **63**(3): 457-60.
- Park CH, Yang DH, Kim JW, Kim JH, Kim JH, Min YW, *et al.* (2020) Clinical practice guideline for endoscopic resection of early gastrointestinal cancer. *Clin Endosc*, **53**(2): 142-66.
- Du Y, Zhu H, Liu J, Li J, Chang X, Zhou L, *et al.* (2020) Consensus on eradication of Helicobacter pylori and prevention and control of gastric cancer in China (2019, Shanghai). *J Gastroenterol Hepatol*, **35**(4): 624-9.
- Patil M, Jr., Gharde P, Reddy K, Nayak K (2024) Comparative analysis of laparoscopic versus open procedures in specific general surgical interventions. *Cureus*, **16**(2): e54433.
- Feng Q, Yu C, Li R, Ren Q, Xie F, Chen S, *et al.* (2023) The efficacy and safety of endoscopic mucosal dissection for early gastrointestinal cancer and precancerous lesions. *J Gastrointest Oncol*, **14**(6): 2671-2.
- Shi B, Wang L, Huang S (2021) Effect of high-quality nursing on psychological status and prognosis of patients undergoing brain tumor surgery. *Am J Transl Res*, **13**(10): 11974-80.
- Shi L, Wang L, Cui Q (2021) The clinical effects of high-quality nursing interventions after a diagnosis of upper gastrointestinal bulging lesions with mEUS. *Am J Transl Res*, **13**(8): 9655-62.
- Oosterveld-Vlug MG, Custers B, Hofstede J, Donker GA, Rijken PM, Korevaar JC, *et al.* (2019) What are essential elements of high-quality palliative care at home? An interview study among patients and relatives faced with advanced cancer. *BMC Palliat Care*, **18**(1): 96.
- Nishiguchi A, Sasaki F, Maeda H, Kabayama M, Ido A, Taguchi T (2019) Multifunctional hydrophobized microparticles for accelerated wound healing after endoscopic submucosal dissection. *Small*, **15**(35): e1901566.
- Yin L (2023) The application value of the clinical nursing pathway for patients with head and neck cancer. *J Cancer Res Clin Oncol*, **149**(12): 9629-34.
- Kelly R, Gordon P, Thompson R, Semple C (2023) Availability and use of web-based interventions for patients with head and neck cancer: a scoping review. *J Cancer Surviv*, **17**(5): 1309-26.
- Harrington KJ, Affronti ML, Schneider SM, Razzak AR, Smith TJ (2019) Improving Attitudes and perceptions about end-of-life nursing on a hospital-based palliative care unit. *J Hosp Palliat Nurs*, **21**(4): 272-9.
- Wen FH, Chou WC, Hou MM, Su PJ, Shen WC, Chen JS, *et al.* (2022) Caregivers' death-preparedness states impact caregiving outcomes and patients' end-of-life care. *J Pain Symptom Manage*, **63**(2): 199-209.
- Wang M, Sun Y, Zhang M, Yu R, Fu J (2022) Effects of high-quality nursing care on quality of life, survival, and recurrence in patients with advanced nonsmall cell lung cancer. *Medicine (Baltimore)*, **101**(37): e30569.
- Alvero AB, Fox A, Madina B, Krady M, Gogoi R, Chehade H, *et al.* (2023) Immune modulation of innate and adaptive responses restores immune surveillance and establishes anti-tumor immunological memory. *bioRxiv*.
- Jin P, Sun LL, Li BX, Li M, Tian W (2022) High-quality nursing care on psychological disorder in ovarian cancer during perioperative period: A systematic review and meta-analysis. *Medicine (Baltimore)*, **101**(27): e29849.
- Zhang L, Zhang X, Cui Z, Zhou L, Qu K, Wang N (2020) Effects of high-quality nursing care on psychological outcomes and quality of life in patients with hepatocellular carcinoma: A protocol of systematic review and meta-analysis. *Medicine (Baltimore)*, **99**(35): e21855.
- He XL and Cao ZM (2020) Effect of high-quality nursing intervention on the psychological disorder in patients with gastric cancer during perioperative period: A protocol of systematic review and meta-analysis. *Medicine (Baltimore)*, **99**(23): e20381.
- Cui Y and Li YX (2020) Effect of high-quality nursing on alleviating depression and anxiety in patients with thyroid cancer during perioperative period: A protocol for systematic review. *Medicine (Baltimore)*, **99**(45): e23018.