

Primary retroperitoneal Ewing's sarcoma in a young woman: A case report

Z. Zhang, W. Wang, H. Wang*

Department II of Gynecology, Affiliated Hospital of Shandong Second Medical University, School of Clinical Medicine, Shandong Second Medical University, Weifang, Shandong Province, China

► Case report

ABSTRACT

*Corresponding author:

Hui Wang, M.D.,

E-mail: wanghui201@163.com

Received: February 2025

Final revised: April 2025

Accepted: May 2025

Int. J. Radiat. Res., October 2025;
23(4): 1131-1135

DOI: 10.61186/ijrr.23.4.42

Keywords: Ewing sarcoma, retroperitoneal space, primary neoplasms, radiotherapy, case report.

Ewing's sarcoma (EWS) is a rare malignant tumour that is more likely to occur in children and young people, especially in people of European ancestry, with an annual incidence rate of one in a million, and the incidence of extra-skeletal EWS is even lower, among which retroperitoneal EWS is advanced once detected because of the deep location of the lesion and other characteristics, which makes treatment difficult. The following case report describes an EWS in the retroperitoneal region in a young healthy female patient. A 28-year-old young female patient with a negative family history underwent gynaecologic ultrasound examination for difficulty in defaecation and lower abdominal pain, which revealed a solid cystic mass behind the cervix, tenderness of the mass, and compression of the vagina and rectum. Therefore, surgery was recommended. A retroperitoneal tumour was found during intraoperative exploration, and laparoscopic surgery was changed to open surgery. Postoperative pathology suggested EWS. After postoperative radiation therapy and close follow-up, tumour recurrence occurred six months after surgery, and bone metastasis occurred one year after surgery. Retroperitoneal EWS is a rare and poorly documented disease. Radical surgery remains the first-line treatment of this disease.

INTRODUCTION

EWS family of tumours (ESFT) is a group of small, round blue tumours associated with tissue genetics, all of which present with non-random t(11:22) (q24;q12) chromosome rearrangement, leading to the formation of EWS-ETS fusion genes ⁽¹⁾. Ewing's sarcoma (EWS) is one of the well-known solid tumours in ESFT, which usually occurs in bones and soft tissues ⁽²⁾. The incidence rate is one in a million, with male patients accounting for about 55%-60% of the total cases, and nearly 60% of the patients are between the ages of 10-20. The incidence of extra-skeletal (ES-EWS) is even lower, accounting for 6-47% of all EWS ⁽³⁾. Among them, 14% of the EWS occur in the trunk, 14% in the abdominal tissue or retroperitoneum, 8% in the internal organs, and 21% in other parts.

Primary retroperitoneal EWS is characterised by deep location of the lesion, large volume, and delayed appearance of clinical symptoms and signs. Once found, the tumour size can reach more than 8 cm or even 25 cm ⁽⁴⁾.

According to reported cases of retroperitoneal EWS clinical manifestations vary. Some patients experience abdominal, waist, and sacroiliac joint pain, while some experience symptoms of gastrointestinal obstruction such as abdominal discomfort, flatulence, and vomiting. In addition, in some patients' palpation of the tumour or imaging

examination reveal the presence of the tumour, but they experience no discomfort. This is related to the specific location of the tumour, and most patients experience short-term weight loss ^(1, 2, 5-7).

In this study, we present a case study of primary retroperitoneal Ewing's sarcoma in a young female patient, detailing its diagnostic and therapeutic management. The report underscores the critical importance of early detection and multidisciplinary treatment approaches, with the dual objectives of advancing clinical recognition of this rare neoplasm and providing evidence-based references for optimizing oncological practice.

Case presentation

A 28 years old married female without any chronic medical illnesses initially presented to the gynaecology department at the Affiliated Hospital of Shandong Second Medical University in Weifang, Shandong Province, China in January 2021 with 15 d of difficulty with bowel movements and 10 d of lower abdominal pain. The patient reported that defaecation and urination became more difficult with time, intermittent lower abdominal distending pain was aggravated during exercise and defaecation, and no other discomfort was noted. Gynaecological physical examination: Vulva development was normal, no loss of skin pigment, no growth, and vaginal compression was identified; however, cervical exposure was difficult; a mass with a

diameter of approximately 10 cm was felt on the pelvic floor, with large tension, inactivity, tenderness, compression of the vagina, and rectum.

The gynecological ultrasound examination performed with the Philips EPIQ7 system (equipped with a C5-1 broadband convex transducer, frequency range 1-5 MHz, curvature radius 50 mm) in B-mode imaging demonstrated the following findings: an anteverted uterus measuring $4.6 \times 3.9 \times 3.5$ cm, and a well-circumscribed complex cystic-solid mass ($9.3 \times 8.9 \times 9.5$ cm) posterior to the cervix with regular morphology, showing punctate vascular signals within its solid component (figure 1A). After admission, the tumour index carcinoembryonic antigen (CEA) was 32.03 ng/mL (reference range 0–10 ng/mL). The levels of other tumour indicators were normal. The patient underwent non-contrast and contrast-enhanced CT of the entire abdomen following oral administration of iohexol (total dose 800 mL, concentration 9 g/L) and intravenous bolus injection of non-ionic iodinated contrast medium (iohexol, 100 mL, concentration 350 mgI/mL) using a GE (General Electric), USA-manufactured Discovery CT750 HD Gemstone Spectral CT scanner, revealing an irregular mass with mixed cystic-solid composition posterior to the uterus demonstrating marked heterogeneous enhancement in solid components and non-enhancing cystic portions, exhibiting ill-defined borders with the cervix, rectal compression, and obliteration of pelvic fat planes (figure 1B). Colonoscopy revealed an external pressure bulge in the rectum. Gastroscopy revealed multiple gastric polyps, bite, and chronic superficial gastritis. Pathological findings: (stomach) fundus glandular polyps.

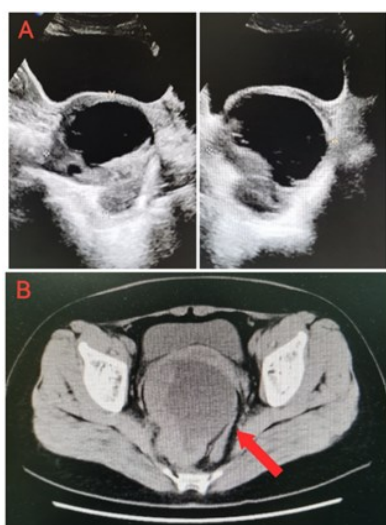


Figure 1. (A) Gynecologic color ultrasound revealed a solid cystic mass about $9.3 \times 8.9 \times 9.5$ cm in size behind the cervix. **(B)** Whole abdomen and pelvis non-contrast and contrast-enhanced CT scans demonstrate an irregular cystic-solid mass posterior to the uterus, showing ill-defined demarcation from the cervix. The solid components exhibit marked heterogeneous enhancement.

After preoperative evaluation, the patient underwent laparotomy and extensive total hysterectomy. The bilateral fallopian tubes and retroperitoneal masses were removed while the

bilateral ovaries were preserved. Intraoperatively, a tumour approximately 10 cm in diameter was observed in the posterior and lower parts of the uterine body, extending down to the vaginorectal septum, right side of the rectum, and behind the rectum. The operation was successful, and the postoperative recovery was good.

The postoperative specimen was fixed in 10% neutral buffered formalin, routinely dehydrated, paraffin-embedded, sectioned at $4\mu\text{m}$ thickness, and subjected to hematoxylin and eosin (HE) staining. Immunohistochemical staining was performed using the EnVision two-step method with antibodies purchased from DAKO Company and Beijing Zhongshan Golden Bridge Biotechnology Co., Ltd., following the manufacturer's instructions for the reagent kits. Observation under an Olympus BX43FC microscope revealed: a small round cell malignant tumor. Immunohistochemical results showed CD99 (3+), Ki67 positivity rate of 40%, negative staining for NSE and other markers (figure 2). Supplementary staining for FLT (+) performed during consultation at a superior hospital confirmed the diagnosis as consistent with peripheral primitive neuroectodermal tumor (pPNET), at which point the tumour was staged as $T_{2b}N_0M_0$.

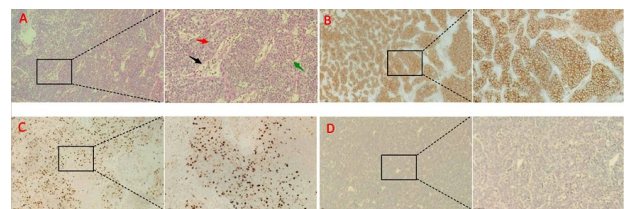


Figure 2. (A) The tumor is composed of extensive sheets of small to medium-sized round and oval cells with well-defined cell borders. The nuclei exhibit hyperchromasia, distinct nuclear membranes, and conspicuous small round nucleoli centrally located within the nuclei. The stromal blood vessels demonstrate a slit-like pattern of distribution, accompanied by focal areas of vascular dilation. The black arrow indicates the dilated stag-horn-like blood vessels. The red arrow points to round or oval cells with enlarged hyperchromatic nuclei. The green arrow highlights apoptotic cells; **(B)** Immunohistochemical staining for CD99 demonstrates strong membranous positivity; **(C)** Immunohistochemical staining for Ki67 demonstrates strong nuclear positivity, indicative of a high proliferative activity, with approximately 40% of tumor cells showing immunoreactivity; **(D)** Immunohistochemical staining for NSE demonstrates negative expression.

The patient commenced adjuvant interventional therapy on postoperative day 30, undergoing CT three-dimensional reconstruction-guided regional chemotherapy targeting bilateral internal iliac arteries at 28 ± 3 -day intervals. The entire procedure utilized a right femoral artery approach. Following local anaesthesia, a 5F arterial sheath was inserted using the Seldinger technique, with an RH catheter precisely super selected into the main trunks of bilateral internal iliac arteries under real-time CT guidance. Methylprednisolone (cumulative 40mg),

tropisetron (cumulative 5mg), and pirarubicin (cumulative 60mg)—were sequentially infused through bilateral vessels. Unilateral perfusion rates were strictly controlled at ≥ 15 minutes per side to ensure regional drug distribution. The protocol was completed over four cycles, with treatment intervals dynamically adjusted based on imaging and laboratory evaluations. On September 9, 2021, the patient underwent pelvic MRI examination using the Philips Prodiva 1.5T CX 1.5T superconducting magnetic resonance imaging system (magnetic field strength of 1.5T, gradient system parameters: maximum gradient field strength of 33 mT/m, gradient slew rate of 160 T/m/s, 16-channel digital radiofrequency reception system, slice thickness resolution ≤ 3.0 mm) manufactured by Philips Healthcare (Suzhou) Co., Ltd., Netherlands. Imaging findings revealed: a round long T1 signal and a slightly longer T2 signal around the rectum, which was indistinct from the local boundary of the rectum, the size was approximately 4.9 cm \times 3.3 cm; the DWIBS signal was enhanced and the ADC image showed a low signal, which was considered tumour recurrence (figure 3). In addition, multiple significantly enlarged lymph nodes were observed in front of the sacrum, with a diameter of approximately 2.2 cm, DWIBS signals were significantly enriched, which was consistent with lymph node metastasis, and the tumour was staged as T_{2b}N₁M₀.

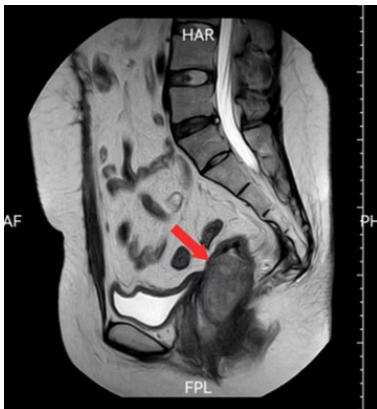

Figure 3. Pelvic magnetic resonance imaging revealed pelvic postoperative changes, soft tissue mass around the rectum, about 4.9cm \times 3.3cm, the DWIBS signal is intensified, suggesting tumor recurrence.

The patient underwent CT-guided Iodine-125 radioactive seed implantation. Using the same CT model and scanning parameters as previous examinations for three-dimensional localization, five puncture targets were identified. Under real-time imaging guidance, percutaneous implantation of radioactive seeds (0.7 mCi per seed) was performed, with dynamic adjustment of puncture trajectories to achieve conformal distribution within the gross tumour volume (GTV). The initial treatment delivered 85 seeds with 8-10 mm spacing, achieving a matched peripheral dose (MPD) of 145 Gy. Two months after the initial implantation, supplementary implantation of 39 seeds to elevate the biologically effective dose (BED) to 180 Gy. The entire procedure adhered to ESTRO/ABS guidelines for quality assurance, with

standard post-procedural management of puncture sites and radiation safety monitoring.

The MRI results of the patient's entire abdomen and pelvis on December 30, 2021 (using the same MRI model and scanning parameters as previous examinations) showed: multiple irregular and slightly long T1 and T2 signals around the rectum, bladder, anus, and pelvic floor, which were indistinct from the surrounding structures. The size of the larger one was about 7.6 cm \times 5.8 cm, the DWIBS signal was enhanced, and the ADC image showed low signal. The tumour was larger than that before the procedure. In addition, multiple long T1 and T2 signal shadows of the patella were observed in the thoracolumbar spine, bilateral ilia, and sacrum, and the DWIBS signal was obviously enriched, which was consistent with bone metastasis (figure 4). The tumour was staged as T_{2b}N₁M₁. The patient subsequently underwent another session of internal iliac artery infusion chemotherapy (following the same protocol as the previous procedure). During the procedure, a total of 40mg Methylprednisolone, 5mg Tropisetron, 60mg Pirarubicin, and 120mg Cisplatin injection were slowly infused. In February 2022, an additional 120 radioactive seeds were implanted as supplementary treatment within the tumor tissue.

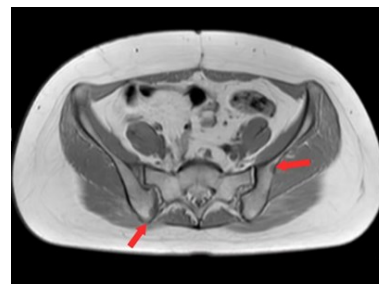

Figure 4. Pelvic magnetic resonance imaging revealed multiple patchy long T1 and long T2 signal shadows in both iliac and sacral bones, suggestive of multiple bone metastases in the tumor.

During the course of postoperative treatment, tumour indicators were reviewed several times, and all were within the normal range.

The patient was lost to follow-up in March 2022.

DISCUSSION

Retroperitoneal EWS has no specific symptoms or signs and is difficult to detect in the early stages of the disease, in this case, the tumor diameter was also over 9cm when the patient was found, and it was not clearly diagnosed before surgery. However, most retroperitoneal masses can be detected during gynaecological or digital rectal examinations, therefore, we recommend regular physical check-up's, and imaging examinations, if necessary. To promote the early detection, intervention, and treatment of the disease, improve the prognosis of patients, and prolong their life cycle.

Magnetic resonance imaging (MRI) is the imaging modality of choice for describing the extent of the tumour and its relationship with adjacent soft tissues

and blood vessels ⁽¹⁾. However, because of the extensible nature of the retroperitoneal space, MRI is not the ultimate diagnostic tool, as it may blur the details of these masses, and no radiologically specific presentation is known to distinguish retroperitoneal EWS from other retroperitoneal tumours. Pathological examination remains the gold standard for the diagnosis of this disease.

From the perspective of immunohistochemistry, CD99 and vimentin were stably expressed in ES-EWS; in this case, CD99(3+). The nuclear proliferation-associated antigen Ki67 reflects the proliferative activity of the tumour, and the positive rate in this case was 40%, indicating a poor prognosis. Expression of NSE, Syn, and CgA was negative. Chromosomal translocation leading to the EWSR1-ETS fusion gene is a characteristic molecular change in Ewing sarcoma, approximately 85–90% of patients have chromosomal translocation t (11; 22) (q24; q12), which causes EWSR1-FLI1 fusion. This fusion can induce the expression of oncogenes while inhibiting the transcription of some genes and also affects the expression of non-coding RNA in various ways, inhibiting gene expression and promoting tumourigenesis and the heterogeneity of EWS ⁽⁸⁾. It can be detected through FISH and other methods. A positive FLI-1 test result is highly substantial for the diagnosis of EWS/PNET, and in this case, FLI-1 (+).

Chemotherapy is beneficial to patients' conditions, but the therapeutic effect of chemotherapy alone is limited. Compared to surgery alone, preoperative chemotherapy offers advantages in terms of survival rate, quality of life, and prognosis for patients. Therefore, it is not recommended for Ewing sarcoma patients to solely undergo chemotherapy or surgery.

At present, patients with EWS should adopt a plan for "local control therapy and adjuvant therapy after initial treatment". The initial treatment was a multi drug chemotherapy regimen with at least nine weeks of appropriate growth factor support. After the initial treatment, patients with stable or improved conditions should receive local control therapy, including extensive surgical resection, radical radiotherapy combined with chemotherapy, and amputation in specific cases. All patients are recommended to undergo adjuvant chemotherapy after extensive resection or amputation, regardless of the surgical margins. The duration of chemotherapy should be between 25–49 weeks to improve the recurrence-free survival (RFS) and overall survival (OS) in most patients. For patients with positive postoperative margins or margins that are very close to the tumour, postoperative radiotherapy should be added to chemotherapy ⁽⁹⁾.

Nearly 70% of EWS recurrences occur early, with 2/3 occurring in the distal region (lungs and/or bones). For 15–20% of patients with isolated local recurrence, such as surgery or radiation therapy,

may improve the prognosis. For patients with recurrent or refractory bone tumours, combination chemotherapy with topoisomerase I inhibitors (Topotecan, Irinotecan), cyclophosphamide, and temozolomide has a good response rate, but there is no consensus on which chemotherapy regimen is superior ⁽¹⁰⁾. For patients with bone metastases, a strategy for attaching traditional drugs to bone-targeted fragments (such as bisphosphonates or oligopeptides) is currently available, which can considerably increase their local concentrations. Many small-molecule drugs and several protein drugs with bone-targeting potential have been studied for their anticancer properties; however, these drugs are still in the preclinical or clinical trial stage ⁽¹¹⁾.

In addition, all patients with recurrent and metastatic EWS should consider participating in clinical trials investigating new treatment methods, such as targeted therapy and immunotherapy.

Acknowledgment: None.

Consent to publish: The manuscript has neither been previously published nor is under consideration by any other journal. The authors have all approved the content of the paper.

Consent to participate: We secured a signed informed consent form from every participant.

Ethic Approval: This experiment was approved by Affiliated Hospital of Shandong Second Medical University Ethics Committee (No. wyfy-2024-ky-412).

Funding: None.

Author Contribution: Z.Z.: The first author collected the data, wrote the case report, conducted the literature review, and wrote the discussion. W.W.: The second author assisted in collecting the data and revising the case report. H.W.: Consultant surgeon who supervised the entire case, with the patient being admitted under her care.

Conflicts of Interest: The authors declare that they have no financial conflicts of interest.

Availability of data and materials: All the information involved in this article can be found on the internal website of Shandong Second Medical University Affiliated Hospital. If necessary, please contact the corresponding author to obtain the required information.

REFERENCES

1. Nedham FN, Nagaraj V, Darwish A, Al-Abbasi TA (2022) Retroperitoneal blue cell round tumor (Ewing sarcoma in a 35 years old male)- case report. *Int J Surg Case Reports*, **94**: 107045. <https://doi.org/10.1016/j.ijscr.2022.107045>
2. Javalgi AP, Karigoudar MH, Palur K (2016) Blue cell tumor at unusual site: retroperitoneal Ewing's sarcoma. *J Clin Diag Res, JCDR*, **10**(4): ED19-ED20. <https://doi.org/10.7860/JCDR/2016/18302.7618>
3. AlRashed R, AlHarbi H, Abdulfattah F, Alhasan I, Alsannaa F (2022) A case report of retroperitoneal Ewing sarcoma requiring adrenalectomy. *Int J Surg Case Reports*, **95**, 106966. <https://doi.org/10.1016/j.ijscr.2022.106966>
4. Chen S, Li Y, Zhao H, Yang X (2022) The giant retroperitoneal

- extraosseous Ewing's sarcoma: A case report. *Asian Journal of Surgery*, **45**(2): 804–806. <https://doi.org/10.1016/j.asjsur.2021.12.009>
5. Reis F, Macedo E, França Junior MC, Amstalden EI, Appenzeller S (2017) Retroperitoneal Ewing's sarcoma/embryonal tumor: a rare differential diagnosis of back pain. *Radiologia Brasileira*, **50**(6): 409–410. <https://doi.org/10.1590/0100-3984.2015.0236>
 6. Kong L, Zhang X, Zhang Y, Kong Z (2024) Primary retroperitoneal Ewing's sarcoma in a young woman. *Asian J Surg*, **47**(2): 1281–1282. doi:10.1016/j.asjsur.2023.11.067
 7. Wu SY, Hsu CK, Yue CT, Tsai YC (2023) Large retroperitoneal extra-skeletal Ewing's sarcoma with renal pedicle invasion: a case report. *BMC Urology*, **23**(1): 95. <https://doi.org/10.1186/s12894-023-01272-z>
 8. Riggi N, Suvà ML, Stamenkovic I (2021) Ewing's sarcoma. *The New England Journal of Medicine*, **384**(2): 154–164. <https://doi.org/10.1056/NEJMra2028910>
 9. National Comprehensive Cancer Network. Bone Cancer (Version 2.2023). https://www.nccn.org/professionals/physician_gls/pdf/bone.pdf.
 10. Van Mater D and Wagner L (2019) Management of recurrent Ewing sarcoma: challenges and approaches. *OncoTargets and therapy*, **12**: 2279–2288. <https://doi.org/10.2147/OTT.S170585>
 11. Wang Y, Wang C, Xia M, Tian Z, Zhou J, Berger JM, Zhang XH, Xiao H (2024) Engineering small-molecule and protein drugs for targeting bone tumors. *Molecular Therapy*, **32**(5): 1219–1237. <https://doi.org/10.1016/j.ymthe.2024.03.001>

